

A study of prevalence and characteristics of glaucoma in pseudo exfoliation syndrome

Gnanaselvan Joseph^{1,*}, Anbuselvi Thirunavukkarasu²

¹Professor, ²Assistant Professor, Dept. of Ophthalmology, Govt. Raja Mirasudar Hospital Thanjavur Medical College

***Corresponding Author:**

Email: helengs18@hotmail.com

Abstract

Background: Glaucoma is the leading cause of irreversible blindness. Pseudo exfoliation is a recognised risk factor for developing glaucoma. Pseudo exfoliation glaucoma is the most common form of secondary open angle glaucoma.

Aim and Objective: To study the prevalence and characteristics of Glaucoma in Pseudo exfoliation syndrome.

Methods: This hospital – based, descriptive cross-sectional study included all patients diagnosed as Pseudo exfoliation syndrome with age group of 40-80 years at the Tertiary Eye Care Centre. A study proforma was used to obtain socio-demographic information, medical history, ocular history and relevant findings on ocular and systemic examination. Descriptive and comparative statistical analyses were performed.

Results: Ninety-six patients with pseudo exfoliation of age 61.15±7.41 SD were examined. The prevalence of glaucoma among the Pseudo exfoliation patients was 35%. In Pseudo exfoliation syndrome, Open angle glaucoma (88%) is more common than Angle closure glaucoma (12%) and Unilateral glaucoma [65%] is more common than Bilateral glaucoma (35%). Glaucoma in Pseudo exfoliation syndrome showed signs of moderate to severe glaucomatous damage including moderate (71%) to severe (22%) optic disc cupping and moderate (33%) to severe (9%) visual field defects. Single drug (Timolol 0.5%) was effective in 21% of glaucoma patients and combination drugs (Timolol 0.5% and Brimonidine 0.2%) needed to treat 44% of glaucoma patients. Rest 35% of patients had poor response to medical management and were effectively managed by Trabeculectomy.

Conclusion: Glaucoma in Pseudo exfoliation syndrome is relatively common and has a more severe clinical course. Hence careful ocular examination of Pseudo exfoliation patients is mandatory to identify and treat glaucoma at the earliest.

Keywords: Disc changes, Prevalence, Pseudo exfoliation Glaucoma, Pseudo exfoliation syndrome, Visual fields.

Introduction

Pseudo exfoliation syndrome is a systemic disorder with primary ocular manifestations. It is a greyish white extracellular material which is composed of a protein core surrounded by glycosaminoglycans and is produced by abnormal basement membrane of aging epithelial cells in trabeculum, equatorial lens capsule, iris and ciliary body. This material is deposited over anterior lens capsule, zonules, ciliary body, iris, trabeculum, anterior vitreous face and conjunctiva. Schlotzer and Streeten found pseudoexfoliative material like fibrils in skin, myocardium, liver, lung, kidney and meninges.⁽¹⁾ The clinical diagnosis of pseudo exfoliation is based on the finding of dandruff like material in pupillary margin or sugar frosting of the anterior lens capsule. One third to half of patients with pseudo exfoliation are unilateral at the time of presentation. The patients presenting with pseudo exfoliation in one eye will show exfoliative material in other eye in conjunctival biopsy.⁽²⁾ The deposition of exfoliative material on the pupillary margin leads to loss of pupillary ruff.⁽³⁾

Pseudo exfoliation is a common cause of secondary open angle glaucoma. In contrast to primary open angle glaucoma in which pressure raises slowly and insidiously, in pseudo exfoliation syndrome pressure rises drastically. This fibrillary material is insoluble in aqueous, gets filtered and deposited in trabecular meshwork. It leads to clogging of trabecular meshwork and impairment of blood aqueous barrier in turn leads to decrease in aqueous out flow and increase in Intra Ocular

Pressure. It is also accompanied by pigment release from iris caused by rubbing of iris against deposits in lens capsule; these released pigments also contribute to the blockage of trabecular meshwork.⁽⁴⁾ Pseudo exfoliation syndrome commonly leads to open angle glaucoma. Angle closure glaucoma in pseudo exfoliation syndrome is rare. The mechanism of angle closure is pupillary block⁽⁵⁾ produced by posterior synechiae, increased rigidity of iris and anterior movement of lens due to zonular weakness.⁽⁶⁾

Glaucoma produces characteristic appearance in optic nerve head. The changes include increase in cup disc ratio, loss of neuroretinal rim, bayonetting of vessels, superior and /or inferior polar notching, laminar dot sign, disc haemorrhage and cupping of the disc.⁽⁷⁾ Retinal nerve fibre layer (RNFL) defect precedes the detectable optic disc changes and the field changes. The pseudo exfoliation leads to high mean IOP and more liable for glaucomatous damage to the optic nerve head. Visual field defects in glaucoma are Para central scotoma, arcuate scotoma, ring scotoma, and the end stage of Small Island of central vision. The incidence is greater in pseudo exfoliation because eyes with pseudo exfoliation have poor tolerance to IOP rise.

Aim

Compared to Primary open angle glaucoma, Pseudoexfoliative glaucoma has predominant unilateral presentation with rapid increase in intraocular pressure and rapid visual field loss. Pseudo exfoliation glaucoma

is refractory to single drug anti-glaucoma medication and needs combination drugs or surgical management. The aim of this study is to assess the prevalence and characteristics of glaucoma in Pseudo exfoliation syndrome.

Objectives

To study the following parameters in patients with Pseudo exfoliation

1. Prevalence of glaucoma
2. Assess the type of glaucoma, severity of glaucoma as optic nerve damage and visual field loss and management of glaucoma in Pseudo exfoliation syndrome.

Inclusion criteria: All patients diagnosed as pseudo exfoliation syndrome with age group of 40-80 years.

Exclusion criteria: Patients with less than 40 years or with previous history of uveitis or ocular trauma and known cases of POAG and angle closure glaucoma who were on medication.

Materials and Methods

A total of 96 patients with pseudo exfoliation who attended the outpatient department of ophthalmology, Thanjavur medical college, Thanjavur from July 2014 to September 2015 were investigated and followed up for one year. This was hospital based descriptive cross-sectional study.

All patients were subjected to complete ocular examination including visual acuity, slit lamp examination, detailed ophthalmoscopic examination with direct ophthalmoscope, slit lamp bio microscopy with +90 dioptre lens and indirect ophthalmoscope, Intraocular pressure measurement, gonioscopy, pachymetry and Visual field examination with automated perimeter (octopus 301). Ultrasound B scan and ultrasound bio microscopy were done in selected patients who had opaque ocular media.

Pseudo exfoliation glaucoma was diagnosed on the basis of pseudoexfoliative material on slit lamp examination, IOP >21 mm Hg, glaucomatous cupping on fundus examination, pigmentation of trabecular meshwork on gonioscopy, glaucomatous field defects on perimetry.

Results

This study includes 96 patients with pseudo exfoliation in the age group of 40 – 80 years (Table 1). Out of 96 patients 54 patients were males and 42 patients were females (Table 2).

Table 1: Age distribution

Age in years	No of cases	Percentage
41 – 50	6	6
51 – 60	34	36
61 – 70	47	49
71 – 80	9	9

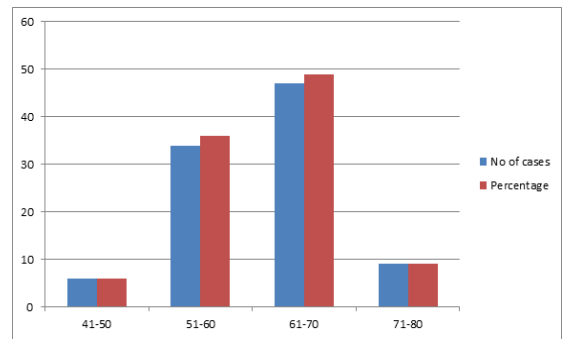
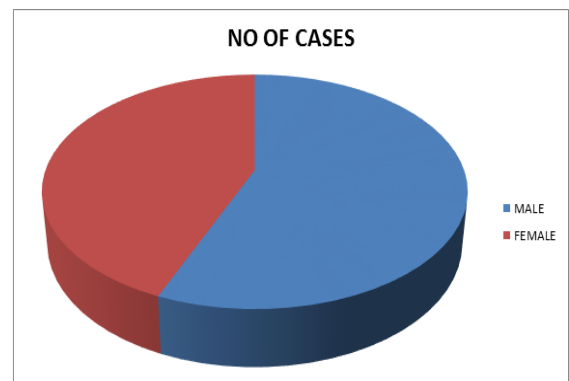


Table 2: Sex distribution

Sex	No of cases	Percentage
Male	54	56
Female	42	44

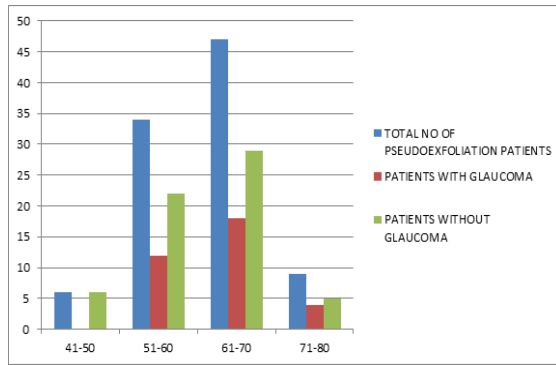


Out of 96 patients enrolled with pseudo exfoliation, 34 patients were diagnosed with Glaucoma. Thus the prevalence of glaucoma in pseudo exfoliation was 35%.

The age adjusted prevalence of glaucoma in Pseudo exfoliation was highest 44% in 70-80 years of age (4 glaucoma patients out of 9 patients with pseudo exfoliation) followed by 38% in 61-70 years of age (18 glaucoma patients out of 47 patients with pseudo exfoliation) and 35% in 51-60 years of age (12 glaucoma patients out of 34 patients with pseudo exfoliation (Table 3).

Table 3: Age adjusted prevalence of glaucoma in pseudo exfoliation

Age in years	Total No of Pseudo exfoliation patients.	Patients with Glaucoma		Patients without Glaucoma	
		No	%	No	%
41-50	6	0		6	100
51-60	34	12	35	22	65
61-70	47	18	38	29	62
71-80	9	4	44	5	56

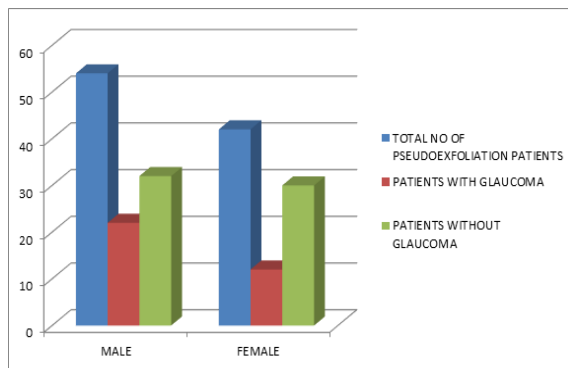


Mean age of patients with pseudo exfoliation was 61.15 years and glaucoma patients with pseudo exfoliation was 62.65 years.

Out of 96 patients with pseudo exfoliation, 54(56%) were males and 42(44%) were females. Prevalence of glaucoma in pseudo exfoliation was 41% in males (22 patients) and 29% in females (12 patients) (Table 4).

Table 4: Prevalence of glaucoma in males and females

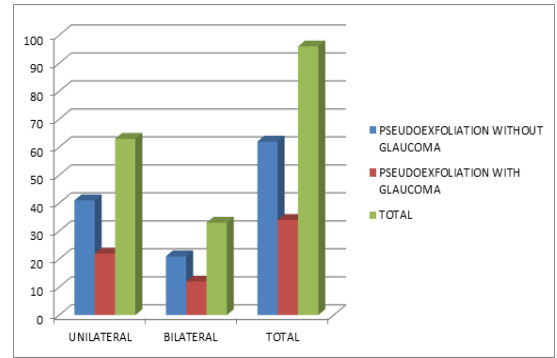
Sex	Total No of pseudo exfoliation patients	Patients with Glaucoma		Patients without Glaucoma	
		No	%	No	%
Male	54	22	41	32	59
Female	42	12	29	30	71



Out of 34 pseudo exfoliation patients with glaucoma, 22 patients had unilateral glaucoma and 12 patients had bilateral glaucoma. Prevalence of unilateral glaucoma (65%) is more than bilateral glaucoma (35%) in patients with pseudo exfoliation. (Table 5)

Table 5: Laterality of glaucoma in pseudoexfoliation

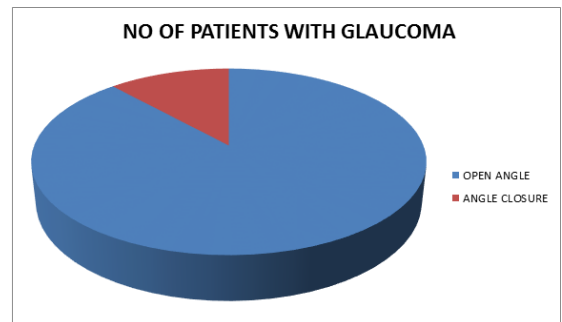
	Pseudo exfoliation without glaucoma	Pseudo exfoliation with glaucoma	Total
Unilateral	41	22	63
Bilateral	21	12	33
Total	62	34	96



Out of 34 pseudo exfoliation patients with glaucoma, 30 patients had open angles and 4 patients had narrow angles. Prevalence of Open angle glaucoma (88%) [95% Confidence Interval 77.1-98.9] is more than narrow angle glaucoma (12%) (Table 6).

Table 6: Types of glaucoma

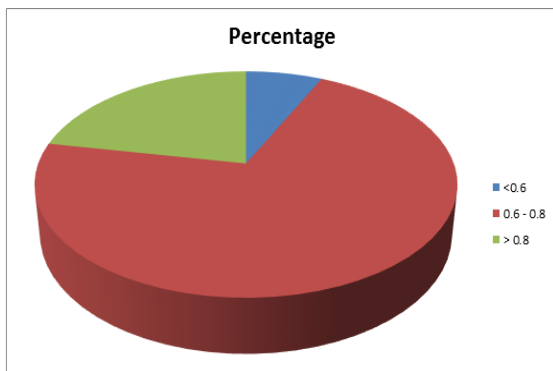
Types of Glaucoma	Pseudo exfoliation patients with glaucoma	
	No of patients	Percentage
Open Angle	30	88
Angle closure	4	12



Analysing the cup-disc ratio (CDR) of 46 eyes of the pseudo exfoliation patients with glaucoma, 3 eyes (7%) had mild glaucomatous defect (CDR<0.6), 33 eyes (71%) had moderate glaucomatous defect (CDR 0.6-0.8) and 10 eyes (22%) had severe glaucomatous defect (CDR >0.8). (Table 7)

Table 7: Optic nerve damage – CD Ratio

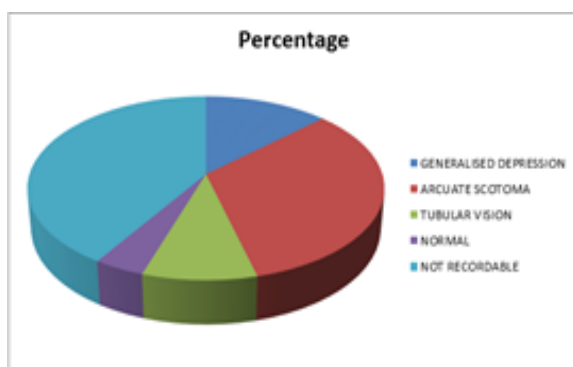
CD Ratio	No of eyes	Percentage (%)
<0.6	3	7
0.6 – 0.8	33	71
>0.8	10	22
Total	46	100



Analysing the visual field defects in 46 eyes of the pseudo exfoliation patients with glaucoma, 6 eyes (13%) had mild glaucomatous defect (generalised depression), 15 eyes (33%) had moderate glaucomatous defect (Arcuatescotoma), 4 eyes (9%) had severe glaucomatous defect (Tubular vision), and 2 eyes (4%) had normal visual fields. Visual field charting was not possible in 19 eyes (41%). (Table 8)

Table 8: Visual field defect

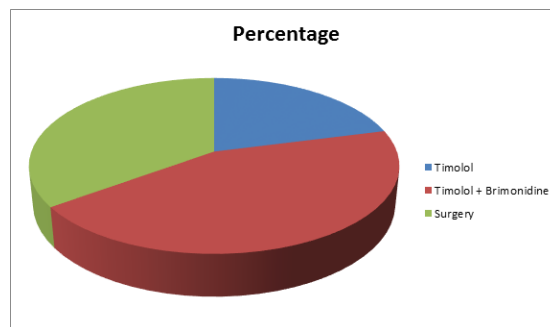
Visual Field Defect	No of eyes	Percentage (%)
Generalised Depression	6	13
Arcuate Scotoma	15	33
Tubular Vision	4	9
Normal	2	4
Not Recordable	19	41
Total	46	100



Out of 34 pseudo exfoliation patients with glaucoma, 7 patients (21%) responded to Timolol eye drop, 15 patients (44%) responded to combination of Timolol and Brimonidine eye drop and 12 patients (35%) had poor response to medical treatment and were effectively managed by combined surgery. (Table 9)

Table 9: Management of glaucoma in pseudo exfoliation patients

	No of patients	Percentage (%)
Timolol	7	21
Timolol +Brimonidine	15	44
Surgery	12	35



Discussion

Glaucoma is the silent thief of sight because vision loss occurs gradually over a period of time, symptoms occur only when disease is advanced and early detection is the best protection.

In this study, 96 patients with pseudo exfoliation were subjected for detailed evaluation and analysis regarding the age, gender, laterality, glaucoma association, type of glaucoma and response to treatment. The glaucoma association with pseudo exfoliation was 35%. The prevalence of glaucoma in pseudo exfoliation syndrome was 30% in some studies^(8,9) and 40- 50% in another study.⁽¹⁰⁾ The incidence of glaucoma increases with age, similar to the study conducted in western India⁽¹¹⁾ 88% of patients had open angle glaucoma and 12% of patients had angle closure glaucoma. Open angle glaucoma is common in pseudo exfoliation syndrome.⁽¹²⁾ 65% patients had unilateral glaucoma and 35% patients had bilateral glaucoma. Unilateral cases had higher incidence than bilateral presentation, comparable to Henry et al study.⁽¹³⁾ Hence Pseudo exfoliation is the commonest cause of unilateral secondary open angle glaucoma. The prevalence of glaucoma in pseudo exfoliation was higher in males (41%) than females (29%) as compared to other studies.⁽¹⁴⁾

Analysing the cup-disc ratio, 71% of patients had moderate glaucomatous damage as CD Ratio 0.6 to 0.8 and 22% of patients had severe glaucomatous damage as CD Ratio >0.8. Analysing the visual field defects, 33% of patients had moderate defect as arcuate scotoma and 9% of patients had severe glaucomatous defect as tubular vision.

In our one year follow up study 65% of patients responded to medical management and 35% of patients responded to surgical management. Single drug (Timolol 0.5%) was effective in 21% of glaucoma patients and Combination drugs (Timolol 0.5% and Brimonidine 0.2%) needed to treat 44% of glaucoma patients Rest

35% of patients had poor response to medical management and were effectively managed by Trabeculectomy. Post-surgery there were no complications. All patients had diffuse cystic filtering bleb with well controlled intraocular pressure.

Though pseudoexfoliation glaucoma patients most often had open angles, in our study 12% of glaucoma patients had narrow angles. Hence detailed gonioscopy is mandatory not to miss narrow angle.

Pseudoexfoliation glaucoma patients respond to medical management better with combination drugs than single drug.

Conclusion

The prevalence of glaucoma was high in pseudo exfoliation. Unilateral glaucoma with open angles was the common presentation. The optic nerve damage is moderate to severe. The glaucoma in pseudo exfoliation showed better response to combination drugs than single drug. The need of surgical therapy to reduce the intraocular pressure is high in glaucoma in pseudo exfoliation syndrome.

All patients with pseudo exfoliation must undergo complete glaucoma evaluation for early detection and follow up. Patients with pseudo exfoliation alone without glaucoma must be followed every 6 months. In pseudo exfoliation patients with glaucoma the intraocular pressure must be checked every 3-6 weeks.

Pseudo exfoliation is an important cause of secondary open angle glaucoma. Due to high prevalence of glaucoma in pseudo exfoliation syndrome, severe damage to optic nerve and increased need of surgical therapy the screening of general population for pseudo exfoliation and evaluation of pseudo exfoliation patients for glaucoma detection and management is mandatory.

References

- Schlotzer-Schrehardt U, N Aaumann GOH. Ocular and systemic exfoliation syndrome. *AMJ Ophthalmol.* 2006; 141(5): 921-937.
- Tarkkanen A, Kivela T, John G. Lindberg: And the discovery of exfoliation syndrome, *Acta Ophthalmol Scand.*, 2002, 80:151-154.
- Latters W J, Samuelson T W. Pseudo exfoliation glaucoma, In: Yanoff M, Duker J S. Editors: *Ophthalmology*, 2nd ed. Vol 2. New Delhi: Mosby; 2006.P.1499-1503.
- Tarkkanen A. Treatment of chronic open angle glaucoma associated with pseudo exfoliation. *Acta Ophthalmol.* 1965; 43:514-523.
- Aasved H. Incidence of defects in pigmentary papillary ruff in eyes with fibrilloglione epitheliocapsularis (so called senile exfoliation or pseudo exfoliation of the anterior lens capsule). *Acta Ophthalmol.*1973: 51:710-715.
- AAO OPH. Vol 108 pg 1043: Ocular hemodynamic in pseudo exfoliation syndrome and pseudo exfoliation glaucoma. June 2001.
- Investigate Ophthal and visual sciences Nov 2005 pg4170 vol 96, no 9: pathophysiologic changes in optic nerves with primary open angle glaucoma and pseudo exfoliation glaucoma.
- Lamba P. A Giridhar A: Pseudo exfoliation syndrome *I.J.O.*32:169, 1984.
- Shazly TA, Farraq AN. Prevalence of pseudoexfoliation syndrome and pseudo exfoliation glaucoma in Upper Egypt. *BMC Ophthalmol* 2011 Jun 27; 11:18doi: 10.1186/1471-2415-11-18.
- Yvonne Ou, MD. Pseudo exfoliation (PXE) Syndrome and Pseudo exfoliation Glaucoma. University of California, San Francisco, UCSF Medical Center. July 21, 2015.
- Rao, Vinita MS. Prevalence and Prognosis of Pseudo exfoliation Glaucoma in Western India. *Asia-Pacific Journal of Ophthalmology*; March/April 2015 – Volume 4 – Issue 2 – p 121-127.
- Prince and Ritch: Preclinical diagnosis of pseudo exfoliation: *Arch oph.*105:1076,1987.
- Mitchell P Wang JJ, Hourihan F. The relationship between glaucoma and pseudo exfoliation: *Blue Mountain Eye Study.* *Arch Ophthalmol* 1999; 117:1319-1324
- Jason Kian Seng Lee. Elizabeth Poh Ying Wong. Pseudo exfoliation syndrome at a Singapore eye clinic. *Clin Ophthalmol.* 2015; 9:1619-1624.