

## Pseudomyxoma pleurii- A case report with clinicopathology and management of a rare Clinical presentation

Devender Singh<sup>1</sup>, Shegu Gilbert<sup>2,\*</sup>, Sudhakar Natrajan<sup>3</sup>, Paulvannan Subramanian<sup>4</sup>, Sadayandi Kandasamy<sup>5</sup>

<sup>1,2</sup>Dept. of CTVS, <sup>3</sup>Dept. of Medical Oncology, <sup>4</sup>Dept. of General Surgery <sup>5</sup>Dept. of Nephrology, Kovai Medical Center & Hospital, Tamil Nadu

**\*Corresponding Author:**

Email: shegugilbert@yahoo.co.in

---

### Abstract

Pseudomyxoma pleurii is an unusual clinical syndrome caused by trans-diaphragmatic spread of pseudomyxoma peritonei due to mucinous adenocarcinoma of the appendix. The disease is highly lethal. We present one such patient who had underwent renal transplant and on immunosuppression therapy developed pseudomyxoma pleurii. Cytoreduction surgery and hyperthermic chemo perfusion were done which is the standard treatment for these patients which has an impact on the overall survival and disease free survival.

**Keywords:** Pseudomyxoma peritonei; Adenocarcinoma, Mucinous; Lung neoplasms; Thoracic surgery; Pleural neoplasms.

---

### Introduction

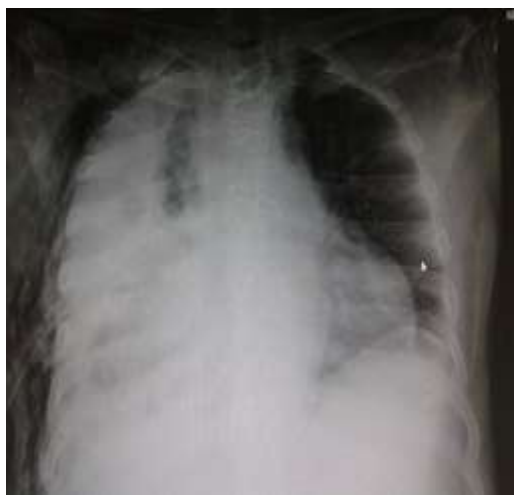Pseudomyxoma pleurii is an uncommon entity characterized by the presence of malignant mucinous implants that arise due to trans-diaphragmatic spread of pseudomyxoma peritonei. The incidence of pseudomyxoma peritonei is 1 per million per year. It originates usually from appendiceal mucinous neoplasms. We report and discuss the clinicopathology and management of one such patient.

### Case Report

A 63 year old male was admitted to our hospital with history abdomen distension and breathlessness since one month. He was a diabetic. Nineteen months back he was diagnosed to have mucinous adenocarcinoma of the appendix and pseudomyxoma peritonei (PMP). He underwent laparotomy, debulking of the tumour, omentectomy, appendectomy and intraperitoneal hyperthermic chemotherapy (IHPC). He received six cycles of chemotherapy with leucovorin, 5-fluorouracil and intraperitoneal cisplatin. He underwent renal transplant for chronic kidney disease three years back and he was on immunosuppressive drugs. He also underwent coronary artery bypass graft surgery 6 years back. Initial ultrasound of the abdomen revealed ascites, sigmoid and descending colon thickening. Chest radiograph revealed complete opacification of the

right hemi-thorax. (Fig. 1) He was evaluated by pulmonologist. Thoracoscopy revealed gelatinous fluid inside the pleural cavity. Computed tomography (CT) of the Thorax was done which revealed gross loculated right pleural collection with multiple air pockets and lobulated contours and volume loss of the lung. CT scan of the abdomen revealed a generalized increase in the pseudomyxoma in the abdomen and pelvis. He underwent cytoreduction surgery (CRS) of the thorax and abdomen. Right posterolateral thoracotomy was done. The entire pleural cavity was filled with mucinous material. (Fig. 2) Complete pleurectomy and debulking of the mass was done. This was combined with laparotomy and debulking of the tumour. The peritoneum was filled with mucinous material. Tumour deposits were noted in the pouch of Douglas, liver, spleen, stomach and transverse colon. Patient had a stormy post-operative period with massive amounts of pleural drain up to five to seven litres every day. It settled after treatment with octreotide. Patient gradually recovered and was discharged after six weeks. Histopathologic examination of the tumour revealed fibrous tissue with a neoplasm consisting of variable size cystic spaces containing pools of mucin separated by fibrous septa. Single layer of tall columnar cells with basal oval vesicular nuclei and apical mucin were seen lining the cystic spaces. Few small epithelial cell clusters were seen within the mucin pools. (Fig. 3) All these characteristics

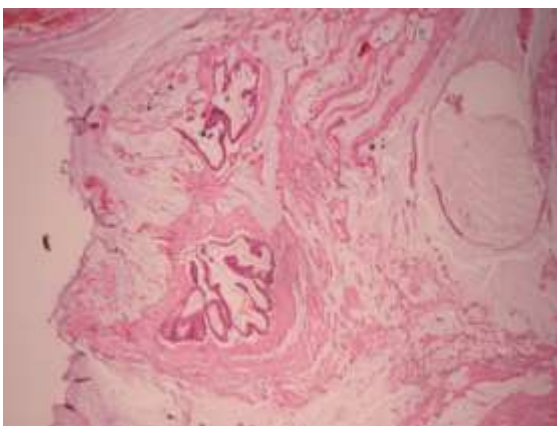
confirmed the diagnosis of pseudomyxoma pleurii<sup>1</sup>. He is doing well in follow up at two years and chest radiograph shows clear right lung fields. (Fig. 4)



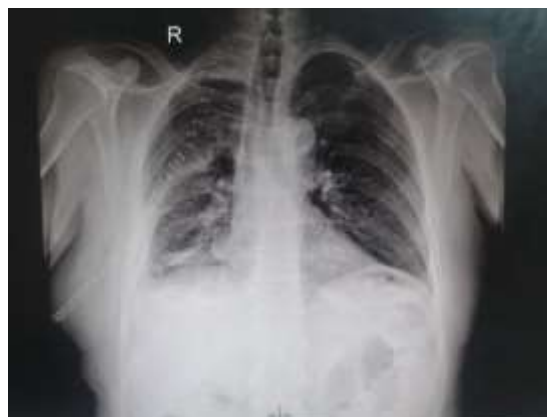**Fig. 1: Chest radiograph shows homogenous opacification of the right hemithorax**



**Fig. 2: Mucinous pleural implants excised during surgery**



**Fig. 3: Histologic section 40x showing dissecting pool of mucin and tumor cells (H&E x 40)**



**Fig. 4: Post-operative chest radiograph reveals clear right lung fields**

### Discussion

Pseudomyxoma pleurii<sup>1</sup> is a condition where the pleural cavity is distended with mucinous material. It is caused by the trans-diaphragmatic spread of PMP. PMP is characterized by peritoneal mucinous implants which are caused by mucin producing neoplasms. It arises as a result of adenocarcinoma of the appendix, colon or ovary. It can also be caused by ruptured mucocele of the appendix. Thoracic involvement is unusual. In a study by Geisinger et al. 30 cases of PMP presented with pleural effusion. Patient age group varied from 34 to 79 years. The interval between the diagnosis of PMP and the related thoracic disease varied from 1 to 15 years<sup>1</sup>. Clinically patients present with abdominal distension, breathlessness and other generalised symptoms like loss of weight and loss of appetite. Most patients with PMP are diagnosed with pseudomyxoma pleurii incidentally during radiological examinations in their follow up. Invasion of the thorax can present as pleural effusion or lung metastasis chest radiographs show opacifications of hemithorax and mass lesions in the lung fields. CT scan of thorax reveal nodules or masses in the lung parenchyma, thickened pleura and ascites. Pleural tapping presents a gelatinous effusion. Pleural fluid cytology shows extra cellular mucinous material with or without neoplastic cells. Pleural biopsy can confirm the presence of neoplasm. Histopathological examination of tumour mass is confirmatory. Histologic features of the metastasis resembles the primary appendiceal neoplasm. Characteristics of the pleural pathology include moderate cellularity, occasional single cells and most tumor cells are seen in small cohesive three dimensional aggregates. Smear background contains extensive mucin, cellular contours varies

from round to low columnar. Nuclei are eccentric and hyperchromatic with small nucleoli. The nuclear cytoplasmic ratios are low due to cytoplasmic mucin often in solitary round vacuoles compressing the nucleus into a crescent shape<sup>2</sup>. Microscopic features of lung metastasis resembles the typical lesions of low grade variety. Hypocellular fibrous connective tissue trabeculae contain dissecting acellular mucin are seen between the tumour and the parenchyma. From histological point of view the differential diagnosis includes primary mucinous cystic neoplasm and colloid carcinomas of lung. Ronnet et al. described two groups of this disease according to the histopathological picture: Disseminated peritoneal adenomucinosis (DPAM) and peritoneal mucinous carcinomatosis (PMCA)<sup>3</sup>. Bradley et al suggested that the survival rates of these groups are similar so they were combined as a single clinicopathologic entity termed low grade mucinous carcinoma peritonei (MCP)<sup>4</sup>. High grade MCP has poor survival and is characterized by signet ring cell differentiation. An intermediate group has also been reported.

The mechanisms involved in the spread of the disease from the peritoneum into the pleural cavity includes iatrogenic damage of the diaphragm during previous peritonectomy, the presence pleuro-peritoneal communications and lymphovascular spread.

Treatment strategies include cytoreduction surgeries like debulking of the thoracic and peritoneal implants, peritonectomy and pleurectomy. Our patient underwent laparotomy and debulking of the abdominal tumour implants, thoracotomy and debulking of the pleural implants, decortication and IPHC. CRS associated with IPHC provided acceptable morbidity and mortality for these patients<sup>5</sup>. Intrathoracic chemotherapy and pleurectomy has been reported in one patient with long term survival of more than 5 years. IPHC is done using mitomycin or cisplatin. Radical debulking and IPHC substantially prolongs tumour remissions with acceptable risks of postoperative complications and mortality. IPHC is an effective treatment because hyperthermia improves the tumour penetration by the chemotherapeutic agents and adequate concentration of the drug is maintained for contact with the tumour locally. Systemic effects are much less due to the peritoneum-blood barrier.

## Conclusions

PMP is a lethal disease. Trans-diaphragmatic spread leads to pseudomyxoma pleurii which has a unfavourable prognosis. Early diagnosis and aggressive management with combined radical debulking and IPHC is the standard treatment. It has an impact on overall survival and disease free survival.

## Acknowledgements

The authors would like to acknowledge Mrs. S. Nithya and Mr. Sujoy. BPT for their contribution towards the study.

**Conflicts of interest:** None declared

## References

1. Kim R, Geisinger, Edward A, Levine, Perry Shen, Robert F, Bradley. Pleuropulmonary Involvement in Pseudomyxoma Peritonei. *American Journal of Clinical Pathology*. 2007;127:135-143.
2. Young RH, Gilks CB, Scully RE. Mucinous tumors of the appendix associated with mucinous tumors of the ovary and pseudomyxoma peritonei: a clinicopathologic analysis of 22cases supporting an origin in the appendix. *Am J Surg Pathol*. 1991;15:415-429.
3. Ronnett BM, Zahn CM, Kurman RJ, Kass ME, Sugarbaker PH, Shmookler BM. Disseminated peritoneal adenomucinosis and peritoneal mucinous carcinomatosis: a clinicopathologic analysis of 109 cases with emphasis on distinguishing pathologic features, site of origin, prognosis, and relationship to "pseudomyxoma peritonei." *Am J Surg Pathol*. 1995;19:1390-1408.
4. Bradley RF, Stewart JH, Russell GB, Levine EA, Geisinger KR. Pseudomyxoma peritonei of appendiceal origin: a clinicopathologic analysis of 101 patients uniformly treated at a single institution, with literature review. *Am J Surg Pathol*. 2006;30:551-559.
5. Dirk F. P. M. Peek, Geerard L. Beets. Pseudomyxoma peritonei in the pleural cavity. *Diseases of the Colon & Rectum*. 1999;42:113-115.