

Bronchiectasis: A neglected entity in the modern world- An evaluation of 102 cases

Varna Indushekar¹, Chetan Basavaraj Patil^{2,*}

^{1,2}Assistant Professor, ¹Dept. of Pathology, ²Dept. of Respiratory Medicine, Karwar Institute of Medical Sciences, Karwar, Karnataka, India

***Corresponding Author: Chetan Basavaraj Patil**

Email: chetan.colors@gmail.com

Abstract

Background: Bronchiectasis is one of the commonest diseases routinely encountered in day to day practice which leads to significant morbidity, mortality and lowered quality of life in the affected individuals. The clinical course of this disease is usually progressive and causes lung damage over many years. In this research study, we analysed its presentation, etiology, diagnosis and indications for surgery.

Methodology: It's a prospective and non randomised study, conducted in 102 patients during the time period November 2016 to December 2018 at a tertiary care referral hospital. All the patients in study group were enrolled and analysed for age, sex, probable etiological factors, presenting symptomatology & radiological findings.

Results: The mean age of presentation to the hospital was 33±20.8 years with male to female ratio of 4:5. The most common presenting complaints were cough (100%) followed by expectoration (91.1%) and breathlessness (53.9%). Commonest causes for bronchiectasis in the study included tuberculosis in 56.8% of cases followed by Post infections in 17.6% patients.

Conclusions: Bronchiectasis is a process that occurs in the context to chronic airway infection and inflammation, since there is no accurate estimation of the etiology of the disease in developing countries; this study aimed to determine them especially in coastal part of India. Surgical treatment should be offered in patients with failed medical management.

Keywords: Bronchiectasis; Tuberculosis; Pneumonia.

Introduction

Bronchiectasis is a chronic and jeopardizing lung diseases that have the capacity of causing substantial morbidity and mortality in the affected individuals. It is defined as heterogeneous and progressive respiratory disease with permanent dilatations of bronchi with destruction of the bronchial wall. Bronchiectasis was first described by Laenec in 1819. Before the antibiotic era it was considered a morbid disease with a high mortality rate from respiratory failure and corpulmonale [1].

It is a common chronic respiratory disease in this coastal part of India which presents with cough, expectoration, wheezing and breathing difficulties. Such patients will be having repeated respiratory infections, and impaired quality of life [2,3]. Exacerbations of bronchiectasis account for a large proportion of the clinical workload and the economic impact of bronchiectasis on health care systems globally [4,5].

Exact incidence and prevalence of bronchiectasis is not well known, in fact historically it was one the neglected disease, a resurgence in interest in the disease over the past several years has generated a volume of new evidence that improves our understanding of the disease [6]. In developing countries, few studies have been published on the etiology of the disease. Since the detection of the etiology of bronchiectasis plays an important role in its proper management [7], the present study aimed to provide an accurate estimation on the prevalence and major causes of the disease, by investigating the possible causes of bronchiectasis in patients referred to tertiary care hospital, Karwar, located in coastal part of Karnataka, India.

Materials and Methods

This is a prospective and non-randomized study conducted at Department of Respiratory medicine, a tertiary care hospital attached to Karwar institute of medical sciences, Karwar, India between November 2016 and December 2018. Diagnoses was done mainly based on the clinical and radiological data. An ethical committee approval and consent of study subjects was obtained.

After thorough physical examination, bronchiectasis was diagnosed on the history of chronic cough; confirmed by high resolution computed tomography (HRCT) thorax (Fig. 1). All the routine hematological investigations were done which included complete hemogram, random blood sugar and kidney function tests; skiagram chest was taken (Fig. 2), sputum was sent for acid fast bacilli staining, gram's stain, culture & amp; sensitivity and 10% KOH for fungus.

All the patients were enrolled in the study only after the confirmation from HRCT thorax and spirometry suggestive of obstructive pattern i.e. FEV1/ FVC less than 70% and FEV1% less than 80% predicted. Electrocardiography and two dimensional echocardiography was performed in patients with signs and symptoms of corpulmonale. Patients with cystic fibrosis and retroviral disease were excluded from the study due to resource limitation & lack of funding for immunological testings.

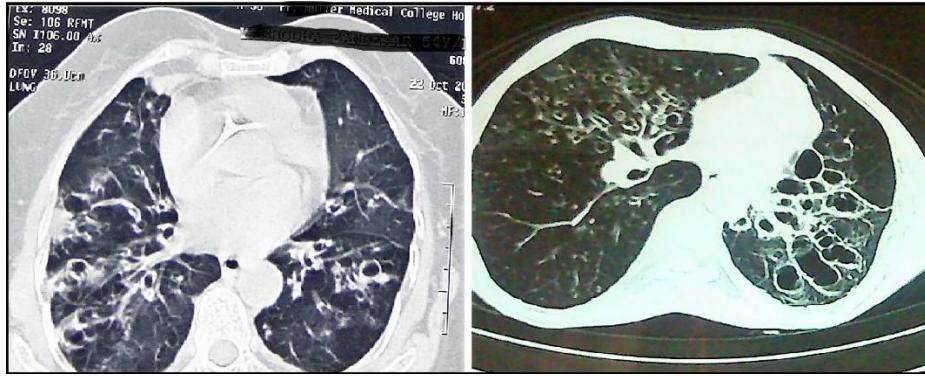


Fig. 1: a) Cystic type of bronchiectasis b) Cylindrical type of bronchiectasis

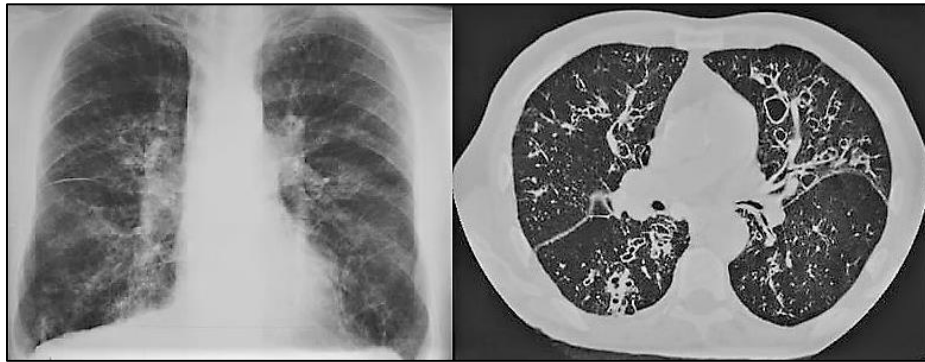

Fig. 2: Patient bilateral bronchiectasis. Comparing with chest skiagram and CT chest

Results

A total of 102 patients with bronchiectasis were enrolled in the study period. The mean age at the time of diagnosis of these patients was 33 ± 20.8 years. The mean delay in diagnosis was 7 years (3 months to 35 years). Male to female ratio was 4:5. Demographic profiles of the study population are summarized in Table 1.

All patients presented to the hospital were symptomatic. The most common presenting symptom was recurrent cough which was present in all the patients (100%), often associated with expectoration seen in 93 (91.1%) patients. Copious amount of fetid sputum was found in 19 (18.6%) patients and recurrent haemoptysis was found in 28 (27.5%) patients. Another most important presenting symptom was Breathlessness seen in 55 (54.0%) patients. The duration of symptoms ranged from 1 to 10 years (mean of 4.7 ± 2.3 years). The clinical manifestations at the time of presentation to the hospital are listed in Table 2.

The most common known causes of bronchiectasis in the study population were post-tubercular sequelae in 58 patients (56.8%), post infectious following severe pneumonia in 18 patients (17.6%), Allergic bronchopulmonary aspergillosis (ABPA) in 5 patients (4.9%), Cicatrisation in 2 patients (1.9%), Foreign body in 2 patients (1.9%). The diagnosis remained unknown (Idiopathic) in the 17 cases (16.6%).

We classified bronchiectasis as idiopathic only after immunological, sweat chloride, total IgE, ANA, rheumatoid factor, RAST-aspergillus, mucociliary clearance, alpha 1-antitrypsin tests were negative, and in absence of previous

history of pneumonias or tuberculosis. HRCT was used as a tool to identify situs inversus, tracheobronchial abnormalities and emphysema. Fiberoptic bronchoscopy was performed in localized bronchiectasis with no clear history. Bronchiectasis was considered post infective when there was clear history or documents in favour of previous severe respiratory infections along with signs and symptoms of bronchiectasis after the episode and/or consistent radiological findings and negative results on the tests mentioned above.

During the course of hospitalization, all the patients initially received a course of antibiotics, primarily amoxicillin with clavulanic acid /Macrolides/ first and second-generation cephalosporins and were submitted to chest physiotherapy with postural drainage. Of these 102 patients, 2 presented with severe haemoptysis and were referred to bronchial artery embolization. Among the clinically treated patients who were hospitalized, 3 died due to chronic cor pulmonale/ sepsis. Out of the rest 99 patients, 12 patients were submitted to cardiothoracic surgery for lobectomy/pneumonectomy for frequent re-admission due to recurrent chest infection and hemoptysis. Out of these 12 patients, 9 patients received unilateral resections and 3 patients underwent bilateral resections.

Table 1: Demographic data, site and smoking history in bronchiectatic patients

S. No.	Characteristics of study population	
1	Total No. of patients	102
2	Mean age - Age range (years)	33±20.8 14-80
3	Sex - Male - Female	44(43.1%) 58(56.9%)
5	Side of involvement - Right Lung - Left Lung - Bilateral	50 (49.0%) 44(43.1%) 8 (7.8%)
6	History of smoking	40 (39.2%)

Table 2: Clinical manifestations in patients with bronchiectasis

Clinical findings in study population	
Cough	102 (100%)
Expectoration	93 (91.1%)
Breathlessness	55 (53.9%)
Wheezing	42 (41.1%)
Chest pain	36 (35.2%)
Hemoptysis	28 (27.5%)
Digital clubbing	26 (25.4%)
Chest wall flattening/ retraction	19 (18.6%)
Crepitation (Fine/ Coarse)	76 (74.5%)
Cyanosis	2 (1.9%)
Pedal edema	4 (3.8%)

Discussion

Bronchiectasis is a condition in which there are abnormal and permanent dilatations of proximal bronchi resulting in dilated thick walled airways typically extending towards lung periphery [10]. Before the era of antibiotics the disease was considered lethal one with a high mortality rate from either respiratory failure or cor-pulmonale or both [11]. It is usually caused by previous pulmonary infections or bronchial obstruction. The exact incidence of bronchiectasis is unknown especially in developing part of the world because of the widespread unavailability of the radiological investigations like computed tomography even in some tertiary care centres. The prevalence of bronchiectasis has reduced significantly over recent decades due to the abundant availability of antibiotics [12]. Childhood immunization against viral and bacterial agents is also one of the important contributing factors in reduction of bronchiectasis incidence. Early recognition and removal of foreign bodies with bronchoscopy also decreased the incidence of post-obstructive bronchiectasis [11]. However, the incidence of bronchiectasis is still high in developing countries due to the high prevalence of severe childhood respiratory infections and tuberculosis (8). Not just medical line of management, even with the newer advances in thoracic surgery, the optimal treatment for bronchiectasis remains controversial [13].

In the present study conducted at our respiratory centre it was found that in 74.5% of the bronchiectatic patients, there

was a history of childhood pneumonia or tuberculosis. Martínez-García et al., in their guidelines published in the year 2018 mentioned different causes of bronchiectasis including post infection, bronchial obstruction, immune deficiency, impaired mucociliary clearance, hypersensitivity, post-transplant, structural airways abnormalities and association with other disease [14]. They also reported that the cause remains unknown in a fairly high percentage of patients ranging from 24.2%–44.8% [14].

In our study, Pulmonary tuberculosis was the most common cause of bronchiectasis in adults (56.8%) followed by past history of recurrent severe respiratory infections like pneumonias (17.6%). Other causes of bronchiectasis in our studies were Allergic bronchopulmonary aspergillosis (ABPA) in 4.9%, Cicatrised and Foreign body in 1.9% each of the study group. The diagnosis remained unknown (Idiopathic) in the 17 cases (16.6%). This is in par with data & literature available [10]; and it confirms the local epidemiological data regarding acute respiratory infections. Tuberculosis plays an important role in bronchopulmonary sequelae [9].

However in the studies conducted at western countries like USA and Spain (14,16) it was found that post infectious/ previous history of pneumonias were the commonest cause of bronchiectasis, whereas in our study it's the tuberculosis. This is because of the high prevalence of Tuberculosis in the developing countries like India which accounts for almost 25% of total TB cases in the world as per World health organisation (WHO). In paediatric age group, recurrent respiratory infections or pneumonias were the leading cause of bronchiectasis. Evidence has shown that even one episode of severe lower respiratory tract infection can lead to the development of bronchiectasis in a way that the risk of the development of bronchiectasis with recurrent and more severe lung infections increases [15]. Hence giving vaccination to children against viral and bacterial diseases not only prevents the bronchiectasis but other associated complications as well.

Most common symptoms in bronchiectasis patients were cough and expectoration. Other symptoms include breathlessness, wheezing and haemoptysis. Expectoration is sometimes fetid due to anaerobic organisms. Similar to our study where in the commonest presenting complaint is Cough seen in 100% of the cases, followed by expectoration in 91.1% and exertional dyspnoea in 53.9% cases. These clinical manifestations are in comparison with other studies mentioned [10,14].

In our study, diagnosis of bronchiectasis is mainly based on clinical history and radiological findings. HRCT of chest was done mandatorily before including them in the study. The Computed tomography (CT) has replaced bronchography in the investigation of bronchiectasis. CT criteria for diagnosing bronchiectasis has been followed as per direct and indirect signs mentioned as per Naidich et al published in the year 1992 [16]. An important criterion used in deciding the grade and meaning of bronchial dilation is size in comparison with the diameter of the adjacent

pulmonary artery branch. This is possible with the cross-sectional views obtained from CT, especially high resolution CT [17].

Bronchoscopy was not done routinely as the diagnostic method for bronchiectasis, but it was helpful in identifying and removing foreign bodies; for locating the site of bleeding in patients with hemoptysis and also to take bronchoalveolar lavage for ruling out active tuberculosis and in choosing the right antibiotics based on culture & sensitivity. One third of their bronchiectasis cases were unilateral and affected a single lobe, one third were unilateral but affected more than one lobe, and one third is bilateral [12]. In our series, the disease affected the right lung in 50 (49.0%) of patients, it was mainly confined to the middle & lower lobes. In 44 (43.1%) it had involved left lung and in 8 (7.8%) cases both the lungs were involved. The initial treatment strategy for all patients with this disease was conservative, which included infection control, bronchodilation and chest physiotherapy which includes postural drainage as well. Whenever medical treatment was unsuccessful or frequent episodes of hemoptysis existed, surgical modality was the treatment of choice. The main indications for surgery in our study were failure of medical therapy, recurrent or massive hemoptysis, destroyed lung and sequestration. In our study, 12 patients were submitted to surgery for lobectomy/pneumonectomy. Out of these 12 patients, 9 patients received unilateral resections and 3 patients underwent bilateral resections. Another important thing we observed in our study was the patients who were diagnosed for bronchiectasis had less life expectancy as compared with the general population, especially in the patients who were 60 years or more.

Conclusions

Bronchiectasis is one of the commonest respiratory diseases especially in the developing countries, which spares no gender and paediatric population. It is one of the neglected diseases in this part of the world. It is very important to diagnose the disease at the earliest in preventing its exacerbations which can be life threatening. Preventive measures should be taken to avoid acute respiratory infections especially in childhood by giving proper vaccinations and better quality of life by practicing good dental hygiene, avoiding crowded areas in flu season, avoiding contact with infected people etc. Surgical management should be considered in cases of failed medical management which reduces both morbidity and mortality.

Conflicts of Interest: None declared.

Acknowledgements: Nil.

References

1. Balkanlı K, Genç O, Dakak M, Gürkök S, Gözübüyük A, Caylak H, Yücel O. Surgical management of bronchiectasis: analysis and short-term results in 238 patients. *Eur J Cardiothorac Surg* 2003;24:699-702.
2. Chalmers JD, Aliberti S, Blasi F. State of the art: Management of bronchiectasis in adults. *Eur Respir J* 2015;45:1446-1462.
3. Pasteur MC, Bilton D, Hill AT; British Thoracic Society Bronchiectasis Non-CF Guideline Group. British Thoracic Society guideline for non-CF bronchiectasis. *Thorax* 2010;65(Suppl 1):1-58.
4. Chalmers JD, Aliberti S, Polverino E, Vendrell M, Crichton M, Loebinger M, et al. The EMBARC European Bronchiectasis Registry: Protocol for an international observational study. *ERJ Open Res* 2015;1:00081-2015.
5. Joish VN, Spilsbury-Cantalupo M, Opershall E, Luong B, Boklage S. Economic burden of non-cystic fibrosis bronchiectasis in the first year after diagnosis from a US health plan perspective. *Appl Health Econ Health Policy* 2013;11:299-304.
6. Aksamit TR, Carretta E, Daley CL, O'Donnell AE, Thomashow B, Dominik R, Olivier KN, Knowles MR, Griffith DE, Barker AF, Schraufnagel DE, Eden E, Metersky ML, Tino G, Salathe M. The Bronchiectasis Research Registry: A collaborative research cohort for non-cystic fibrosis bronchiectasis. *Am J Respir Crit Care Med* 2012;185:A3654.
7. Li A, Sonnappa S, Lex C, Wong E, Zacharasiewicz A, Bush A, Jaffe A. Non-CF bronchiectasis: does knowing the aetiology lead to changes in management? *Eur Respir J* 2005; 26:8-14.
8. Adebajo AS, Grillo IA, Osinowo O, Adebajo OA. Suppurative disease of the lung and pleura: A continuing challenge in developing countries. *Ann Thorac Surg* 1982;33:4047.
9. Kwon KY, Myers JL, Swensen SJ, Colby TV. Middle lobe syndrome: a clinicopathological study of 21 patients. *Hum Pathol* 1995;26:302-307.
10. Al-Refaie RE, Amer S, El-Shabrawy M. Surgical treatment of bronchiectasis: a retrospective observational study of 138 patients. *J Thorac Dis* 2013;5(3):228-233.
11. Campbell DN, Lilly JR. The changing spectrum of pulmonary operations in infants and children. *J Thorac Cardiovasc Surg.* 1982;83:680-5.
12. Ishak A, Everard ML. Persistent and Recurrent Bacterial Bronchitis-A Paradigm Shift in Our Understanding of Chronic Respiratory Disease. *Front Pediatr* 2017;5:19.
13. Kutlay H, Cangir AK, Enon S, Sahin E, Akal M, Gungor A. Surgical treatment in bronchiectasis: analysis of 166 patients. *Eur J Cardiothorac Surg* 2002;21:634-637.
14. Martínez-García MÁ, Máiz L, Oliveira C, Girón RM, de la Rosa D, Blanco M, Cantón R, Vendrell M, Polverino E, de Gracia J, Prados C. Normativa sobre la valoración y el diagnóstico de las bronquiectasias en el adulto. *Arch Bronconeumol* 2018;54:79-87.
15. Valery PC, Torzillo PJ, Mulholland K, Boyce NC, Purdie DM, Chang AB. Hospitalbased case-control study of bronchiectasis in indigenous children in Central Australia. *Pediatr Infect Dis J* 2004;23:902-908.
16. Naidich DP, Zerhouni EA, Siegelman SS. CT and MRI of thorax, 2nd ed. New York: Raven, 1992.
17. Porto N, Irion KL, Perin C, Palombini BC. Avaliação torácica por imagem: Princípios e semiologia radiológica. *Pesqui Méd (P. Alegre)* 2001;35:96109.

How to cite this article: Indushekar V, Patil CB. Bronchiectasis: A neglected entity in the modern world- An evaluation of 102 cases. *Indian J Immunol Respir Med* 2019;4(1):11-14.