

## A study on mycological profile of corneal ulcers in a tertiary care hospital

Vasudha C.L<sup>1\*</sup>, B. Anuradha<sup>2</sup>, B. Nithya Krishna<sup>3</sup>

<sup>1</sup>Assistant Professor, <sup>2</sup>Professor and HOD, <sup>3</sup>Final year- Part I MBBS Student, Dept. of Microbiology, Mamata Medical College, Khammam, Telangana, India

\*Corresponding Author: Vasudha C.L

Email: drvasucl@gmail.com

### Abstract

**Introduction:** Keratitis may be due to infectious or non-infectious etiology. Breach in the corneal epithelial barrier due to trauma or surgery predisposes to infectious keratitis which can result in scarring and blindness. The most common bacteria implicated is *S.aureus*. Among the fungi, *Fusarium*, *Aspergillus* and *Candida spp.*, are common agents. The fungi are usually inoculated into the cornea by trauma involving plant or vegetable matter. This study was conducted to know the prevalence of fungal keratitis and the different fungal species implicated in patients attending our tertiary care hospital.

**Materials and Methods:** Corneal scrapings collected under slit-lamp examination with aseptic precautions were subjected to KOH mount, Gram stain, inoculated on Sabouraud dextrose agar and sent to Microbiology lab for further processing using standard techniques.

**Result:** Out of the 18 clinically suspected fungal keratitis cases studied, 7 (38.89%) were farmers and most common risk factor associated was trauma 66.66% (12/18) of which vegetative trauma accounted for 27.78% (5/18) cases. 10 (55.56%) cases were both KOH and culture positive. The prevalence of fungal keratitis in our study was 1.54%. Out of the 10 positive cultures, most common isolate was *Candida albicans* (40%).

**Conclusion:** Fungal keratitis is an important cause of monocular blindness that occurs after trivial trauma to the eyes. Most of the patients do not come to the ophthalmologist immediately after such trauma due to lack of knowledge. Early diagnosis and prompt treatment if initiated in the early phase of the infection can prevent the occurrence of any complications.

**Keywords:** Corneal ulcer, Mycotic Keratitis, *Fusarium spp.*, *Candida spp.*

### Introduction

Keratitis is an inflammation of the layers of the cornea which may be due to infectious (exogenous or endogenous) or non-infectious aetiology. Exogenous infection is more common than endogenous infection. Intact corneal epithelium acts as a barrier against many microorganisms. Breach in the epithelial barrier due to trauma or surgery predisposes to infection.

Infectious keratitis is the leading cause of prolonged ocular morbidity and corneal blindness in developing countries.<sup>1</sup> Corneal blindness is responsible for 1.5-2 million new cases of monocular blindness every year.<sup>2</sup> In India, approximately 6.8 million people are suffering from corneal blindness.

The most common bacterial agent causing infectious keratitis is *S. aureus*, while filamentous molds such as *Fusarium spp.*, *Aspergillus spp.*, and yeasts such as *Candida spp.*, are common fungal agents. They produce lesions similar to bacterial agents thereby delaying diagnosis and appropriate treatment.<sup>3</sup>

The fungi are usually inoculated into the cornea by trauma involving plant or vegetable matter sustained in agricultural farms often leading to infectious corneal ulceration and loss of vision.<sup>4</sup>

Apart from trauma, use of corticosteroid [for medical or surgical ocular conditions (LASIK)] and soft contact lenses increases the likelihood of fungal keratitis by altering the cornea's resistance and potentiating pre-existing fungal infection.

Fungal keratitis remains a diagnostic and therapeutic challenge due to:<sup>5</sup>

1. Delay in clinical diagnosis due to fewer signs & symptoms than that of bacterial keratitis.
2. Difficulty in isolating the causative fungi.
3. Difficulty in appropriate treatment with topical antifungal agents due to poor corneal penetration and limited commercial availability of the drugs.
4. Unfavourable prognosis because of protracted course of illness and requirement of specific therapy.

Hence early diagnosis and prompt treatment of fungal keratitis is important even though they are generally less common than either bacterial or viral keratitis.

The above study was conducted in order to know the prevalence of fungal keratitis, to identify and isolate the various causative fungi and to identify the various predisposing factors in patients attending our tertiary care hospital.

### Materials and Methods

This is a cross-sectional study conducted over a period of three months May – July 2018 on patients diagnosed with corneal ulcer attending the Ophthalmology out patient clinic in our tertiary care hospital. Institutional ethical committee clearance was obtained for the study. Before collecting the samples informed consent was taken from the patients.

**Exclusion Criteria:** Cases presenting as non-infectious keratitis, impending perforation, perforated corneal ulcers, typical bacterial or viral keratitis, paediatric patients (as corneal infection in the paediatric age group differ from the adult disease in risk factors, treatment and complications<sup>6</sup>) and patients who refused to give consent were excluded from this study.

**History:** A detailed history, nature and duration of complaints were obtained from each patient, with special emphasis on occupation, history of trauma, the mode of injury, use of steroid eye drops or contact lens, any associated systemic illness such as diabetes mellitus and ocular abnormalities / disorders were noted.

**Specimen Collection and Processing:** Collection of corneal scrapings was performed with full aseptic precautions, after anesthetizing the cornea with 4% lignocaine, under slit-lamp visualization with a sterile No. 15 Bard-Parker blade by an experienced Ophthalmologist. The material obtained by gently scraping the leading edge and base of the ulcer was immediately smeared on two slides [one for Gram stain and the other for 10% potassium hydroxide (KOH) wet mount.<sup>7,8</sup> and inoculated in C-shaped manner on two plates of Sabouraud dextrose agar (SDA) with chloramphenicol (50 mg/ml) and sent to Microbiology lab for further processing. Out of the two inoculated plates of SDA with chloramphenicol (50 mg/ml) received, one was incubated at 25°C and the other at 37°C and both were examined daily for growth. The isolated fungi were identified by standard mycological techniques.<sup>3,9,10</sup>

All the materials required for culture were obtained from Hi Media Laboratories Pvt Ltd, Mumbai, India.

#### Statistical Analysis

The results were expressed as percentages for the analysis of various data. Microsoft excel was used for the interpretation of these results.

#### Results

During the study period a total of 648 patients attended the Ophthalmology OPD, of which 45 cases presented with infectious keratitis. Out of the 45 patients with infectious

keratitis, 18 clinically suspected cases of fungal keratitis were studied. Out of the 18 cases studied, 11 cases (61.11%) were males and 7 cases (38.89%) were females with a male to female ratio of 1.57:1.

Among the 18 cases, 15 cases showed unilateral (monocular) involvement and 3 cases showed both eyes involvement. The commonest age group to be affected was between 41-50yrs (38.89%) followed by 31-40yrs and 51-60yrs (22.22% each group) and least common age group affected was between 61-70yrs (16.67%).

In our study, out of the 18 cases, 7 (38.89%) were farmers by occupation, 5 (27.78%) were working indoors (office/home maker), 4 (22.22%) were working as daily labourers and 2 (11.11%) were working as drivers. In our study we observed that the most common risk factor associated with corneal ulcer was trauma 66.66% (12/18) of which vegetative trauma accounted for 27.78% (5/18) cases, followed by dust particles 22.22% (4/5) [Table 1].

Out of the 18 clinically suspected cases of fungal keratitis, 10 (55.56%) were both KOH and culture positive, while remaining 8 (44.44%) were both KOH & Culture negative. There were no cases where KOH was positive and culture negative and vice versa.

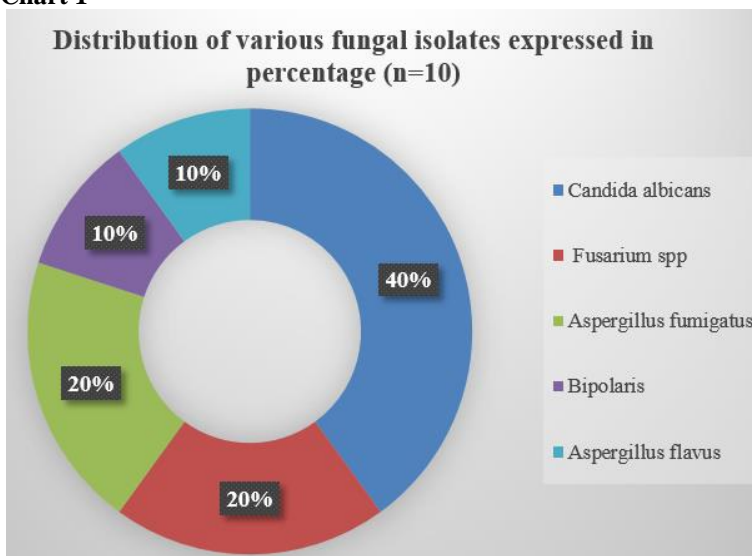
The prevalence of fungal keratitis in our study was 1.54% (10/648).

Out of the 10 positive cultures, 6 (60%) isolates were filamentous fungi and 4 (40%) were yeast-like fungi. Among the 6 filamentous fungi, most common isolates were *Fusarium spp* and *Aspergillus fumigatus* (2 each), while all 4 yeast-like fungi isolated were *Candida albicans*. Overall the most common isolate was *Candida albicans* 40% (4/10), followed by *Fusarium spp* and *Aspergillus fumigatus* 20% (2 each). The other fungi isolated in this study were *Bipolaris* and *Aspergillus flavus* 10% (1 each) [Chart 1].

**Table 1: Risk factors associated with corneal ulcer in our study**

Risk factor		Number of cases	Percentage (n=18)
Trauma	Vegetative trauma	5	27.78%
	Dust particles	4	22.22%
	Others	3	16.67%
Diabetes Mellitus		3	16.67%
Use of steroids		2	11.11%
Dust particles + Diabetes Mellitus		1	05.55%
Contact lens usage		0	0
Ocular abnormalities / disorders		0	0
Previous ocular surgery		0	0
Total		18	100%

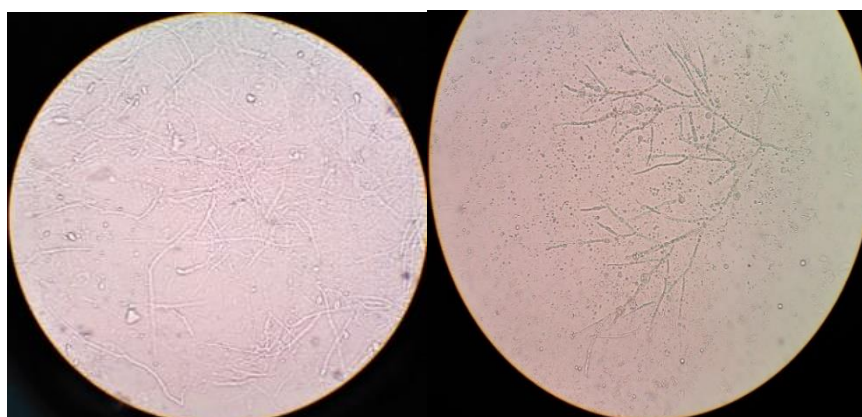
**Chart 1**



**Table 2: Comparison of socio-demographic features between different studies**

	Our study	Bengaluru <sup>11</sup>	Nepal <sup>12</sup>	Madhya Pradesh <sup>13</sup>	
Male	61.11%	61.5%	42%	52%	
Female	38.89%	38.5%	58%	48%	
M:F	1.57:1	1.6:1	1:1.4	1.08:1	
Age group	41-50 yrs (38.89%)	41-60 yrs	51-60 yrs (40%)	40-60 yrs (36.36%)	
Occupation	Farmers (38.89%)	-----	Farmers (57.8%)	-----	
Risk factors	Trauma	66.66%	46%	28.9%	-----
	Vegetative trauma	28.3%	-----	-----	-----
	Dust particles	22.22%	-----	-----	-----
	Diabetes	16.67%	26.5%	-----	-----
	Contact lens	-----	19%	-----	-----

M:F = male to female ratio



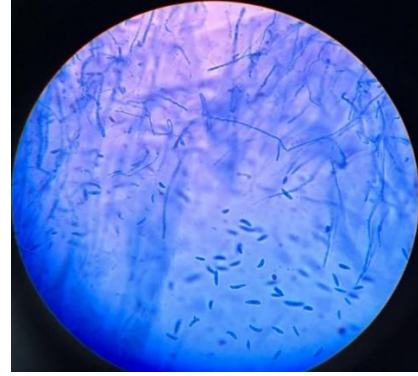**Fig. 1 & 2: KOH mount**



**Fig. 3: *Candida albicans* on SDA**



**Fig. 4: *Fusarium* on SDA**



**Fig. 5: LPCB mount of *Fusarium spp***

### Discussion

Mycotic keratitis is an important cause of ocular morbidity in rural population of developing countries where agriculture is the main occupation. Lack of knowledge, illiteracy and ignorance of patients along with less ease of access to tertiary care set up results in delayed diagnosis of these cases, which may in turn lead to complications. Hence early diagnosis for effective treatment is necessary in these cases.

The different socio-demographic factors observed in our study is compared with other studies in table 2. In our study, the prevalence of fungal keratitis was more in male patients with male to female ratio of 1.57:1. This is in concordance with study done in Bengaluru<sup>11</sup> which showed similar male to female ratio of 1.6:1 suggesting that male patients are more prone to infectious keratitis due to their outdoor activities. But another study done in Nepal<sup>12</sup> showed higher prevalence of fungal keratitis in female patients with male to female ratio of 1:1.4.

We observed that fungal keratitis was more common in patients between 41–50yrs age group (38.89%) which was similar to other study done by Gandhi. S et al.<sup>13</sup> where 36.36% of patients belonged to 40-60yrs age group.

Majority of patients with fungal keratitis in our study were farmers by occupation, while other patients had different outdoor occupation like daily labourers & drivers. Another study<sup>12</sup> also showed higher prevalence of fungal keratitis in farmers.

We observed that vegetative trauma was the most common predisposing factor to fungal keratitis followed by dust particles and Diabetes mellitus in our study. Similar findings were observed in study done in Bengaluru<sup>11</sup> where trauma was the main risk factor, especially vegetative trauma, which was more commonly implicated in causing fungal keratitis in farmers. The same study also showed that apart from trauma, Diabetes mellitus and use of contact lens were other important predisposing factors.

The above findings suggest that male patients with outdoor activities like farming and daily labour were more prone to infectious keratitis when compared to office workers and home makers. Fungi cannot penetrate intact cornea and trauma provides the required breach in the epithelium facilitating fungal penetration. Thus trauma was the most common predisposing factor in causation of fungal keratitis.

Apart from trauma, Diabetes mellitus and contact lens usage were the other important risk factors implicated especially in office workers and home makers.

The prevalence of fungal keratitis in our study was 1.54%. It is higher when compared to studies<sup>14,15</sup> done in China which showed a prevalence rate of 0.007% and 0.015% respectively. Many studies<sup>11-13</sup> in India have conducted prospective studies as well as retrospective analysis of fungal keratitis. But there is very less data regarding prevalence rate in India and many research works are further needed in this regard.

In our study 55.56% of cases were positive for fungal culture. This is similar to study done by N. Padmaja et al.,<sup>16</sup> where 50% of cases showed positive fungal culture. A study done in Haryana<sup>17</sup> showed higher culture rate of 61.53%, while another study done in Madhya Pradesh<sup>13</sup> showed lower culture rate of 32%.

The different fungal species isolated in our study and other studies are compared in the table 3. In our study *Candida albicans* was the most common fungal species isolated, followed by *Aspergillus species* and *Fusarium species*. This is in contrast with study<sup>18</sup> done in North India which showed *Aspergillus species* as the most common isolate and also with studies<sup>11,19</sup> done from South India and Nepal<sup>12</sup> which showed *Fusarium species* as the most common isolate from fungal keratitis cases.

One study done in Uttarkhand<sup>18</sup> has reported isolation of *Candida spp* from fungal keratitis cases, but not as the commonest isolate. We isolated *Bipolaris* as a rare agent of fungal keratitis in our study. A study from Nepal<sup>12</sup> has also reported isolation of *Bipolaris*. Not many Indian studies have reported isolation of this species.

From the above findings it could be understood that there are many fungal species yet to be isolated and reported as the causative agents of fungal keratitis from different parts of the country.

## Conclusion

Fungal keratitis occurring after trivial trauma to the eyes with plant or vegetable matter while farming does not present with typical signs & symptoms as that of bacterial or viral keratitis. Many patients do not seek immediate care after trauma due to ignorance, difficulty in accessing medical centre or financial constraints and visit ophthalmologist only when their compromised vision interferes the daily activities.

Hence, these cases present with prolonged symptoms or complications (impending perforation or invasive complications) which may require enucleation, making them diagnostic and therapeutic challenge. Early diagnosis and initiation of appropriate treatment can prevent the occurrence of complications.

## Acknowledgements

We sincerely thank the staff of Ophthalmology department of our hospital for their help, support and guidance during this study.

**Conflict of Interest:** None.

## References

- Assudani HJ, Pandya JM, Sarvan RR, Sapre AA, Gupta AR, Mehta SJ. Etiological diagnosis of microbial keratitis in a tertiary care hospital in Gujarat. *Natl J Med Res* 2013;3:60-62.
- Whitcher JP, Srinivasan M, Upadhyay MP. Corneal blindness: A global perspective. *Bull World Health Organ* 2001;79:216-217.
- Procop G.W, Church D.L, Hall G.S, Janda W.M, Koneman E.W, Schreckenberger P.C, et al., Koneman's color atlas and text book of diagnostic Microbiology, 7<sup>th</sup> edition, Philadelphia: Lippincott; 2017, chapter 2, pg 95.
- Robert C. Arff, Grayson's Diseases of the Cornea, 4th edition, Mosby Publications, p257-269.
- Saha R, Das S. Mycological profile of infectious keratitis from Delhi. *Indian J Med Res* 2006;123:159-164.
- Parmar P, Salman A, Kalavathy CM, Kaliamurthy J, Thomas PA, Jesudasan CA. Microbial keratitis at extremes of age. *Cornea* 2006;25:153-158.
- Colle JG, Marr W. Specimen collection, culture containers and media. Mackie and McCartney Practical Medical Microbiology 14th ed. New York: Churchill Livingstone; 1996. p. 95-100.
- Tille P. Role of microscopy in the diagnosis of infectious diseases. Bailey and Scott's Diagnostic Microbiology. 11th ed. St. Louis: Mosby; 2002. p. 122-3.
- Larone DH. Medically important fungi. 4th ed. ASM Press, Washington DC. Part III Laboratory technique; p 296, 298, 300, 304, 307.
- Chander J. Text book of medical mycology. 3rd ed. Appendix A - Fungal culture media. Mehta publishers, New Delhi; January 2009.p. 512.
- Ranjini CY, Vandana VW. Microbial profile of corneal ulcers in a tertiary care hospital in South India. *J Ophthalmic Vis Res* 2016;11:363-367.
- Suwal S, Bhandari D, Thapa P, Shrestha MK, Amatya J. Microbiological profile of corneal ulcer cases diagnosed in a tertiary care ophthalmological institute in Nepal. *BMC Ophthalmol* 2016;16:209.
- Gandhi S, Shakya DK, Ranjan KP, Bansal S. Corneal ulcer: A prospective clinical and microbiological study. *Int J Med Sci Public Health* 2014;3:1334-1337.
- Song X, Xie L, Tan X, Wang Z, Yang Y, et al. (2014) A Multi-Center, Cross-Sectional Study on the Burden of Infectious Keratitis in China. *PLoS ONE* 9(12): e113843. doi:10.1371/journal.pone. 0113843.
- Cao J, Yang Y, Yang W, Wu R et al.: Prevalence of infectious keratitis in Central China. *BMC Ophthalmol* 2014;14:43.
- Padmaja N, Nageswara Rao P. "Microbiological Study of Corneal Ulcers at KIMS, Amalapuram". *J of Evolution of Med and Dent Sci* 2014;3:4525-4528.
- Sharma K, Mehta S, Singh VA, Jamwal S, Sharma T, Manjhi PK. A profile of corneal ulcers – 2 years study from rural hospital, Haryana. *IOSR-J of Dent and Med Sci (IOSR-JDMS)*2014;13:94-97.
- Changte L, Pandey S, Umesh. Epidemiological and Microbiological Profile of Infectious Corneal Ulcers in Tertiary Care Centre, Kumaon Region, Uttarakhand. *Int J of Sci and Res Pub (IJSRP)* 2015;5:1-5.
- Sengupta S, Rajan S, Reddy PR, Thiruvengadkrishnan K, Ravindran RD, Lalitha P, et al. Comparative study on the incidence and outcomes of pigmented versus non pigmented keratomycosis. *Indian J Ophthalmol* 2011;59:291-296.

**How to cite this article:** Vasudha CL, Anuradha B, Krishna BN. A study on mycological profile of corneal ulcers in a tertiary care hospital. *Indian J Microbiol Res* 2019;6(1):1-5.