

11 Years experience of treatment of olfactory groove meningioma in tertiary care centre

Prakash Mahantshetti^{1,*}, Dhananjaya Bhat²

¹Assistant Professor, ²Professor, ^{1,2}Dept. of Neurosurgery, ¹Jawaharlal Nehru Medical College, Belgaum, ²National Institute of Mental Health and Neuro Sciences, Bengaluru, India

***Corresponding Author: Prakash Mahantshetti**

Email: drprakashsm@gmail.com

Abstract

Objective: Retrospective analysis of the clinical, radiological presentation, surgery and outcome following management of OGMs at our institute over a eleven year period

Materials and Methods: A total of 28 cases operated for olfactory groove meningioma at the Department of Neurosurgery, National Institute of Mental Health And Neurosciences, Bangalore over a 11 year period were analyzed for clinical and radiological presentation, detailed study of operative notes for surgical approaches, neuro-radiological evaluation, follow-up examination, and histopathology slides.

Results: Twenty eight patients underwent surgery for olfactory groove meningiomas. The mean and median ages of the patient were 49 and 49.5 years respectively (range 32-71 years). Of these 7 were male and 21 female patients. Headache was the most frequent presenting symptom seen in 21 cases (75%) Bifrontal craniotomy was the predominant approach used in 25 cases (89%), unilateral frontal craniotomy in 1 cases (%) and pterional in 2 case (7%). Post-operative complications seen were seizures, CSF rhinorrhoea, post-operative frontal hematoma which required re exploration and evacuation of hematoma.

Conclusion: It is important for the psychiatrist to be aware of olfactory groove meningiomas as majority of them present with neuropsychiatric manifestations for early detection of these tumours as safe surgical excision with low mortality and morbidity can be obtained in these tumours despite their large size at presentation.

Keywords: Tumours, Olfaction, Meningioma.

Introduction

Olfactory groove meningiomas usually arise over the cribriform plate of the ethmoid bone extending from the crista galli to the frontosphenoid suture.¹ The frequency of these tumours among all meningiomas is 8-13 %.²

The olfactory groove meningiomas are highly vascular tumours with blood supplied by anterior and posterior ethmoidal arteries, the branches of external carotid artery. There is also some amount of vascularity arising from middle meningeal artery as well as meningeal part of the ophthalmic artery.

This presentation of these tumours is with raised intracranial pressure after a long period because of the slow growth. These tumours commonly present with headache, visual disturbances and change in cognitive functions overtime.³ There are controversies regarding the best surgical approach and there is no consensus for best approach. Hence this study is undertaken with an objective of retrospective evaluation of clinical and radiological presentation, pathological grading, surgical management, its outcome and complications of olfactory groove meningioma in our institution.

Olfactory groove meningioma (OGM):

Cushing in 1938 with an experience of management of 29 patients of Olfactory groove meningioma, described these tumours in detail with respect to its anatomy, pathology and the surgical principles of its management.⁴

These tumours have some peculiarities being slow growing tumors, bilateral and asymmetrical. There are intratumoral calcifications in 15–20% of cases.^{5,6} OGM can present due to their large size resulting in compression of the optic nerve and chiasm and hence affecting vision. The most common presenting symptoms are various combinations of personality changes, headache, anosmia, and visual impairment.

Clinical presentation

Olfactory groove meningioma's manifest only after they attain significant size.^{7,8} Batteries of studies have reported about 20.7–71% of these patients with altered cognitive functions.⁹ The study by Solero et al have documented euphoria in 59.1% of the patients.⁹ Few Studies have also reported that on clinical examination, about 53.8–100% of patients had impaired olfactory functions preoperatively.^{7,10-12} This could be possibly due to interruption of the blood supply to the olfactory nerves or physical damage to fila olfactoria during surgery. Visual impairment is seen to occur in 15.3– 58.1% of the patients preoperatively.⁹⁻¹¹

Surgical approach

Surgical methods viz; standard fronto-temporal, unilateral or bilateral subfrontal approaches depending on tumor location and the relationship of the anterior cerebral arteries and the optic nerves were chosen to have adequate visualization of the tumor and to prevent damage to neural

and vascular structures.^{11,13-15} Bifrontal craniotomy which involves opening of frontal nasal sinus has been used by several investigators.^{16,17} The pterional approach for these tumours preferentially used by Yasargil was proposed by Hassle in 1989.¹⁰

Recurrence

Different series have reported complete removal in 65-100 % of the cases.^{9,10,17} The risk of recurrence is dependent on the extent of surgical resection¹⁸⁻²⁰ and it was found that recurrences are higher when the tumor invading the bone is not completely excised.^{17,21,22}

Mortality

The mortality rates for surgery of olfactory groove meningioma have declined with the use of microsurgical techniques from 0 to 33% in earlier series^{9,12,17,23} to 4.4 % in recent published series.^{10,12,14,24} Mortality is seen in patients with malignant postoperative edema, cerebrovascular event, or intracranial hemorrhages.

Morbidity

The complications seen post operatively are presence of a CSF leak, local infections including bone flap and intracranial haemorrhages as these tumours are frequently large as well as injury to the superior sagittal sinus or its draining veins.

Materials and Methods

This is a retrospective study. The data was collected for the period from January 2001 to December 2011. A total of 28 patients were operated for olfactory groove meningioma at the Department of Neurosurgery, National Institute of Mental Health And Neurosciences, Bangalore. The list of patients having undergone surgery for the same were obtained from the operation theatre records followed by study of files of these patients from the medical records department for clinical and radiological presentation, detailed study of operative notes for surgical approaches, neuroradiological evaluation, follow-up examination, and histopathology slides. Radiology and histopathology slides were reviewed. Follow up details were obtained from files, OPD exam and telephonic interviews.

Results

Demographic data

Twenty eight patients underwent surgery for olfactory groove meningiomas from 2001 to 2011.

The mean and median ages of the patient were 49 and 49.5 years respectively (range 32-71 years)(Table 1). Of these 7 were male and 21 female patients as shown in the Table 2.

Table 1: Age distribution

Median of ages at diagnosis	49.5
Range of ages at diagnosis	32– 71

Table 2: Sex distribution

Sex of patient	Number of patients
Male	07
Female	21

Clinical presentation

Headache was the most frequent presenting symptom reported by 21 patients (75%), followed by psychiatric manifestation in 15 patients (53.5%), visual symptoms in 10 patients (35.5%), seizures in 6 patients (21%), memory disturbances in 6 patients (21%) and neurologic deficit in 4 patients (14%) (as shown in Table 3 and Graph 1). Papilloedema was seen in 7 patients. Olfaction was impaired in 16 patients. It was presenting symptom in 4 patients whereas in remaining 12 olfaction was found to be impaired only on testing. In 6 patients olfaction could not be tested either due to decreased consciousness level or were uncooperative and in remaining 6 it was found to be normal.

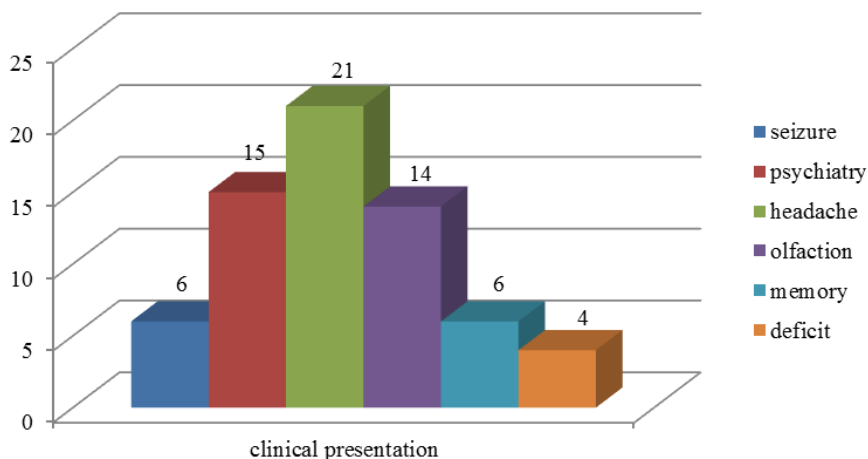
Table 3: Presenting symptoms

Symptoms at presentation	Number of patients
Seizure	06
Psychiatric symptoms	15
Headache	21
Impaired olfaction	16
Memory disturbances	06
Deficits	04

The psychiatric manifestations that were seen in 15 patients consisted predominantly of social withdrawal, apathy, uninterested in surrounding and sometimes excess anger, crying abusiveness and temper tantrums. The duration of these psychiatric symptoms before diagnosis of lesion ranged from as less as 15 days to 4 years. The duration of psychiatric symptoms were sometimes so long that 2 of the patients were on long term antipsychotic before being evaluated for the lesion.

Visual symptoms a presenting symptom was seen in 8 patients whereas in 2 patients vision could not be tested as they were in altered sensorium. Of the 8 patients 3 had unilateral vision loss and rest had bilateral vision loss. There was severe visual loss in 7 patients with 3 having no perception of light.

Graph 1: Bar chart showing frequency of various clinical presentations



Radiological studies Preoperatively, all patients underwent CT and/or MRI, including axial, coronal, and sagittal T1-weighted images with and without contrast

enhancement and T2-weighted images.(Fig. 1 and Fig. 2 showing preoperative MRI and CT Images)

MRI is done to know the relation of the tumour with anterior cerebral arteries, optic nerves and chiasma.

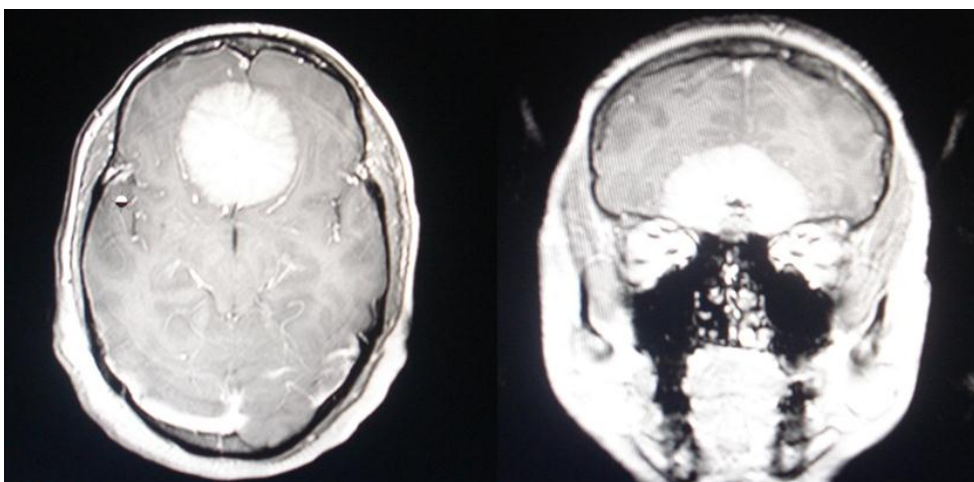


Fig. 1: Pre operative MRI axial and coronal showing olfactory groove meningioma respectively.

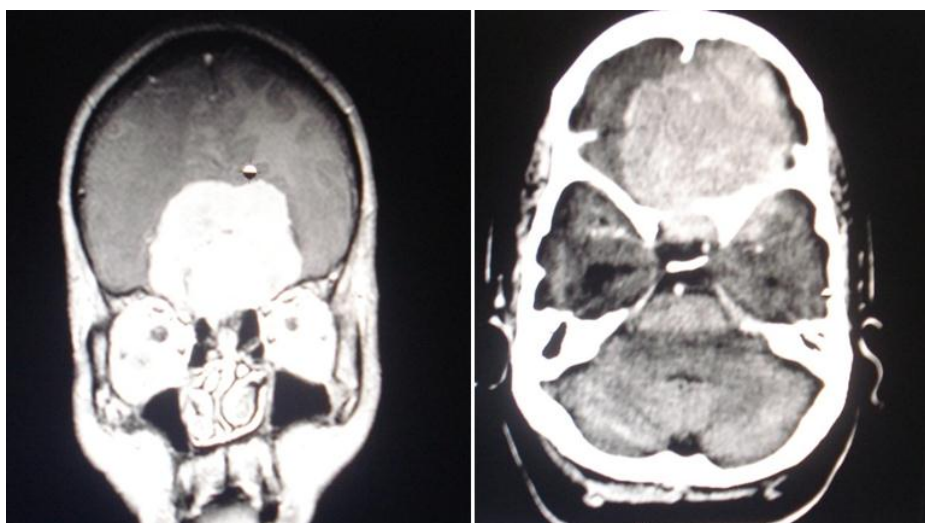


Fig 2,3: Showing MRI and axial CT Contrast of patient showing large olfactory groove meningioma respectively.

The size of the tumours were estimated from the preoperative imaging studies. The tumours were classified

based on the size on preoperative imaging as follows (shown in Table 4)

Table 4: Distribution of size of tumors

Size of the tumour	Number of cases
Small 0-2 cms diameter	0 Patients (0%)
Medium 2-4 cms diameter	02 Patients (7.1%)
Large 4-6 cms diameter	16 Patients (57.1%)
Giant > 6 cms diameter	10 Patients (35.8%)

Majority of the lesions in our study were large constituting 26/28(92.9%).

Surgery

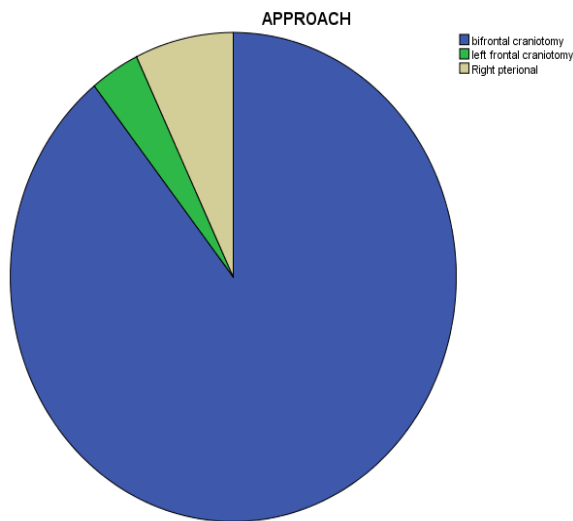
Craniotomy: Bifrontal craniotomy was the predominant approach in our patients 25 cases(89%), unilateral frontal

craniotomy in 1 cases(%) and pterional in 2 case (7%)(depicted in table 5 and Graph 2)

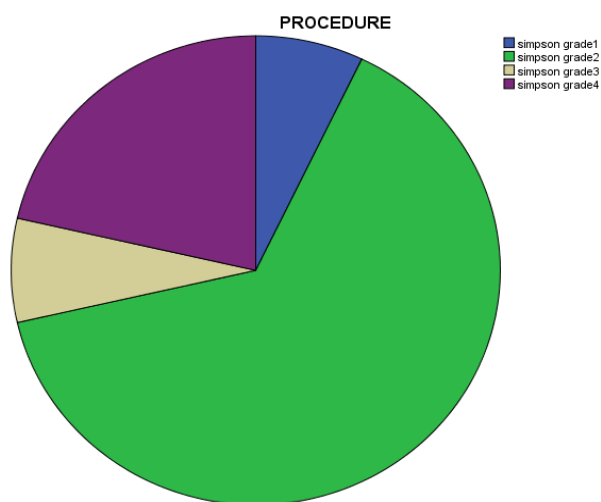
Table 5: Distribution of surgical approach

Surgical approach	Number of cases
Bifrontal craniotomy	25
Left frontal craniotomy	01
Right pterional craniotomy	02

Graph 2: Pie chart showing surgical approaches

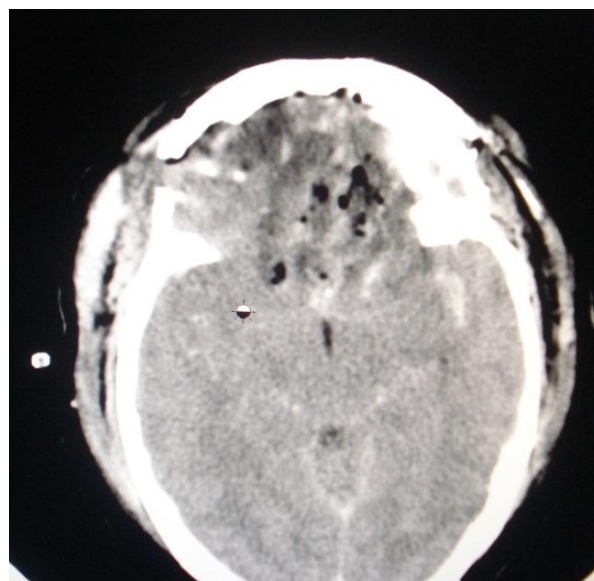


Graph 3: Pie chart showing extent of resection



Extent of resection

Tumor debulking and excision was done using the standard procedures as explained before. Simpsons grading was used to quantify of extent of resection. The degree of tumour removal was complete excision including the involved dura and bone (grade 1) in 2 cases, complete excision with cauterisation of dura (grade 2) in 18 cases and gross total excision with small tissue left around the anterior cerebral artery (grade 3 and 4) in 8 cases (as shown in Graph 3).



Picture 4: Post-operative CT of olfactory groove meningioma

Post-operative complications

Post-operative seizures were seen in 4 patients, 2 were new onset seizures. Three patients developed post-operative CSF rhinorrhoea, one of whom developed meningitis. Of these one patient was managed with lumbar drainage and antibiotics and 1 underwent the coperitoneal shunt and one ventriculoperitoneal shunt. One patient had post-operative frontal hematoma which required re exploration and

evacuation of hematoma. One patient who was operated for recurrence developed an ischaemic stroke unrelated to the surgery in postoperative period and was managed conservatively. Three patients had subgaleal or extradural collection which did not need any intervention (as shown in Table 6)

Table 6: Postoperative complications

Surgical approach (no of patients)	Complication	No of patients (%)	Comment
Bifrontal	Subgaleal collection	2	Conservative treatment
	New seizure	2	AEDs
	CSF rhinorrhoea	2	TP shunt in 1 and VP shunt in other
	Meningitis	1	Antibiotics
	Stroke	1	Conservative treatment
	Extradural collection	1	Conservative treatment
	Frontal hematoma	1	Re exploration
Unilateral frontal	No complication	-	-
Pterional	CSF rhinorrhoea	1	Lumbar drainage

Histopathology

According to histopathology WHO classification there were 22 cases of grade 1 and 6 cases of grade 2 meningioma. Grade 1 meningiomas constituted 7 cases (25%) of meningothelial meningioma, 13 (46%) transitional

meningioma, 1 (3%) angiomatous and 1 (3%) secretory whereas grade 2 constituted 6 (23%) cases of atypical meningioma (as shown in Table 7)

Table 7: Histopathological distribution of tumors

Grades	Histopathology	Number of Patients
Grade 1	Meningothelial meningioma	07
	Transitional meningioma	13
	Angiomatous meningioma	01
	Secretory meningioma	01
Grade 2	Atypical meningioma	06

Condition at discharge

There was one death in postoperative period due to malignant cerebral edema. Of the 15 patients with preoperative psychiatric symptom all but one improved in post-operative period who had persistent euphoria in post-operative period. Visual symptoms improved in one patient in post-operative period.

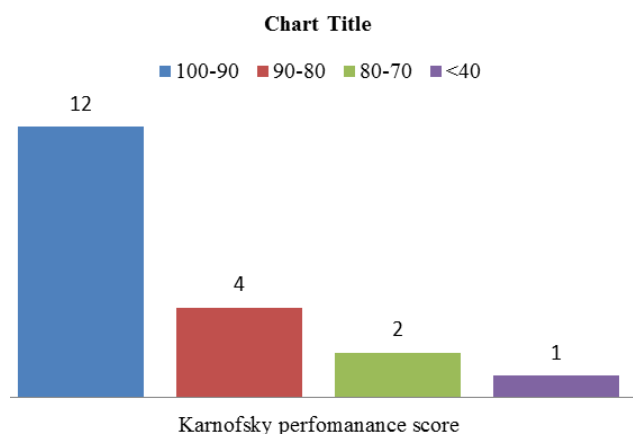
Follow up

Follow up was available for 19 patients with median follow up of 06 months, mean of 11 months and ranging from 0-72 months. The Karnofsky performance score was 90-100 in 12 patients, 80-90 in 4 patients and 2 patients had score of 70-80 at last follow up (shown in Table 8 and graph 4). There was one death at 11 months follow up who developed meningitis and treated with antibiotics for the same.

Table 8: Karnofsky score at follow up

Karnofsky score	Number of Patients
100-90	12
90-80	04
80-70	02
<40	01

At follow up all of the patients who presented with psychiatric symptoms improved except for one patient who had aggressive behaviour with irrelevant and excessive talking. Three patients of those who had preoperative impaired olfaction reported improvement in olfaction.

Graph 4: Bar chart of KPS at follow up

Recurrence

Three cases were operated for recurrence one previously operated in our institute and two other in different hospital.

Recurrence was seen after 72 months in patient previously operated at our institute. He had undergone Simpson grade 2 excision at first surgery. He underwent re exploration and excision. The other 2 patients who had recurrence occurred at 10 and 24 months respectively.

Discussion

Our study consists of 28 cases treated in 11 years. The sex distribution showed female predominance with sex ratio of 3:1. This is in accordance with various studies which show higher female sex ratio^{25,26}

There are several studies that described olfactory groove meningiomas with respect to clinical findings, types of neurosurgical approaches, results and rate of recurrences.^{5,6,12,27}

Clinical presentation

These tumours are inherently slow growing and hence have varied time interval from the first symptom to diagnosis being reported to be up to 14 years.⁵ In our studies time frame for diagnosis varied from as short as 15 days to 4 years with average time of diagnosis being 1 year.

The most common and principal symptoms of olfactory groove meningiomas are impaired cognitive functions, headache and visual disturbances.^{13,28}

Headache and psychiatric manifestation are the most common presenting symptom in our study. They were seen in 75% and 53% of the patients respectively. In our study major psychiatric manifestations were reported were apathy, excess anger, wandering and social incontinence as compared to 20.7%-71% of patients with mental status changes in other series^{9,12,28}

Decreased olfaction was appreciated by 16 of our 28 patients though it was not a presenting symptom in all constituting 57% of the patients. This finding is similar with earlier studies who have reported Preoperative anosmia in 53.8-100% of the patients.

Visual impairment was seen preoperatively in 15.3-58.1% of the patients⁹⁻¹¹ whereas in our study 10 cases (35.5%) had preoperative visual impairment. Classical Foster-Kennedy Syndrome was not observed in our study.

Surgical Approaches

A number of different surgical approaches have been described for olfactory groove meningioma including bifrontal craniotomy with bifrontal polectomy (Dandy 1938),²⁹ unifrontal craniotomy with partial excision of bifrontal lobes (Cushing and Eisenhardt),⁴ bifrontal craniotomy alone with retraction of frontal lobes (Tönnis 1938),³⁰ unilateral pterional-transsylvian approach (Yasargil), pterional approach, fronto-orbital approach, lateral supraorbital approach to minimally invasive endoscopic techniques and craniofacial approaches. Tönnis described bifrontal craniotomy and tumour resection through interhemispheric route after ligation of the superior sagittal sinus and detaching the falx from the crista galli.³⁰ We performed the bilateral craniotomy and subfrontal approach in 25 cases (89%). The unilateral subfrontal approach was used in 1 case (3.5%) and the pterional approach was performed in 2 cases (7.5%). According to Simpson's grading system for removal of meningiomas, complete excision including the involved dura and bone (grade 1) in 2 cases, complete excision with cauterisation of dura (grade 2) in 18 cases and gross total excision with small tissue left around the anterior cerebral artery (grade 3 and 4) in 8. In our study 25 of the cases underwent bifrontal craniotomy and excision of the tumour. The bifrontal approach provides a panoramic view of the anterior skull base especially for bilateral, broadbased tumours and their dural attachment as well as bone that has infiltrated. Hassler used the pterional approach for these tumours, also routinely used by Yasargil¹⁰ in order to anticipate complications from the frontal venous system and from opening of the frontal sinus. We had 2 cases that underwent pterional approach for excision. One of the patients had post-operative CSF rhinorrhoea managed with lumbar drainage. We used the unilateral subfrontal approach in 1 case. This approach allowed better access to the dural attachment of tumor compared to the more lateral based pterional approach and at the same time avoids the bilateral retraction of frontal lobe as may happen with the bilateral subfrontal approach.

Surgical outcome

The functional status improvement after surgical treatment of patients with olfactory groove meningioma is satisfactory and cognitive functions generally improve the most followed by visual disturbance.³¹ Improvement in psychiatric symptoms is generally good seen to occur in 80% to full recovery has been reported. It has been observed that mental status improvements occur after subsidence of frontal lobe edema.²⁷ In our study all but one patient who had presented with psychiatric symptoms improved at follow up.

Patients who had objective preoperative visual disturbance generally improved after surgery seen in about

72% of patients.³² There is correlation between the degree and duration of the preoperative deficit and degree of visual improvement.

The effects of treatment on patients who presented with seizures preoperatively was generally good with patients being seizure free and off anticonvulsant therapy postoperatively.

The outcome of surgery on anosmia was poor²⁷ even when anatomic preservation of at least one olfactory nerve was accomplished.³³ In our study 3 patients on follow up had preserved smell.

Postoperative complications

The most common complication seen in our study was the presence of a postoperative CSF leak which was conservatively managed with bed rest, fluid restriction and lumbar puncture with removal of CSF. Other studies have reported infections, hematoma, epidural empyema, CSF leakage and new neurological deficits as postoperative complications in Olfactory Groove Meningioma.²⁵

In our patients, leak ceased after several days in one patient and two patient required CSF diversion procedure. This is also the most documented complication in literature seen to occur in 7 % of patients. There were no late recurrences of CSF leak. The vast majority of CSF leaks respond to the use of a lumbar drain, and further surgery is needed in fewer than 2% of patients.

In our study one patient developed post-operative frontal hematoma who required re exploration and evacuation seen to occur in 3% of patients in literature possible due to the large size as well as injury to the superior sagittal sinus.

Mortality rates for removal of these tumours in the literature ranges from 0% to as high as 22.7%.⁴ We had one death in postoperative period who developed severe cerebral edema.

Recurrences

The rate of recurrence seems to be proportional to the time period of follow up and also the completeness of excision at the first surgery. There were three recurrence in our study one had a Simpson grade 2 resection at first surgery and other had grade 4 resection at the first surgery. Tumour in these cases has probably invaded into the paranasal mucosa and had not been removed at first surgery. A complete removal of the olfactory groove meningioma is reported to be achieved in 67–100% in different series.^{9,10,17}

Conclusion

Most of olfactory groove meningiomas are large or giant (>4cm) when detected.

Headache, behavioural and psychiatric disturbances are common presenting complaints.

Though majority have impaired olfaction it is not the presenting complaint in most.

It is important for the psychiatrist to be aware of olfactory groove meningiomas and their presentations for early detection of these tumours with low mortality and morbidity.

Safe surgical excision with low mortality and morbidity can be obtained in these tumours despite their large size at presentation.

As most of these tumours are benign it is prudent to leave behind small tumour residue adherent to major vessels (anterior cerebral artery).

Surgical excision results in improvement of raised intracranial pressure and psychiatric manifestations in most of the patients.

Conflict of Interest: None.

References

1. Pepper J, Hecht SL, Gebarski SS, Lin EM, Sullivan SE, Marentette LJ et al. Olfactory groove meningioma: discussion of clinical presentation and surgical outcomes following excision via the subcranial approach. *Laryngoscope* 2011;121:2282–2289.
2. Nakamura M, Struck M, Roser F, Vorkapic P, Samii M. Olfactory groove meningiomas: clinical outcome and recurrence rates after tumor removal through the frontolateral and bifrontal approach. *Neurosurg* 2007;60:844–852.
3. Ciurea AV, Iencean SM, Risea RE, Brehar FM. Olfactory groove meningiomas. A retrospective study of 59 surgical cases. *Neurosurg Rev* 2011;30;
4. Cushing H, E.L.: Meningiomas: Their Classification, Regional Behaviour, Life History, and Surgical End Results.. Springfield, IL, Charles C Thomas, 1938.
5. Nakamura, M. Olfactory groove meningiomas: clinical outcome and recurrence rates after tumor removal through the frontolateral and bifrontal approach. *Neurosurg* 2007;60(5):844-852.
6. Spektor, S. Olfactory groove meningiomas from neurosurgical and ear, nose, and throat perspectives: approaches, techniques, and outcomes. *Neurosurg* 2005;57(4):268-280.
7. Bakay, L., Olfactory meningiomas. The missed diagnosis. *JAMA* 1984;251(1):53-55.
8. Carvi y Nievas, M.N., Volume assessment of intracranial large meningiomas and considerations about their microsurgical and clinical management. *Neurol Res* 2007;29(8):787-797.
9. Bakay, L. and H.L. Cares, Olfactory meningiomas. Report on a series of twenty-five cases. *Acta Neurochir (Wien)*, 1972. 26(1):1-12.
10. Hassler, W. and J. Zentner, Pterional approach for surgical treatment of olfactory groove meningiomas. *Neurosurg* 1989. 25(6):942-945.
11. Mayfrank, L. and J.M. Gilsbach, Interhemispheric approach for microsurgical removal of olfactory groove meningiomas. *Br J Neurosurg* 1996. 10(6):541-545.
12. Solero, C.L., S. Giombini, and G. Morello, Suprasellar and olfactory meningiomas. Report on a series of 153 personal cases. *Acta Neurochir (Wien)* 1983;67(3-4):181-194.
13. Hullay, J, Planum sphenoidale meningioma. Attachment and blood supply. *Acta Neurochir (Wien)*, 1980;52(1-2):9-12.
14. Turazzi, S, The pterional approach for the microsurgical removal of olfactory groove meningiomas. *Neurosurg* 1999. 45(4):821-825; discussion 825-826.
15. Paterniti, S, Basal meningiomas. A retrospective study of 139 surgical cases. *J Neurosurg Sci* 1999;43(2):107-113; discussion 113-114.
16. El Gindi, S., Olfactory groove meningioma: surgical techniques and pitfalls. *Surg Neurol* 2000;54(6):415-417.
17. Obeid, F. and O. Al-Mefty, Recurrence of olfactory groove meningiomas. *Neurosurg* 2003;53(3):534-542; discussion 542-543.
18. Black, P.M., Meningiomas. *Neurosurg* 1993;32(4):643-657.

19. Jaaskelainen, J., Seemingly complete removal of histologically benign intracranial meningioma: late recurrence rate and factors predicting recurrence in 657 patients. A multivariate analysis. *Surg Neurol* 1986;26(5):461-469.
20. Simpson, D., The recurrence of intracranial meningiomas after surgical treatment. *J Neurol Neurosurg Psychiatry* 1957;20(1):22-39.
21. Derome, P.J. and G. Guiot, Bone problems in meningiomas invading the base of the skull. *Clin Neurosurg* 1978;25:435-451.
22. Mirimanoff, R.O, Meningioma: analysis of recurrence and progression following neurosurgical resection. *J Neurosurg* 1985;62(1):18-24.
23. Olivecrona, Surgical treatment of intracranial tumors Olivecrona H (eds) *Handbuch der Neurochirurgie*, 1967. vol. 4 Springer, Ber
24. Symon, Olfactory groove and suprasellar meningiomas Krayenbühl H (eds). *Advances and technical standards in Neurosurgery*, Springer, Wien New York(1977).4: 67-91.
25. Aguiar, P.H., et al., Olfactory groove meningiomas: approaches and complications. *J Clin Neurosci* 2009;16(9):1168-1173.
26. Colli, B.O, Olfactory groove meningiomas: surgical technique and follow-up review. *Arq Neuropsiquiatr* 2007;65(3B):795-799.
27. Bassiouni, H., S. Asgari, and D. Stolke, Olfactory groove meningiomas: functional outcome in a series treated microsurgically. *Acta Neurochir (Wien)*, 2007;149(2);109-121; discussion 121.
28. Tsikoudas, A. and D.P. Martin-Hirsch, Olfactory groove meningiomas. *Clin Otolaryngol Allied Sci* 1999;24(6):507-9.
29. Dandy, W.E., Contributions to Brain Surgery: A. Removal of Certain Deep-Seated Brain Tumors B. Intracranial Approach with Concealed Incisions. *Ann Surg* 1925;82(4):513-525.
30. Tooniss, Zur Operation der Meningeome der Siebbeinplatte (in German) *Zentralbl Neurochir* 1938. 1:1-7.
31. Chee, C.P., et al., Dementia due to meningioma: outcome after surgical removal. *Surg Neurol* 1985. 23(4): p. 414-6.
32. Andrews, B.T. and C.B. Wilson, Suprasellar meningiomas: the effect of tumor location on postoperative visual outcome. *J Neurosurg* 1988;69(4):523-528.
33. Welge-Luessen, A, Olfactory function in patients with olfactory groove meningioma. *J Neurol Neurosurg Psychiatry* 2001;70(2):218-221.

How to cite this article: Mahantshetti P, Bhat D, 11 Years experience of treatment of olfactory groove meningioma in tertiary care centre, *J Neuro sci* 2019;5(1):20-27