

## A rare presentation of Presenilin 1 (*PSEN 1*) Mutation

Jithin Raj. P<sup>1,\*</sup>, Shaji CV<sup>2</sup>, Kabeer KA<sup>3</sup>, Prasanth SR<sup>4</sup>, Nikhil Gladson<sup>5</sup>

<sup>1,5</sup>Senior Resident, <sup>2</sup>Professor and HOD, <sup>3</sup>Associate Professor, <sup>4</sup>Assistant Professor, <sup>1-5</sup>Dept. of Neurology, <sup>1-5</sup>Government T D Medical College, Alappuzha, Vandanam, Kerala, India

\*Corresponding Author: Jithin Raj. P

Email: jjjjrrr49@gmail.com

### Abstract

**Introduction:** Presenilin1 (*PSEN 1*) mutation is a rare mutation which is most commonly associated with the early onset Alzheimer's disease. But it is also mutated in many other conditions which involve the neurological and the extraneurological systems.

**Case report:** 38 year old lady with a family history of cognitive, pyramidal and extrapyramidal involvement for her father and paternal grandmother coming with slowly progressive involvement of the cognitive spectrum with the pyramidal and extrapyramidal involvement. Her neuroimaging was showing only non specific changes like cortical atrophy. But her genetic study was found to be positive for Presenilin1 (*PSEN1*) mutation.

**Keywords:** Presenilin1, Early onset Alzheimer's disease, Cognitive, Pyramidal and extrapyramidal.

### Introduction

Presenilin 1 is a protein which is produced by the gene *PSEN 1* which is located in the chromosome 14.<sup>1</sup> It has 13 exons.<sup>2</sup> This protein acts as a proteolytic subunits of the enzyme  $\gamma$ -secretase<sup>3</sup> which acts as a cleaving agent for many transmembrane proteins. This is considered as an important step in the signal transduction from the cell membrane to the nucleus in many pathways. One such pathway is the Notch signaling which is considered as an important pathway involved in the function of our normal immune system. Another one is the processing of amyloid precursor protein (APP).<sup>4,5</sup>

There are many diseases which are found to be related to multiple mutations in the *PSEN1*. Alzheimer's disease, hydradenitis suppurativa and familial dilated cardiomyopathy are a few of these conditions. Aggregation of beta amyloid plaques especially in the brain is considered as the hallmark of the Alzheimer's disease.<sup>6</sup>

It is now identified that there are at least 220 possible mutations in *PSEN1* gene.<sup>7</sup> Some of these novel mutations are now known to be associated with early onset Alzheimer disease. One such mutation is the missense mutation (Leu166Arg) at an atypical site which is identified in a Spanish family.<sup>8</sup>

### Case report

38 year old lady studied up to 10<sup>th</sup> standard presented with complaints of insidious onset slowly progressive easy forgetfulness in the form of forgetting routine conversations and discussions at home, repeatedly cooking the same food in spite of having food in the house for past 5 years. She used to misplace things like her tooth brush, tooth paste, money and purse. She was keeping these things in unusual locations (money among the utensils in the kitchen).

During that time, her mother noticed personality changes in her in the form of anger outbursts and irritability to elders in the family. She used to get angry at her children for trivial reasons. For last 4years, she had difficulty to initiate sleep. She used make some actions during sleep in

the form of throttling her son, kicking and thrashing her husband

For last 3 years, she was noticed to have walking difficulty in the form of swaying to either side and dragging of both lower limbs especially the left lower limb with tripping episodes and tendency to fall while walking and unsteadiness while turning. For the past 1 year her body was bending to the left side while walking, standing and sitting which was getting relieved only after lying down. For past 1 month, there was history of recurrent forward falls without loss of consciousness, jerking or convulsive movements.

Slurring of speech was noticed for last 3 years as undue stressing of syllables which was worsening progressively.

For last 2 years, she developed slowness in fine motor activities with her left upper limb like dressing, undressing, buttoning, cutting vegetables and opening the lids of kitchen containers. For last 3 months she used to keep her left hand in a fist posture most of the time.

She had word finding pauses and was not able to complete sentences for past 1 year. But she could understand what has been told to. For last 1 year she was having decreased word output.

For last 3 months, she had repetitive behavior in the form of putting all clothes from shelf on her bed and keep on folding it from morning till evening.

No bladder symptoms, disinhibited behavior, fluctuation in symptoms, alteration of sensorium, visual or auditory hallucinations, sudden jerking of body, seizures, cranial nerve symptoms, features of raised intracranial tension or systemic symptoms.

She was born out of a Non consanguineous marriage as a full term normal vaginal delivery. Normal antenatal, natal, post natal and developmental history.

Her father and grandmother were affected with similar illnesses. Her father died at the age of 38 years and grandmother at 65 years.

### On examination

She was Moderately built and nourished.

No icterus/ cyanosis/ clubbing/ lymphadenopathy / pedal edema/ neurocutaneous markers or KF ring.

Her Mini mental status examination score was 22/30.

Her neuropsychological assessment showed impaired attention and vigilance with difficulty in problem solving and abstract thinking.

Her executive functions were impaired with abnormality in response inhibition, set shifting and verbal fluency.

Language testing showed impaired category and phonemic fluency and writing .

Memory testing showed defect in semantic memory, short term memory, visual and verbal memory.

Her ideomotor praxis was normal with impaired ideational and dressing praxis. Constructional ability was also impaired.

There was no visual object agnosia.

Cranial nerve examination showed spastic dysarthria with a scanning quality. Her saccades were hypometric with broken pursuits. Other cranial nerve examination were all normal.

Motor system examination showed bilateral spasticity of both upper limbs and lower limbs.

Axial rigidity was also present. Motor power examination was normal in both upper limbs and lower limbs. All deep tendon reflexes were exaggerated with bilateral extensor plantar response.

Tests of coordination showed bilaterally impaired finger nose test, disdiadochokinesia, heel shin ankle test, toe finger test and grossly abnormal tandem walking. She was walking with a broad base swaying to either side with lateral bending of her trunk and extended posturing of lower limbs and flexed posturing of upper limb.

She had postural instability with positive pull test. Bradykinesia of both upper limbs and dystonic posturing of left hand were there.

Her routine investigations

Hemoglobin – 12 g dL

Total Leucocyte Count : 5060/cmm ,

Differential Count – P 59 L 33 E 10

Platelet count-2.13L

ESR -10

Random blood sugar- 96 mg %

Bilirubin Total: 0.4mg % Direct: 0.1 mg%.

SGPT- 33 U/L; SGOT: 10 U/L,

Serum Total Protein: 7.1 g

Serum Albumin: 3.6 g%

ALP: 88 . fT3: 3.64 (normal)

T4: 7.8 micg/dl (normal)

TSH: 1.87 (normal)

Chest X Ray PA view –Normal

ECG- Normal

Peripheral smear –Microcytic Hypochromic blood picture.

No acanthocytes (Repeated 3 times). HIV- Non reactive

HBsAg, Anti HCV-NEGATIVE

VDRL-Non Reactive.

EEG-BETA FAST

USG ABDOMEN- NORMAL

CT HEAD- NORMAL

Pure Tone Audiogram –NORMAL

Nerve conduction study upper limbs and lower limbs was normal

CPK-120 (Normal)

Ca-8.9

LACTATE-3.23 (4.5-20) and PYRUVATE-0.74(0.37-0.88)

Anti Nuclear Antibody-Negative (4.6)(>23)

Rheumatoid Factor: NEGATIVE.

FERRITIN-24.41

SER.IRON-25(23-134)

TIBC-435(250-425)

TR SAT-5.75(15-50)

CERULOPLASMIN-40(15-60) were normal

Her MRI Brain showed cortical atrophy with no evidence of iron deposition or caudate atrophy (Fig 1 and 2)

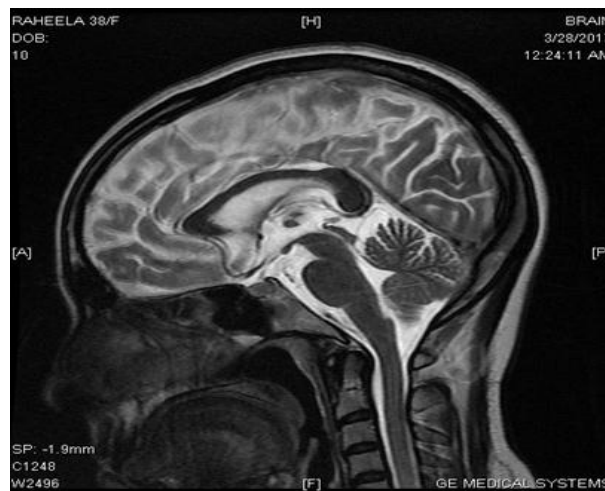

Fig. 1: Sagittal section of MRI Brain showing cortical atrophy

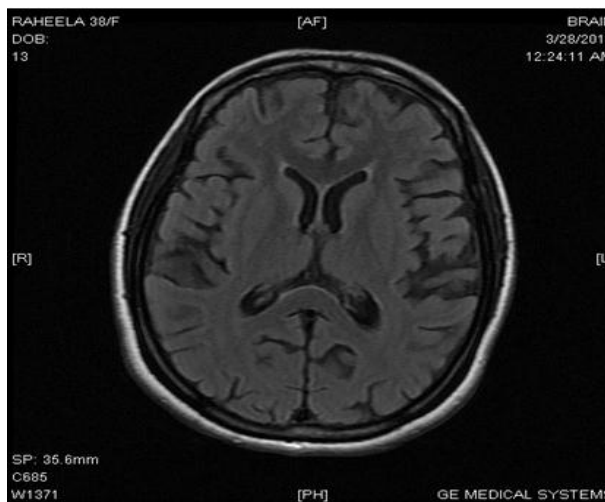


Fig. 2: Coronal section of MRI Brain showing cortical atrophy with no evidence of iron deposition or caudate atrophy

We proceeded with whole exome sequencing in view of her autosomal dominant inheritance and early onset dementia with extrapyramidal syndrome. Genetic analysis showed a Presenilin 1 mutation (PSEN1) [Fig. 3]. Literature review showed PSEN1 mutation presenting as

early onset dementia with extrapyramidal involvement. This is a novel mutation previously not described hence labeled as variant of uncertain significance with probable damaging effect.

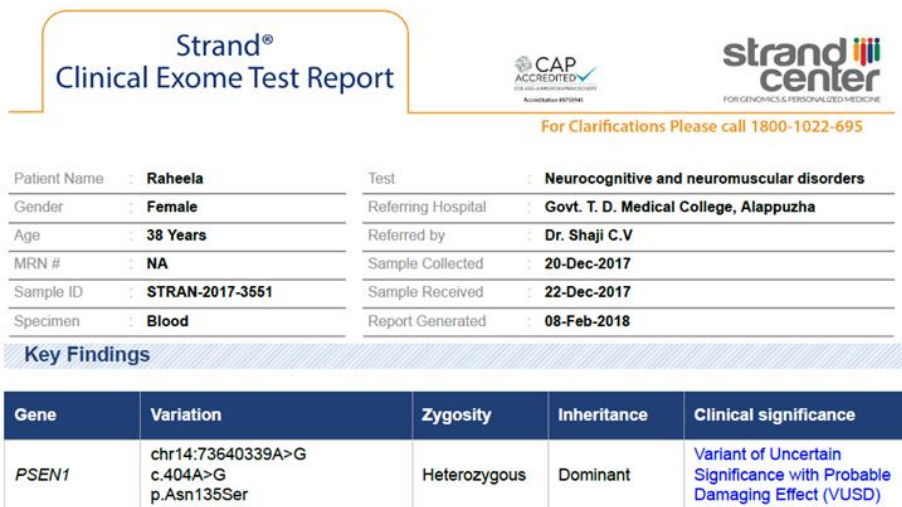

Fig. 3: Whole exome sequencing of the patient showing a Presenilin 1 mutation (PSEN 1).

So this 38 year old lady presented with early onset dementia, extrapyramidal syndrome with pyramidal and cerebellar involvement was found to be having a Presenilin1 mutation.

**Discussion**

Presenilin 1 mutation is a rare genetic mutation which is associated with early onset Alzheimer's disease.<sup>9</sup> It is considered as the somatic mutation of this gene is a factor which causes a proportion of Alzheimer's disease in a sporadic setting.<sup>10</sup> It has multiple other rare manifestations.

Our patient is a 38 year old lady with the family history of a neurodegenerative disease running in her family which involve the cognition, pyramidal, extra pyramidal and the cerebellar systems. She was found to be positive for the genetic mutation analysis of the PSEN 1 gene mutation. Such clinical manifestation of this mutation is very rare in the literature.

So it is to be emphasized that the mutation in presenilin 1 to be considered in patients with multiple neuraxial involvement including the cognition, pyramidal and extrapyramidal systems.

**Conflict of interest:** None.

**References**

1. Larner AJ. Clinical phenotypic heterogeneity of Alzheimer's disease associated with mutations of the presenilin-1 gene *J Neurol* 2006;253(2):139-58 [PMID: 16267640].
2. Miller BL, Boeve BF. The behavioral neurology of dementia. Cambridge University Press; Cambridge, UK; New York: 2009.

3. De Strooper B. Aph-1, Pen-2, and Nicastrin with Presenilin generate an active gamma-Secretase complex. *Neuron* 2003;38:9-12.
4. Mario N, Stefano T, Alessandro C, Valentina V, Aldo P, Carola P et al. Neurodegeneration in Alzheimer Disease: Role of Amyloid Precursor Protein and Presenilin 1 Intracellular Signaling. *J Toxicol* 2012;2012: 187297.
5. Morgan N, Lachlan W, Giuseppe V, Anne L, Imran K, Seyyed H Moussavi N, et al. Differential, dominant activation and inhibition of Notch signalling and APP cleavage by truncations of PSEN1 in human disease, *Human Molecular Genetics*, 2014;23;3(602).
6. Sun L, Zhou R, Yang G, Shi Y. Analysis of 138 pathogenic mutations in presenilin-1 on the in vitro production of Aβ42 and Aβ40 peptides by γ-secretase. *Proc Natl Acad Sci USA* 2017;114:E476-E485.
7. Shea YF, Chu LW, Chan AO, Ha J, Li Y, Song YQ et al. A systematic review of familial Alzheimer's disease: Differences in presentation of clinical features among three mutated genes and potential ethnic differences. *J Formos Med Assoc* 2015
8. Ezquerra M, Carnero C, Blesa R, Oliva R. A novel presenilin 1 mutation (Leu166Arg) associated with early-onset Alzheimer disease. *Arch Neurol* 2000;57(4):485-488.
9. Finckh U. Novel mutations and repeated findings of mutations in familial Alzheimer disease. *Neurogenetics* 20056(2):85-89 [PMID: 1577627].
10. Beck JA. 2004. Somatic and germline mosaicism in sporadic early-onset Alzheimer's disease. *Hum Mol Genet* 13(12):1219-24 [PMID: 15115757]. Bart Dermaut MD, PhD

**How to cite this article:** Jithin RP, Shaji CV, Kabeer KA, Prasanth SR, Nikhil Gladson, A rare presentation of Presenilin 1(PSEN 1) Mutation. *J Neurosci* 2019;5(1)35-37