

## Rhinoplasty by open or closed approach– Our experience

Nilam U. Sathe<sup>1,\*</sup>, Bhavana Narang<sup>2</sup>, Swapna Patil<sup>3</sup>, Pravin Misal<sup>4</sup>

<sup>1</sup>Associate Professor, <sup>2</sup>Senior Resident, <sup>3</sup>Assistant Professor, <sup>4</sup>Senior Resident, <sup>1-4</sup>Dept. of ENT, <sup>1-4</sup>Seth Gordhandas Sunderdas Medical College and King Edward Memorial Hospital, Parel, Mumbai, Maharashtra, India

**\*Corresponding Author: Nilam U. Sathe**

Email: drmeelam\_s@yahoo.co.in

---

### Abstract

Rhinoplasty to an ENT surgeon is a combination of art and science to correct the external nasal deformity as well as restoring normal nasal function. There have been protocols of evaluation of deformity our literature. The debate on open and closed approach as well as on material ideal for augmentation is an ongoing issue amongst the surgeon. In our study we share our experience with rhinoplasty where we work with an open mind to all approaches and material debates and give every individual case its own merit for the choice of approach and material used.

**Keywords:** Rhinoplasty, Open or closed approach.

---

### Introduction

Rhinoplasty to an ENT surgeon is a blend of art, application science of function of nose and surgical skill. Rhinoplasty, the term comes from the Greek literature which though only means moulding or formation of the structure of nose, while working on it we have to remember the functional aspect of nose is as important as the structure.

There are several literatures on the assessment of nasal structure, classification of deformity, patient selection, surgical approaches, and outcomes with each approach. This shall remain a fact; this surgery of art is way beyond the mathematical statistics of dimensions of ideal nose or any protocol of approach for a specific deformity. Every case is to be treated to its own merit.

In our study we have dealt with dorsal nasal deformities, which included saddle nose, dorsal hump, crooked nose, depressed nasal bridge and open book deformity, where project an open mind approach to rhinoplasty, in respect of approach, material used as well as technique of rhinoplasty which was individualised for each patient after thorough assessment and the results were assessed in both functional and cosmetic terms.

### Method and Materials

#### Study site

Out patient department of otolaryngology in tertiary care centre.

#### Study population

Patients with external nasal deformity, meeting the inclusion-exclusion criteria.

#### Study design

Following ethical committee approval a “prospective study” was conducted in patients with external nasal deformity.

#### Study duration

Two years

#### Sample size

55 patients

#### Sampling technique

Random selection of patient

#### Justification of sample size

Keeping in mind the given duration of the study, the topic being a surgical related the sample size will be 55 subjects, with the aim to complete the study within stipulated time.

#### Time frame to address the study

Study duration is two years.

#### Inclusion criteria

1. Patients with nasal dorsal deformities with or without deviation of nasal septum
2. Post traumatic nasal deformity
3. Congenital nasal deformity
4. Post operative nasal deformity

#### Exclusion criteria

1. Active nasal infection
2. Granulomatous disease of nose
3. Age below 18 years
4. Associated craniofacial anomalies
5. Chronic rhinosinusitis
6. Tip or alar deformities
7. Presentation within 3 months of trauma

#### Methodology

##### Patient selection

Was done from the out patient department by random selection of all patients with external nasal deformity between 18 to 50 years of age over duration of two years. Patients with dorsal nasal deformity, meeting the inclusion and exclusion criteria were selected following thorough evaluation by the operating surgeon. An informed consent was taken from all patients participating in the study. A

diagnostic nasal endoscopy was done preoperatively to rule out any coexistent nasal pathology.

**Photographic record**

Preoperative documentation of the photographic record was done meticulously, where pictures in frontal, profile, oblique and basal view were taken on a uniform white background.

Deformity assessment was done classifying the defect, assessing the skin thickness and status of septum was done. Accordingly augmentation or reduction rhinoplasty with or without septoplasty was planned. Surgical approach was based on the individual case considering the deformity, prior procedures and previous scars.

In cases of augmentation rhinoplasty, material used were septal cartilage, choncal cartilage or silicon implant according to the assessment of individual case. All the surgical procedures were performed by the same surgeon. All cases were done in general anaesthesia. Marking of landmarks were done pre operatively before infiltration of local anaesthetic and adrenalin solution. Open or closed approach was decided according to the individual case. Average surgical time was 1 hour.

Post operative care was according to standard protocol of anterior nasal packing for 2 days, external nasal splinting for 6 weeks and 1 week of antibiotics were given.

**Follow up**

Was done 2 weeks, 6 weeks, 12 weeks and 6 months. Post operative photographic record was done in 12 weeks and 6 months.

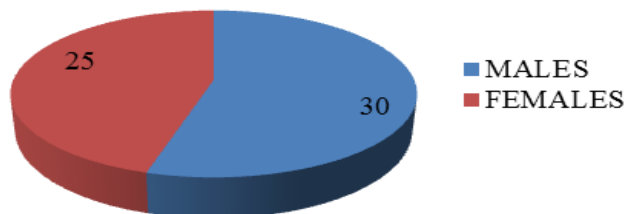
**Results**

In our study, a total of 55 patients participated, between an age ranges of 18 to 60 years, with a mean age of 25.10 years.

The sex distribution was 30 males and 25 females.

**Graph 1:**

**SEX DISTRIBUTION**



**Table 1: Classification of aetiology**

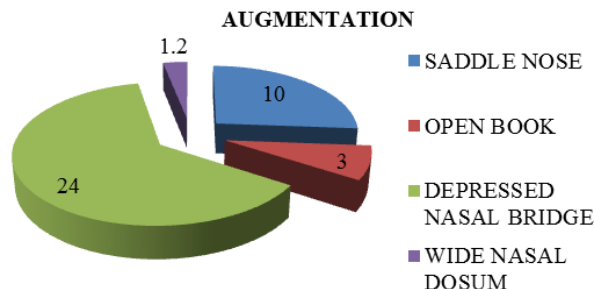
Aetiology	Number of cases
Congenital	31
Trauma	24

**Table 2: Classification of deformity**

Deformity	No. of cases
Saddle nose	10
Dorsal hump	11

Open book deformity	3
Crooked nose	4
Depressed nasal bridge	24
Wide nasal dorsum	5

**Graph 2:**



**Surgical plan**

an augmentation rhinoplasty was planned for 40 patient and reduction was planned was 15 patients

**Approach**

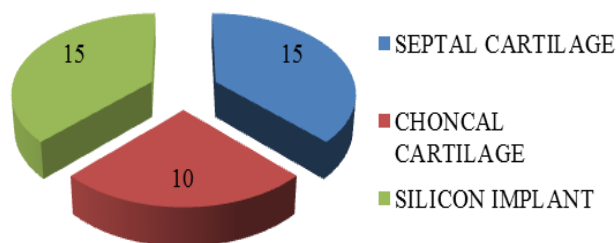
based on the type of deformity, aetiology, scar over the nose and revision case approach was individualised. We planned 53 cases with closed approach while 2 underwent an open approach.

**Augmentation material**

used were septal cartilage in 15 cases, choncal cartilage in 10 cases and silicon implant in 15 cases.

**Graph 3:**

**AUGMENTATION MATERIAL**



**Immediate post operative period**

almost all patients had periorbital edema and echymosis which resolved completely in a week. None of the patient had any severe complication.

**Post op in 3 months**

clinical assessment and photographic record was taken. None of the patients had any complaints of nasal obstruction or symptoms pertaining to sinusitis. There was no patient with extrusion of graft material or suture material. On assessment there was mild edema of the nasal dorsum present. Indurations of skin was present in 10 patients. Photographic record was documented for all patients.

**Post op in 6 months**

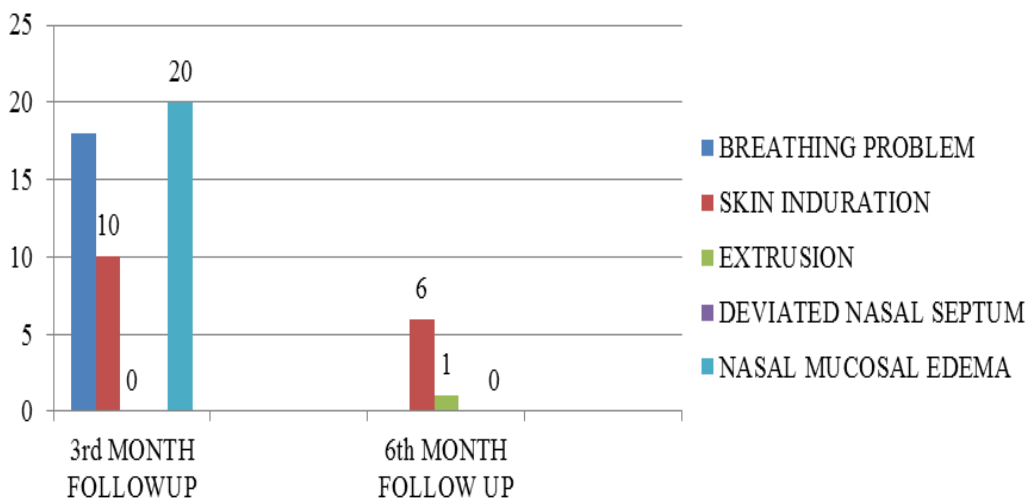
Clinical assessment of result was done for deformity correction, evaluation of subcutaneous edema or any other complication. Patient satisfaction was the prime assessment factor in the assessment. All the patients were satisfied with the cosmetic and functional results. Subcutaneous edema and thickening of skin was still present in 6 patients. No other gross complication was present in any patient.

**Follow up DNE**

was done for assessment of any intranasal extrusion of implant, septal deviation correction and surgical wound healing. Extrusion occurred in one of the patients with silicon implant.

Photographic record was taken in all the views same as the preoperative documentation.

**Graph 4: for Complications**



**Discussion**

The external nasal framework is formed from both bony and cartilaginous structures. Both these components organised together form the internal as well as external nasal structures. These form various components of the support of nasal dorsum and tip that gives a specific structure to the nose. There is no definition of an ideal nose but the symmetry of its structure and the harmony with the face it belongs to categorises it as normal or deformed. Therefore for any corrective plan a perfect idea of anatomy as well as idea of assessment of the structure is required.

In various literatures, dorsal nasal anatomy is described as a smooth plane with an adequate projection from the face according to the gender and age of the person is described. The assessment of nasal structure is done by adequately exposing the entire face and observing in the Frankfort plane. The facial harmony, projection of nose, slant of nasal dorsum and symmetry of structures are seen. According to the age, gender and race assessment of deformity is done. Surgical planning also involves assessment of internal anatomy, as these are as important to correct as the structure of the nose to obtain optimal functional outcome. Surgical results also depend on the skin thickness, healing properties and aetiology of the deformity, hence approach and material used to correct the deformity is accordingly planned.

The entire surgical plan and indication rests on the patients demand for correction and patient’s expectation from the surgery.

Both pre operative and post operative photographic records are a must both for medicolegal purpose as well as

assessment of result. The photographic record standards are followed and accordingly for all cases frontal, oblique, profile and basal views are taken (Fig. 1, Fig. 2).

And accordingly the deformities are described according to the structure. The various dorsal nasal deformities are nasal hump, depressed nasal bridge, saddle nose, wide nasal dorsum, open book deformity and crooked nose.

Both open and closed approaches are equally promoted by various surgeons. This is more today a surgeon’s preference. Though the point still stands valid that the approach should be decided on the merit of the individual case. The factors to be considered are aetiology of deformity, previous surgical procedures, preoperative scars, skin type, graft required and the internal nasal anatomy.

In cases of augmentation rhinoplasty (Fig. 4 and Fig. 5) the best material is again a debate. There is no material that is ideal; each has its advantage and disadvantage. Factors that determine the choice of material depends on various factors like type of deformity, fresh or revision case, availability of the graft material if it is an autologous graft, surgeon preference etc.

Surgical approach is decided according to deformity and aetiology. Though it is primarily a surgeon’s preference, certain cases like revision cases, scarred fibrotic skin, associated pathology like perforated septum or multiple structure deformity. Deformity resulting from trauma or granulomatous diseases usually requires an external approach as the deformity is gross and the skin overlying is

cicatricial. These cases are often deficient in cartilage required for correction of deformity.

Local anaesthetic is infiltrated prior to the procedure which provides a blood less field for surgery, this spreads into the planes and obliterates the landmarks, therefore markings are always done prior to infiltration and the quantity infiltrated is kept to the lower side to ease assessment of accurate correction.

Surgical time is maintained as far as possible as time advances due to tissue manipulation edema sets in, this affects the accuracy of correction achieved (Fig. 3).

Follow up is usually longterm when the tissue edema settles, skin changes come back to normal and graft material

moulds to the new bed. Different complications present in different time intervals. Therefore six months to two years of follow up is required

Outcomes are assessed in terms of patient satisfaction, maintenance of adequate function of the nose and adequate healing of the surgical wound.

Complications associated with rhinoplasty can be early like external and internal edema in the nose, periorbital echymosis and edema, bleeding, wound gaping, infection. Late complications like over or under correction, extrusion of graft material, prolonged edema of subcutaneous tissue, skin scarring, polybeaking, collumellar retraction, bossae can occur.



Fig 1: Closed Reduction Rhinoplasty Front view preop and post op

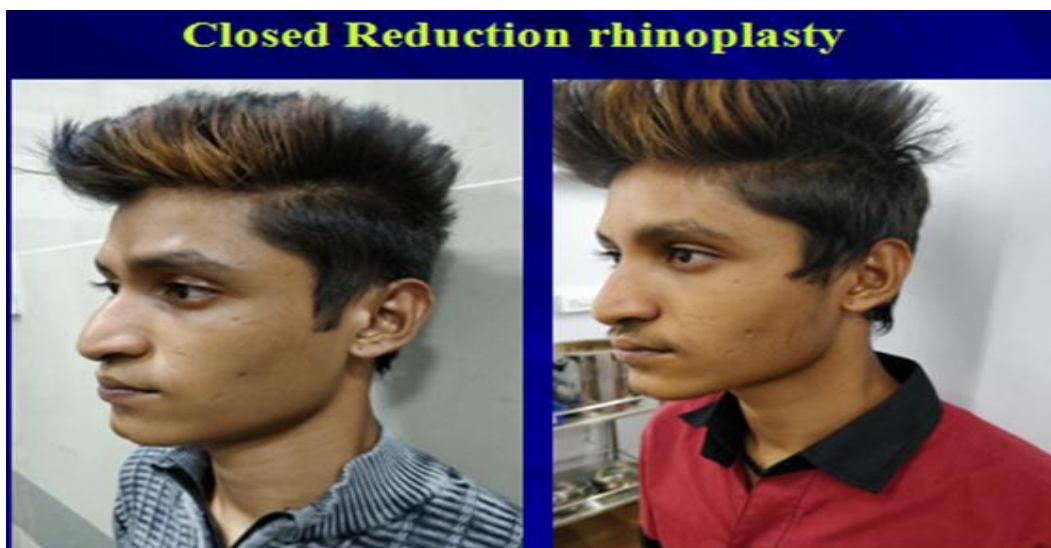
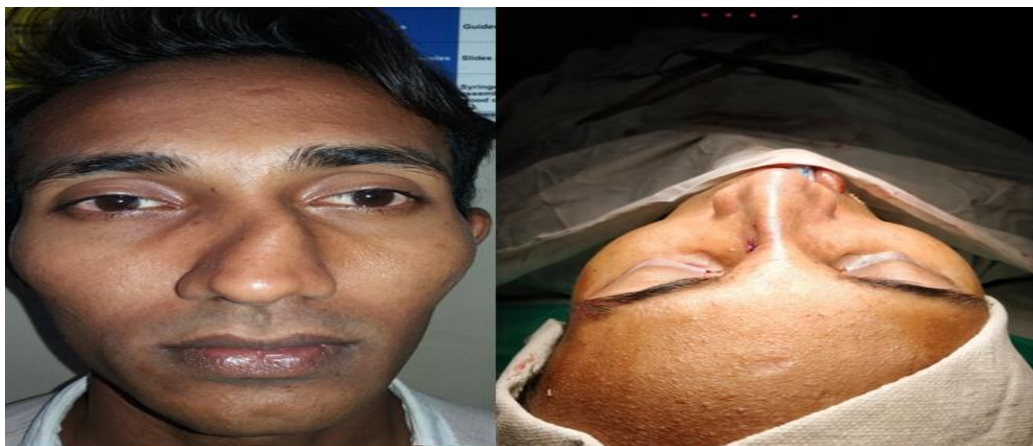
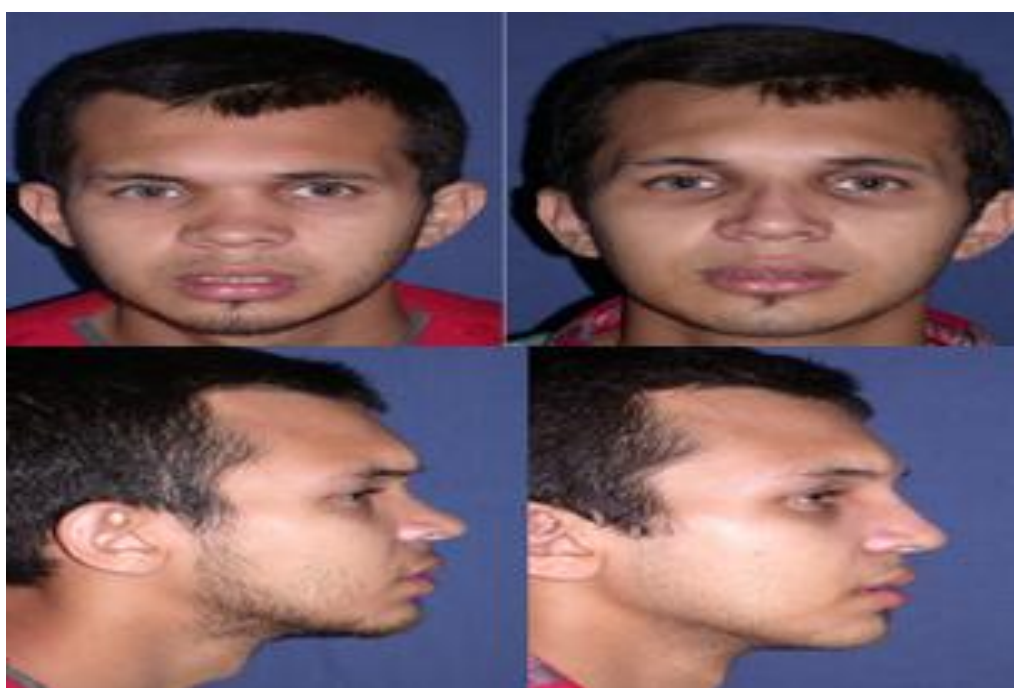Fig. 2: Closed Reduction Rhinoplasty Lateral view preop and post op



**Fig. 3: Closed Reduction Rhinoplasty Preop and Intraop**



**Fig. 4: Osteotomies and Augmentation Rhinoplasty closed approach Front view**

**Conclusion**

In our study we included 55 cases of dorsal nasal deformity for which individualised surgeries were planned according to the deformity and aetiology. Most common aetiology in our study was congenital deformity.

We had 30 males and 25 females. Most of the cases were done with closed approach. Surgical time of average one hour was maintained for all cases. In augmentation rhinoplasty cartilage and silicon implants were used in equal number of cases with no significant difference in outcome or complication rate. Patients who were followed up for 6 months were included in the study and most had satisfactory structural and functional outcome.

Both open and closed approaches are equally promoted by various surgeons. This is more today a surgeon’s preference. Though the point still stands valid that the approach should be decided on the merit of the individual

case. The factors to be considered are aetiology of deformity, previous surgical procedures, preoperative scars, skin type, graft required and the internal nasal anatomy.

Synthetic material offers real advantage in providing plentiful supply quickly and may have place when large defect need to be corrected, but for small to moderate defects cartilage remains best choice.

Most of the cases can be done successfully with closed technique and open technique of rhinoplasty should be preserved for revision cases and gross deformities.

**Financial Support:** None.

**Conflict of Interest:** None.

**References**

1. American Society for Aesthetic Plastic Surgery. 2011 Plastic Surgery Statistics Report. *Am Soc Aesthet Plast Surg* Available at <http://www.plasticsurgery.org/News-and-Resources/2011-Statistics-.html>. Accessed: March 21, 2012.
2. AAFPRS. 2011 AAFPRS Membership Survey. *AAFPRS* Available at [http://www.aafprs.org/media/stats\\_polls/AAFPRS-2012-REPORT.pdf](http://www.aafprs.org/media/stats_polls/AAFPRS-2012-REPORT.pdf). Accessed: March 21, 2012.
3. Powell, N. and Humphreys, B. Proportions of the Aesthetic Face. New York, N.Y.: Thieme-Stratton; 1984.
4. Farkas LG. Linear Proportions in Above- and Below-Average Women's Faces. *Anthropometric Facial Proportions in Medicine*. Springfield: Thomas; 1987. 119-29.

**How to cite this article:** Sathe NU, Narang B, Patil S, Misal P, Rhinoplasty by open or closed approach– Our experience, *J Otorhinolaryngol and Allied Sci* 2019;2(1):16-21