

Evaluation of orthodontic treatment needs in school going children of south western Maharashtra population using aesthetic component of IOTN index

Chaitrali kadu¹, Vinay Umale^{2*}, Pavan Vibhute³, Chetan Patil⁴, Baalagangadhar⁵

¹Student, ^{2,5}Senior Lecturer, ³Professor and HOD, ⁴Reader, Dept. of Orthodontics and Dentofacial Orthopedics, ¹⁻⁵Yogita Dental College and Hospital, Ratnagiri, Maharashtra, India

*Corresponding Author: Vinay Umale

Email: vinayumale15@gmail.com

Abstract

Introduction: The IOTN is simple to use tool, for measuring the orthodontic treatment need and may be adequate for epidemiological purposes and public health planning. Identification of malocclusion in initial stages and immediately starting a simple orthodontic procedure results in prevention of the number of late orthodontic treatments which can be beneficial. The aim of study was evaluation of orthodontic treatment needs in school going children of south western Maharashtra population using aesthetic component of IOTN index

Materials and Methods: The age group selected was 6-12 yrs. with mixed dentition. Examination was done by a single operator by checking the aesthetic view of the samples and comparing them with set of ten colour photographs showing different levels of dental attractiveness i.e. SCAN. The aesthetic view was examined and marked according to the aesthetic view in SCAN Index

Results: Of the studied subjects (400) 103 subjects were having their aesthetic view as type 7 of the scan index which was the highest followed by 58 subjects having their aesthetic view as type 5 of the scan index.

Conclusion: Borderline levels should be lowered. The dividing line between no need of treatment and need for treatment should be distinct. Further studies are required to evaluate if a layman in Khed wants to make a same judgment.

Keywords: Index of orthodontic treatment needs, A Standardized continuum of aesthetic need scale, Malocclusion.

Introduction

As aesthetic and is now the prime concern is the reason for the increasing orthodontic demand day by day. This leads to use of malocclusion indices for prioritizing orthodontic treatment need, many indices have been developed in an attempt to differentiate malocclusion into several groups depending upon the level of the treatment needs. Need to establish an orthodontic treatment in children has increased which can be evaluated using IOTN index. The IOTN is simple to use tool, for measuring the orthodontic treatment need and may be adequate for epidemiological purposes and public health planning. Identification of malocclusion in initial stages and immediately starting a simple orthodontic procedure results in prevention of the number of late orthodontic treatments which can be beneficial.¹

On periodic evaluation of the subjects developing dento-skeletal problems can be detected in early stage, but doctors tends to assess subjects with orthodontic problems only after completion of dental permutation.^{2,3} Because of this doctors refuse to do the interceptive orthodontic procedure which if carried out can prevent the risk of formation of major problems like development of facial

asymmetries or development of class III malocclusion. On the other hand, if the interceptive orthodontic procedures are carried out it can exclude the need for complex, lengthy procedures and provides more stable therapeutic results.^{4,6}

Interceptive orthodontic procedures provide better oral health care with reduced risk of occurrence of dental caries. Orthodontic treatment needs of an individual can be evaluated using IOTN index and accordingly treatment can be carried out.^{7,8}

The Index of Orthodontic Treatment Need (IOTN) was developed by a team in the University of Manchester. The IOTN has two separate components, a clinical component called the Dental Health Component (DHC) and an Aesthetic Component (AC). The DHC assesses the patient's worst feature in their malocclusion. The AC assesses the patient's level of dental attractiveness. The Dental Health Component of IOTN is divided into five grades, with Grade 1 indicating no treatment is required and Grade 5 showing great need for treatment (Brook and Shaw, 1989) [15]. The occlusal trait with the highest score indicates the grade in which the malocclusion belongs to determining the degree of treatment needs.

Table 1

Grade 5 (very great)	<p>Increased overjet > 9 mm</p> <p>Extensive hypodontia with restorative implications (more than one tooth missing in any quadrant) requiring pre-restorative orthodontics.</p> <p>Impeded eruption of teeth (with the exception of third molars) due to crowding, displacement, the presence of supernumerary teeth, retained deciduous teeth and any pathological cause</p> <p>Reverse overjet greater than 3.5mm with reported masticatory and speech difficulties</p> <p>Defects of cleft lip and palate</p> <p>Submerged deciduous teeth</p>
----------------------	--

Grade 4 (great)	<p>Increased overjet > 6 mm but ≤ 9 mm</p> <p>Reverse overjet > 3.5mm with no masticatory or speech difficulties</p> <p>Anterior or posterior crossbites with > 2 mm discrepancy between retruded contact position and intercuspals position</p> <p>Severe displacement of teeth > 4mm</p> <p>Extreme large or anterior open bites > 4 mm</p> <p>Increased and complete overbite with gingival or palatal trauma</p> <p>Less extensive hypodontia requiring pre-restorative orthodontics or orthodontic space closure to obviate the need for prosthesis</p> <p>Posterior lingual crossbite with no functional occlusal contact in one or both buccal segments</p> <p>Reverse overjet greater than 1 mm but ≤ 3.5 mm with recorded masticatory and speech difficulties</p> <p>Partially erupted teeth, tipped and impacted against adjacent teeth</p> <p>Supplemental teeth</p>
Grade 3 (borderline)	<p>Increased overjet >3.5 mm but ≤ 6 mm with incompetent lips</p> <p>Reverse overjet greater than 1 mm but ≤ 3.5 mm</p> <p>Anterior or posterior crossbites with ≤ 1 mm discrepancy between retruded contact position and intercuspals position</p> <p>Displacement of teeth > 2 mm but ≤ 4 mm</p> <p>Lateral or anterior open bite > 1 mm but ≤ 2 mm</p> <p>Increased and complete overbite without gingival or palatal trauma</p>
Grade 2 (little)	<p>Increased overjet > 3.5 mm but ≤ 6 mm with competent lips</p> <p>Reverse overjet > 0 mm but ≤ 1 mm</p> <p>Anterior or posterior crossbites with ≤ 1 mm discrepancy between retruded contact position and intercuspals position</p> <p>Displacement of teeth >1 mm but ≤ 2 mm</p> <p>Anterior or posterior open bite > 1 mm but ≤ 2 mm</p> <p>Increased overbite ≥3.5 mm without gingival contact</p> <p>Prenormal or post normal occlusions with no other anomalies. Includes up to half a unit discrepancy</p>
Grade 1 (none)	Extremely minor malocclusions including displacements < 1 mm

Need for Study

1. As there is lack of awareness about pediatric orthodontic treatments, hence this study highlights the awareness about the same.
2. By this study we can't prevent but we can surely intercept the malocclusion in mixed dentition by assessing the orthodontic treatment needs of an individual.

Aim of the Study

Aim of study was evaluation of orthodontic treatment needs in school going children of south western Maharashtra population using aesthetic component of IOTN index

Objective of the study

1. Early identification of developing malocclusion and initiates simple orthodontic therapy procedures.
2. It represents ways to prevent or reduce the no of late orthodontic treatments which can be lengthy, complex and costly.
3. To help the patients and their parents to grade their own dental esthetics to make the treatment decisions on a more realistic basis.

Methodology

Permission to undertake a survey was obtained and then a study was carried out. The target population for the study consisted of students from primary school of Khed and OPD patients from Yogita dental college and hospital, Khed.

Sample size and selection

The age group for selection was 6-12 yrs with mixed dentition. There was a selection criterion which was to be followed. The inclusion criteria were, Children with mixed dentition. Those children who were not having any history of previous orthodontic treatment were included in the study.

While the exclusion criterion for the study was the subjects with any craniofacial anomalies and those children who did not give informed parents concern.

Method

After all the inclusions and exclusions total 400 subjects were examined (202 boys and 198 girls) Examination was done by a single operator by checking the aesthetic view of the samples and comparing them with set of ten colour photographs showing different levels of dental attractiveness i.e. SCAN -A Standardized Continuum of Aesthetic Need Scale popularly known as "SCAN". Thus,

the aesthetic view was examined and marked according to the aesthetic view in SCAN Index.

1. Results:- Of the studied subjects (400) 103 subjects were having their aesthetic view as type 7 of the scan index which was the highest followed by 58 subjects having their aesthetic view as type 5 of the scan index
2. The detailed results are as follow

Table 2

Types	Boys	Girls	Total
Type 1	9	5	14
Type2	8	9	17
Type3	18	20	38
Type4	12	27	39
Type5	36	20	56
Type6	51	53	104
Type7	25	20	45
Type8	13	15	28
Type9	21	20	41
Type10	9	9	18

Grading Pattern

The grading pattern of the aesthetic index is divided as following

Type-1, Type-2, Type-3, Type-4

= these subjects require no need of treatment

Type 5-type7 = these subjects are inn borderline need of treatment

Type 8-type10 =these subjects are in immediate need of treatment.

Results

When the results of study were distributed according to grading pattern of treatment needs it was found that

Grading Pattern

1. 1-4 No need of treatment
2. 5-7 Borderline
3. 8-10 Immediate Treatment

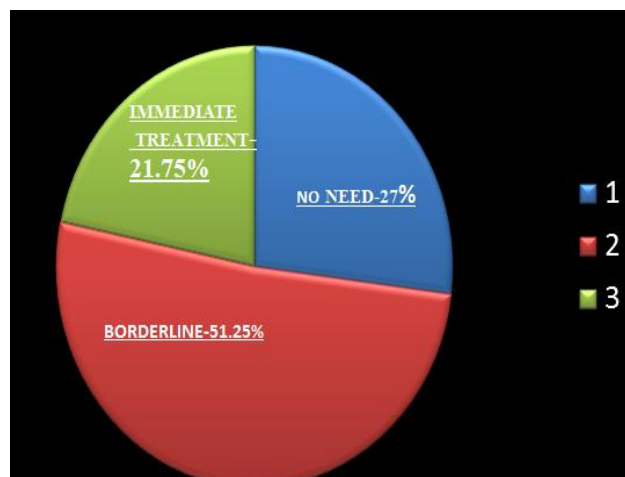


Fig. 2: Distrubtion according to grading pattern

Gender variation in treatment needs

Need of treatment

Borderline

(51.25%)

Boys =54.63%

Girls =45.36%

Immediate

(21.75%)

Boys=49.42%

Girls=50.57%

Discussion

The SCAN scale was created on the basis of intraoral photographs of the dentition of 12-year-old children (Evans and Shaw, 1987). Because of this in the present study, a group of mixed dentition was chosen. On other hand, previous studies carried out using the IOTN have indicated that assigning own dentition to the AC scale is a difficult task, particularly for younger patients (Holmes, 1992). At the stage of mixed dentition the occlusion exhibits some characteristic traits which are reflected in the AC photographs.

The study shows that 73.00% samples need orthodontic treatment while 27% shows no need of orthodontic treatment. But according to study conducted by Tulika Wakhloo in Marathahalli, Bangalore 29.29% shows need for orthodontic treatment while 70.71% shows no need of orthodontic treatment. Comparatively, Nigerian (9%), Western Saharan (13.3%) & Tanzanian (13.8%) children had much lower orthodontic treatment need.

Conclusion

1. Borderline levels should be lowered.
2. The dividing line between no need of treatment and need for treatment should be distinct
3. Further studies are required to evaluate if a layman in Khed wants to make a same judgment.

Even though, the Index of Orthodontic Treatment Need may not be an ideal one, but this index could be considered as good malocclusion index, since it fulfils some of criteria of good index as stated by Young and Striffler. The examination only takes less than one minute if the malocclusion is not too complicated.

Conflict of Interest: None.

References

1. Assessment of Orthodontic Treatment Need in Mixed Dentition Period (11-12 Years) Among School Children in Marathahalli, Bangalore Tulika Wakhloo Department of Pedodontics and Preventive Dentistry, Dr. Syamala Reddy Dental College Hospital and Research Centre, Bangalore, Karnataka, India
2. Proffit, W., Fields, H.W., Sarver, D.M. Contemporary Orthodontics 5th Edition. Elsevier 2013 2-15, 46-50, 73-90, 133-145, 403-442.
3. Vig KWL, Fields HW. Facial growth and management of orthodontic problems. *Pediatr Clin North Am* 2000;47(5):1085-1123.

4. Seehra J, Newton JT, Dibiasi AT. Interceptive orthodontic treatment in bullied adolescents and its impact on self-esteem and oral-health-related quality of life. *Eur J Orthod* 2013;35(5):615-621.
5. Keski-Nisula K, Hernesniemi R, Heiskanen M, Keski-Nisula L, Varrelä J. Orthodontic intervention in the early mixed dentition: a prospective, controlled study on the effects of the eruption guidance appliance. *Am J Orthod Dentofacial Orthop* 2008;133(2):254-260.
6. Tulloch JF, Phillips C, Koch G, Proffit WR. The effect of early intervention on skeletal pattern in Class II malocclusion: a randomized clinical trial. *Am J Orthod Dentofacial Orthop* 1997;111(4):391-400.
7. Kerosuo H. The role of prevention and simple interceptive measures in reducing the need for orthodontic treatment. *Med Princ Pract* 2002;11(1):16-21.
8. King G.J. and Brudvik P. Effectiveness of interceptive orthodontic treatment in reducing malocclusions. *Am J Orthod Dentofacial Orthop* 2010;137(1):18- 25.
9. Hassan R and Rahiman AK. Occlusion, malocclusion and method of measurements – an overview. *Arch Orofac Sci* 2007;2:3-9.
10. Kharbanda OP. Orthodontics: Diagnosis and management of malocclusion and dentofacial deformities. Elsevier Publishers
11. Assessment of orthodontic treatment need in 11- to 20-year-old urban Iranian children using the Dental Aesthetic Index (DAI) Article in World journal of orthodontics · December 2010
12. Jenny J, Cons NC. Establishing malocclusion severity levels on the Dental Aesthetic Index (DAI) scale. *Aust Dent J* 1996;41:43–46.
13. Evaluation of the aesthetic component of the IOTN index by Swedish orthodontics . Anneli m.Johansson and Marie.e.Follin, Department of orthodontics and faculty of odontology, goteborg university sweden.

How to cite this article: kadu C, Umale V, Vibhute P, Patil C, Baalagangadhar, Evaluation of orthodontic treatment needs in school going children of south western Maharashtra population using aesthetic component of iotn index. *J Orthod Dentofacial Res* 2019;5(1):28-31