

Early orthognathic approach combined with SABG for congenital dentofacial deformity-A rare case report

Shruthi Pradeep¹, Saloni Garg², Ratna Parameswaran³, R. Devaki Vijayalakshmi^{4,*}, Sanjay Sundararajan⁵

^{1,5}Post Graduate, ²Private Practitioner, ³Professor, ⁴Professor and HOD, ^{1,3-5}Dept. of Orthodontics and Dentofacial Orthopedics, ^{1,3-5}Meenakshi Ammal Dental College, Maduravoyal, Tamil Nadu, India

Corresponding Author: R. Devaki Vijayalakshmi

Email: devasara17@yahoo.co.in

Abstract

Patients with dentofacial deformities form an important part of the society and present with physical and psychological issues due to their appearance. The rehabilitation of such patients requires a surgical intervention which can be tremendously volatile due to several factors amongst which residual growth is considered to be the most imperative. In this report, a case of a 14 year old male patient with a class III skeletal base and cleft lip and palate is presented. Growth Treatment Response Vector (GTRV) cephalometric analysis is used to predict the mandibular growth vector thereby giving an insight into whether an early orthognathic surgical intervention for the early rehabilitation of this patient can be considered and whether future surgeries post growth can be eliminated. Pre-surgical orthodontics involved levelling and aligning followed by SABG in the cleft region which allowed the normal eruption of impacted canine. Surgically maxillary advancement of 6mm with an anterior pitch down of 4mm, and advancement genioplasty of 6mm was done to achieve an orthognathic profile. Postsurgical settling was done, and the case was finished in skeletal Class I, functional molar and canine relationship with ideal overjet and over bite.

Keywords: Early orthognathic surgery, Dentofacial abnormalities, Cleft lip and palate.

Introduction

The congenital dentofacial deformities traditionally manifest along with the incoordination of skeletal jaw bases. The management of congenital dentofacial deformities involves prolonged periods of treatment usually spanning about the first three decades of life. Certain factors as the age, residual skeletal growth, the response of the skeletal and associated structures to surgery need consideration which lengthens treatment periods of these patients.¹

The cleft lip and palate is one such congenital dentofacial anomaly which is often associated with a hypoplastic maxilla. A differential growth exists between the jaw bases in cleft lip and palate patients because of the underdeveloped maxilla and a normal growing mandible resulting in class III skeletal base in these patients.² The treatment option often remains complicated with surgery being the primary choice. There exists a certain perplexity involving the surgical correction and growth remnants in mandible that has further implications of the timing of the surgery. This delay in the timing of surgery causes a lowered self-esteem and difficulties in social interaction and negative psychosocial issues.³

There exists a requirement of an approach that is showcased in this case report which highlights the treatment results of early orthognathic surgery in a patient with cleft lip and palate is presented. A proper understanding of normal growth and accurate diagnosis and treatment planning can warrant an early correction of severe skeletal deformities with shorter treatment time by eliminating the orthopedic phase and by enhancing the healing potential.

Case Report

A 14 year old male patient reported to the Department of Orthodontics with the chief complaint of irregularly placed upper front teeth due to cleft lip and palate. Medical

history revealed that the patient had undergone cleft lip repair surgery at 4 months and palatoplasty at 8 months of age. Lip scar revision was performed at the age of 7 years and the patient also underwent speech therapy for one year. Patient's parent revealed no relevant family history.

General examination indicated a mesocephalic head type, mesomorphic body type and mesoprosopic facial pattern. The patient was found to be moderately built. Extra oral examination revealed a straight profile with straight divergence, obtuse Nasolabial angle and high clinical FMA. The facial midline was not coincident with the dental midline. Nasal deformity was seen with deviated nasal septum and asymmetric alar basal width. A mild chin shift towards the left was observed with asymmetric lower third of the face. The patient had competent lips with asymmetric lip contour. A Scar was seen on upper left lip with lip drag upwards towards the left suggestive of cleft repair surgery on left upper lip. Smile analysis displayed no upper incisor visibility and increased lower incisor visibility (Fig. 1.A, B, C, D)

Functional examination revealed clinically asymptomatic TMJ, normal speech, breathing and swallow pattern. The Oral hygiene was found to be Satisfactory with normal tongue, oral and buccal mucosa. Intraoral hard tissue examination revealed retroclined upper anterior teeth, proclined lower anterior teeth with missing 12, 22. Due to the presence of cleft, the maxilla was found to be underdeveloped on the left side. Class I molar and canine relationship was found on the right side. The molar and canine relation on the left side could not be defined as proper occlusion was not established due to the underdevelopment of the alveolar ridges. Edge to edge incisor relation was seen with 0mm overjet and overbite. (Fig. 2.A, B, C, D, E)

On cephalometric evaluation, skeletal Class III skeletal base was evident with retrognathic maxilla and retrognathic mandible due to high mandibular plane angle with an average growth pattern (Fig.3.A). Orthopantomogram revealed alveolar bone defect in the left upper segment, missing 12, 22, impacted 13 and tooth buds of 18, 28, 38 and 48 (Fig. 3.B).

The growth prediction, which is the key to analyze the timing of surgical intervention, is done using the Growth Treatment Response Vector (GTRV) analysis by Peter Ngan in 2005⁴. A series of lateral cephalometric superimposition is done using the phase I post treatment cephalogram and the follow up cephalograms of 4 years which enables to decide whether a surgical intervention could be feasible by predicting the growth vector prognosis. The GTRV values for class III patients between 0.33-0.88 suggest that the case can be managed by camouflage treatment. However, for this patient, the GTRV was found to be 1.25 which suggested that the growth trend was favourable towards surgical intervention with no or minimal growth left in the mandible.

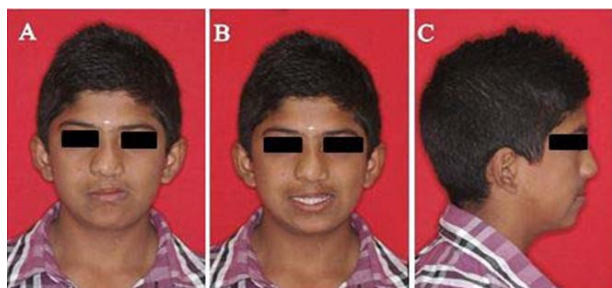


Fig. 1: Pre-treatment extra-oral photographs

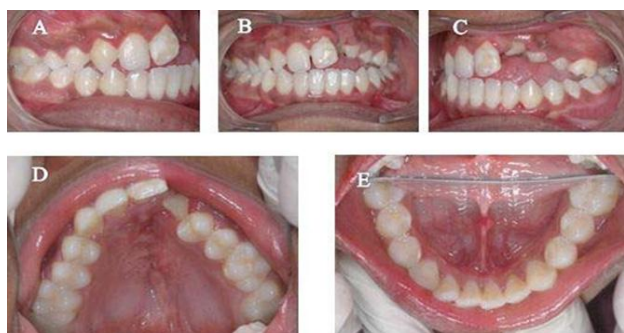


Fig 2: Pre-treatment intra-oral photographs

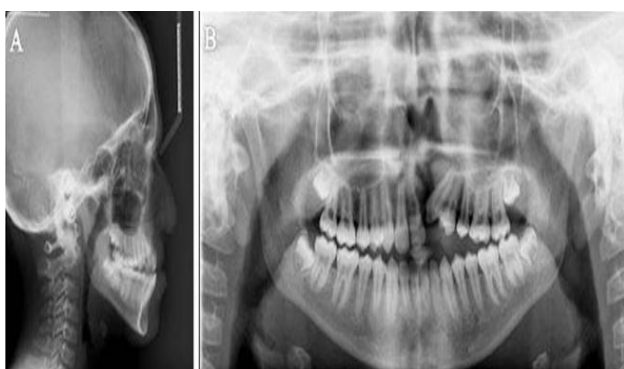


Fig 3: Pre-treatment radiographs

Treatment Objectives

- To achieve ideal soft tissue profile and balance
- To achieve ideal skeletal base
- To correct the nose chin asymmetry
- To correct dento-alveolar cant in the maxilla
- To align upper and lower arch
- To achieve ideal overbite and overjet
- To achieve functional molar and class I canine relationship bilaterally.

Accurate diagnosis, proper treatment planning, and appropriate age sequencing of procedures were crucial in this case as the maxillary growth was not complete. Due to cleft, normal growth of the maxilla could not be expected whereas normal mandibular growth would continue which would further aggravate the discrepancy between the skeletal jaw bases. An early surgical intervention was to be considered as significant functional, esthetic, and psychosocial issues need to be resolved. Delaying the treatment until adulthood could aggravate the existing problems.^{2,5}

Treatment Plan

Pre – surgical orthodontics:
 Secondary alveolar bone grafting – 22-23region
 Leveling and aligning to correct alveolar canting on left side and cross bite correction
 Surgical plan -Maxillary advancement of 6mm with an anterior pitch down of 4mm and Advancement genioplasty of 6mm
 Post-surgical: settling
 Mechanotherapy: 0.022 MBT PEA

Treatment

Pre-surgical phase was commenced by proclining and aligning the upper anterior teeth. The teeth were bonded with 0.022 MBT bracket systems. Segmental bonding was performed excluding 21 as there was deficient bone uprighting the teeth in left upper quadrant. Secondary Alveolar Bone Grafting (SABG) was done in 22-23 region which allowed root uprighting and alignment of 21 and allowed normal eruption of the impacted canine (Fig. 4).

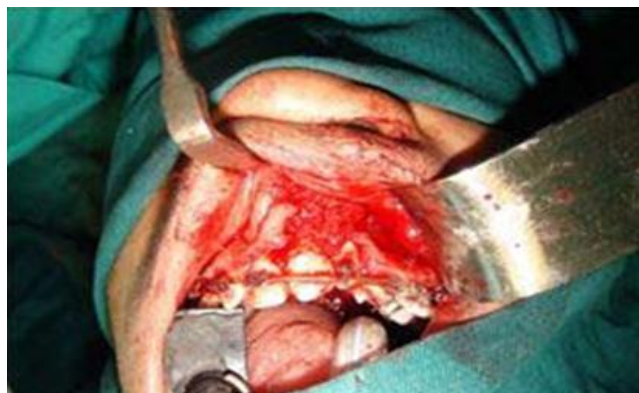

Fig 4: SABG

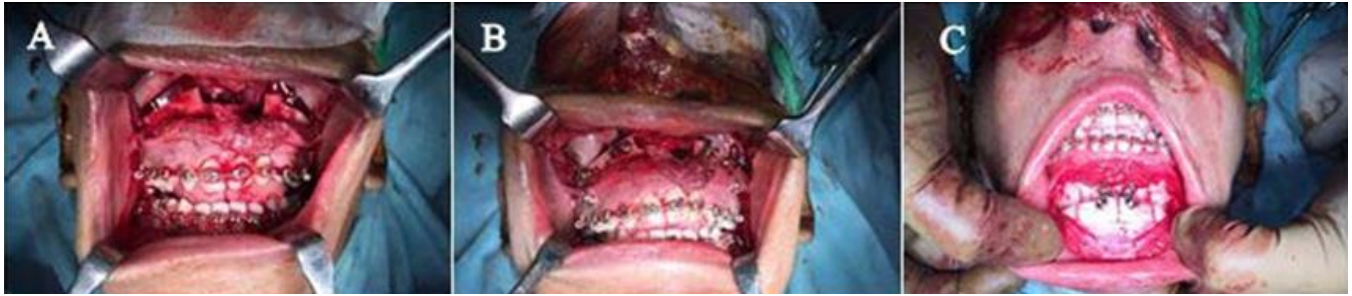

Fig 5: Surgery

Leveling and aligning phase lasted for 8 months. 0.016 Nickel titanium (Ni-Ti) archwires were placed followed by 0.016 x 0.022 Ni- Ti, 0.017 x 0.025 Ni-Ti, and 0.019 x 0.025 Ni-Ti which sequentially leveled and aligned the dental arches. The GTRV analysis (calculated value - 1.25) revealed that the mandibular growth was predictably favourable and prognosis was positive. However a surgical intervention was indicated in the maxilla in order to correct the skeletal deformity. Accordingly STO, mock surgery was done during which surgical splint was prepared and the patient was posted for surgery. Surgically maxillary advancement of 6mm with an anterior pitch down of 4mm, and an advancement genioplasty of 6mm were done to achieve an orthognathic profile (Fig. 5.A, B, C). Post-surgical settling was done.

Results

A substantial enhancement in the patient’s profile was seen as the skeletal base was ideal. An ideal smile line with proper upper incisor display was achieved which gave the patient a more youthful and attractive personality. In response to the hard tissue structures, the soft tissue profile of the patient was also found to be highly satisfactory except for the nasal deformity (Fig 6.A, B, C, D). The occlusion was finished with Class I skeletal base, molar and canine in functional relationship and with ideal overjet, overbite, coincident midlines and proper occlusion was achieved(Fig. 7 A,B,C,D,E). Rhinoplasty procedure was advised as an adjunct surgical approach after the completion of growth.

Post debonding, the patient was delivered upper and lower thermoplastic retainers with attachment for class III elastic wear (Fig. 8 A, B, C) (Table 1).

The entire treatment period lasted for 20 months. One Year follow up showed stable results and maintenance of the improved soft tissue profile (Fig. 9 A, B).

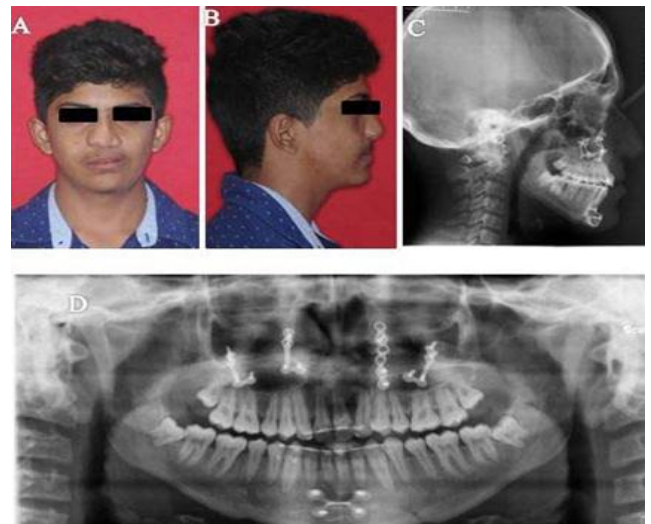

Fig 6: Post Treatment Extra-oral photographs and radiographs

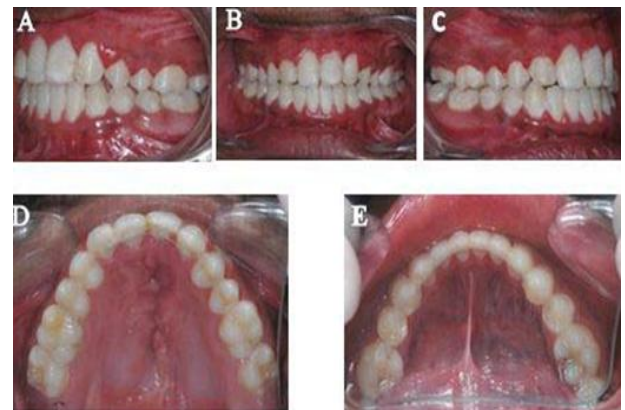


Fig 7: Post treatment intra- oral photographs

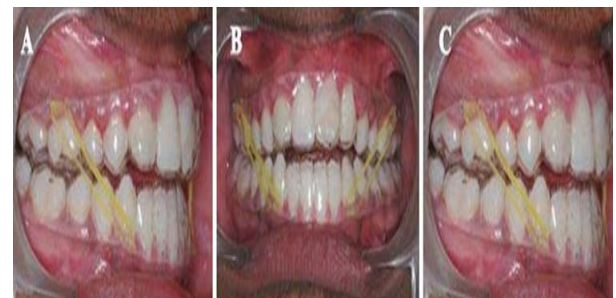
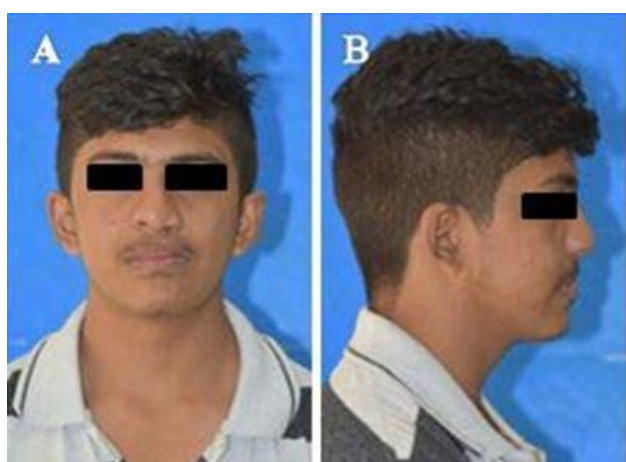
Fig 8: Retention

Table 1: Comparison of cephalometric values at different stages of treatment

	Normal	Pre -Treatment	Pre -Surgical	Post-Treatment
SNA	82 ⁰	77 ⁰	76 ⁰	80 ⁰
SNB	78 ⁰	78 ⁰	78 ⁰	78 ⁰
ANB	2 ⁰	-1 ⁰	-2 ⁰	2 ⁰
1 to NA	4mm/22 ⁰	2mm/17 ⁰	2mm/18 ⁰	3mm/19 ⁰
1 to NB	4mm/25	8mm/27	8mm/27	7mm/25 ⁰
Interincisal Angle	131 ⁰	136 ⁰	135 ⁰	132 ⁰
1 to A PoG	1mm±2	2mm	3mm	0mm
FMA	25 ⁰	30 ⁰	30 ⁰	29 ⁰
N to PT A	0±2mm	-4mm	-5mm	3mm
N to PoG	0-4mm	-9mm	-11mm	-3mm
6 to PtV	14mm	15mm	15mm	19mm
Go-Me	71±5mm	65mm	69mm	71mm
Go-Pg	68.5-80.1	66mm	70mm	72mm

**Fig 9: Follow up**

Discussion

Research studies have shown that a psychosocial impairment has been found in individuals with cleft lip and palate and early orthognathic surgery usually results in increased self-esteem, self-confidence and satisfaction with appearance and is indicated if significant functional, esthetic, and psychosocial impairments exist. The absence of TMJ pathosis also favors the surgical intervention. In contrary an early orthognathic surgery has its own demerits which include; (1) the surgical procedure may adversely affect the subsequent growth⁶ and (2) facial growth may continue postoperatively compromising the benefits of surgery performed.⁷

While intervening with early orthognathic surgery, a clear understanding of the normal growth is very important. Normal transverse growth is completed first followed by horizontal growth and vertical growth. 98% of facial growth is usually complete in girls by age 15 and in boys by age 17 or 18. On average, growth spurt peaks in girls at age 12 years and in boys at age 14 years.

Wolford states that maxillary hypoplasia during growth will result in recurrence of the Class III skeletal relationship as the mandible continues to grow normally.³ The mandibular growth in class III patients became more

predictable with the Growth treatment response vector analysis proposed by Peter Ngan⁴. A GTRV analysis is performed during the early permanent dentition and it allows clinicians to decide whether the malocclusion can be camouflaged by orthodontic treatment or whether a surgical intervention would be required when growth was complete. When maxillary advancement surgery is indicated as an early intervention, GTRV helps in assessing the prognosis of further mandibular growth offering insight whether second surgery would be necessary.

The GTRV ratio for a patient with normal growth pattern was found to be 0.77. In class III patients, with maxillary deficiency and GTRV ratio between 0.33 and 0.88 can be successfully camouflaged with orthodontic treatment. Class III patients with excessive mandibular growth together with a GTRV ratio that falls below 0.38 is usually in need of a future orthognathic surgery. In the present case the GTRV was calculated as 1.25 which revealed that the mandibular growth was favourable and a future mandibular surgery would not be required.

Secondary alveolar bone grafting (SABG) is an integral approach in the management of cleft lip and palate. The bone defect due to cleft had destabilised the maxillary arch and had prevented the normal eruption of the canine. SABG provided a matrix for continued eruption of the impacted canine thereby bringing it into occlusion. The iliac crest was chosen to be the SABG donor site as iliac crest has sufficient cancellous bone to fill even a large alveolar bone defect.

Maxillary hypoplasia is rectified with the le fort I osteotomy. Even though the sagittal growth does not continue following the surgical procedure, vertical growth continues and usually remains unaltered. While treating class III cases, care is taken to overcorrect the maxilla in order to compensate for the remaining mandibular growth. Another concern during this procedure is the damage to developing tooth roots which may result in ankylosis and localized growth impairment. Following the STO and considering the pros and cons of Le Fort I osteotomy, maxillary advancement of 6mm with an anterior pitch down of 4mm corrected the hypoplasia and the anterior pitch

down proved to be favorable in increasing the upper incisor exposure thereby refining the smile of the patient.

An advancement genioplasty or functional genioplasty as said by Precious and Delaire was also performed since it provided a beneficial change in lip function and would also help obtain lip competency at repose.⁸ The upward and forward repositioning of the chin would increase symphysis thickness, enhance bone apposition at B point, and causes remodelling at the inferior border.⁹ Advancement genioplasty of 6mm thereby masked the retrognathic profile of the patient due to downward rotating mandible.

Conclusion

Surgical procedures in growing patients remain one of the most debatable topics in orthodontics. Along with the treatment outcome, multiple factors like risks, complications of surgery during the growth period, residual growth left in the patient and the severity of the skeletal deformity must be kept in mind and careful assessment of each patient must be done in order to provide the best of treatment results. Early orthognathic surgery when performed after a GTRV analysis helps analyze the growth vectors of the jaw bases, thereby reducing the need for a future surgical intervention.

Conflict of Interest: None.

References

1. Weaver N, Glover K, Major P, Varnhagen C, Grace M. Age limitation on provision of orthopaedic therapy and

- orthognathic surgery." *Am J Orthod Dentofacial Orthop* 1998;113:156-164
2. Wolford LM, Karras SC, Mehra P. "Considerations for orthognathic surgery during growth, part 2: maxillary deformities." *Am J Orthod Dentofacial Orthop* 2001;119(2):102-105.
3. Sousa AD, Devare S, Ghanshani J. "Psychological issues in cleft lip and cleft palate". *J Indian Assoc Pediatr Surg* 2009; 14(2):55-58.
4. Ngan P. "Early timely treatment of Class III malocclusion". *Semin Orthod* 2005;11:140-145
5. Alwadei S. "Early Orthognathic Surgery: A Review". *J Contemp Dent Pract* 2017;1;18(3):250-256.
6. McCarthy JG, La Trenta GS, Breitbart AS, Grayson BH, Bookstein FL. "The Le Fort III advancement osteotomy in the child under 7 years of age". *Plast Reconstr Surg* 1990;86(4):633-646
7. Snow MD, Turvey TA, Walker D, Proffit WR. "Surgical mandibular advancement in adolescents: postsurgical growth related to stability". *Int J Adult Orthodon Orthognath Surg* 1991;6(3):143-151.
8. Precious DS, Delaire J. "Correction of anterior mandibular vertical excess: the functional genioplasty". *Oral Surg Oral Med Oral Pathol* 1985;59:229-235.
9. Chamberland S, Proffit WR, Chamberland PE. "Functional genioplasty in growing patients". *Angle Orthod* 2015; 85(3):360-373.

How to cite this article: Pradeep S, Garg S, Parameswaran R, Vijayalakshmi RD, Sundararajan S, Early orthognathic approach combined with SABG for congenital dentofacial deformity - A rare case report. *Indian J Orthod Dentofacial Res* 2019;5(1):32-36