

A rare case of oropharyngeal angiomyolipoma

Kanica Chaudhary^{1,*}, Veena Ramaswamy², Kinjal Majumdar³, Rachana Prasad⁴, Vishal Rao⁵

¹DNB Resident, ^{2,5}Consultant, ^{3,4}Fellow, ^{1,2}Dept. of Pathology, ³⁻⁵Dept. of Head and Neck Surgery, HCG Hospital, Bengaluru, Karnataka, India

*Corresponding Author: Kanica Chaudhary

Email: drkanicachaudhary@gmail.com

Received: 18th June, 2018

Accepted: 23rd July, 2018

Abstract

The authors here present a rare case of angiomyolipoma arising in the oropharynx. The tumor was found in a 55-year-old man, not associated with tuberous sclerosis. Histopathologic examination of the tumor revealed an admixture of numerous smooth muscle cells, mature adipose tissue and numerous thin-walled capillaries and thick-walled vessels. Both histological and immunohistochemical findings were typical for tumors of the mucocutaneous angiomyolipoma group.

Keywords: Angiomyolipoma, Oropharynx, Tumor, Excision, Lateral pharyngotomy.

Introduction

Angiomyolipoma (AML) is a benign mesenchymal neoplasm composed of fat, vascular, and smooth muscle elements. This tumor most commonly arises from the kidney, followed by the liver.^{1,2,4,8} In the head and neck region, AML has frequently been reported to be located in the oral cavity, nasal cavity and nasopharynx.¹⁻³ Accompanying tuberous sclerosis syndrome is present in 50% of angiomyolipoma patients; whereas AML has been reported in 80% of tuberous sclerosis patients.⁴ There are only a few laryngeal AML cases available in the literature.⁵⁻⁷

Case Report

We herein report a case of a 55-year old male who presented to our outpatient department with complaint of discomfort in throat since 2 years. No history of difficulty in swallowing or breathing was present. There was no change in voice too. On videolaryngoscopic examination, a globular, smooth surfaced, polypoid mass was seen arising from left pharyngeal wall just below the lower pole of tonsil, encroaching into the left vallecula compressing the epiglottis to right [Fig. 1].

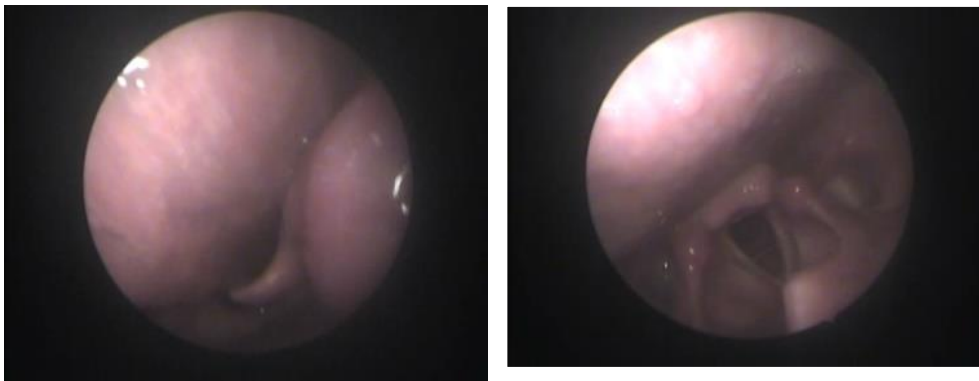


Fig. 1: Videolaryngoscopic images showing a smooth surfaced globular mass arising from left lateral pharyngeal wall encroaching left vallecula compressing the epiglottis to the opposite side. Laryngeal inlet was normal with mobile vocal cords

Magnetic resonance imaging with angiogram (MRA) showed a well-defined, isointense in T1 & hyperintense in T2 weighted images, homogeneously enhancing lesion in left tonsillar fossa measuring 4.0 x 2.3 x 2.9 cm, compressing epiglottis to right, receiving arterial feeders directly from external carotid artery & ascending pharyngeal artery [Fig. 2]. Fine needle aspiration cytology (FNAC)

revealed blood aspirate, suggestive of vascular lesion. Owing to the vascularity of the tumors, pre-operative embolization followed by surgical excision was planned. Carotid angiogram showed a branch from left lingual artery feeding the epiglottic lesion with significant vascularity and contrast blush; but due to small calibre and tortuosity, the artery could not be catheterised using 2.7 Fr Progreat microcatheter.

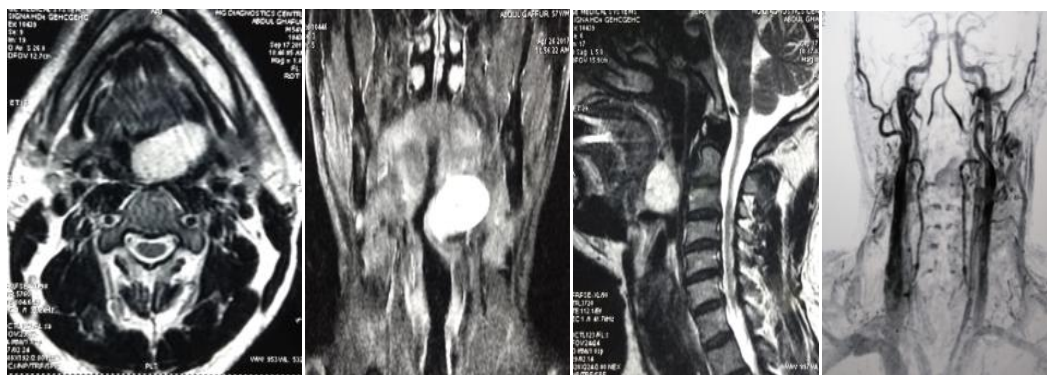

Fig. 2: Magnetic resonance imaging with angiogram showing a well-defined, homogeneously enhancing lesion in left pharyngeal wall

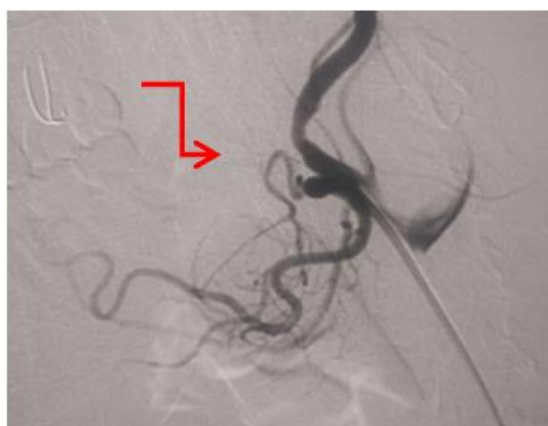

Fig. 3: Carotid angiogram showing feeder vessel (Red arrow) to be a branch from the lingual artery

Intra-operative microlaryngoscopy showed two separate vascular masses with sessile base arising from the left lateral pharyngeal wall obscuring the left vallecula and from the epiglottis. But microlaryngoscopic excision was abandoned due to failed pre-operative embolisation, need of ligation of the feeder vessel prior to excision and inadequate exposure. The tumors were excised by left lateral pharyngotomy approach with prior ligation of the left lingual artery.

Grossly, the masses appeared circumscribed and globular. Routine microscopic examination of the vallecular lesion revealed a well circumscribed lesion formed of irregular thick walled arteries with a few thin -walled capillaries and venules [Fig. 4]. Some of these vessels appear as slit like spaces and some as cavernous spaces. The stroma in between was composed of smooth muscle bundles and lobules of mature adipocytes. Lymphocytic infiltration of the stroma was noted.

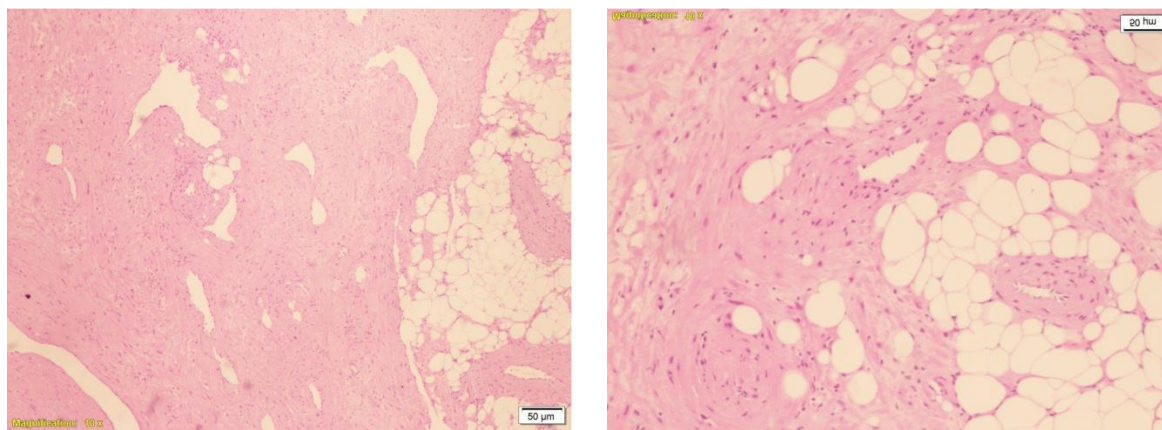


Fig. 4: Histopathology images showing presence of mature adipose tissue, smooth muscle fibres and thick-walled, irregular blood vessels pathognomonic of angiomyolipoma

The epiglottic lesion showed a vascular lesion composed of interconnecting venules and arterioles of varying sizes. Predominant areas showing thrombosed and congested blood vessels, haemorrhage and fibro-intimal thickening in the venules were noted amidst an oedematous stroma. The epiglottic lesion was an Arterio-Venous malformation composed of malformed vessels with abrupt changes in their medial and elastic walls [Fig. 5]. No evidence of dysplasia or malignancy was seen in either of the lesions.

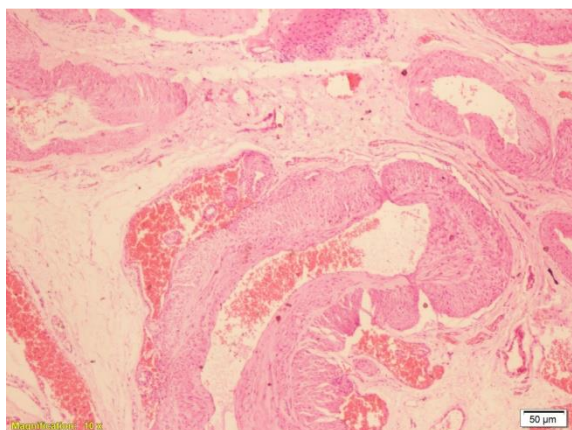


Fig. 5: Epiglottic lesion showing an admixture of malformed arteries, capillaries and venules with abnormal vascular dilatation

Immunohistochemistry done on the vallecular lesion showed positive expression for Smooth muscle actin (SMA) and Desmin by the smooth muscle component of the lesion; CD34 was expressed by the vascular endothelial cells. Immunostaining for melanocytic markers like HMB-45 and Melan-A- which signify a renal angiomyolipoma – was negative. Morphologic and immunohistochemical findings were concordant for the diagnosis of an angiomyolipoma of the vallecula.

Successive ultrasound of abdomen revealed no synchronous lesion in kidney or liver. And presence of tuberous sclerosis was also ruled out through multidisciplinary team approach.

Discussion

Angiomyolipoma (AML) is a hamartoma consisting of varying amount of mature adipose tissue, smooth muscle fibres and thick walled blood vessels, seen more commonly in females. The commonest form of AML is renal AML, which usually remains asymptomatic and is diagnosed incidentally. While 50% of renal AML is associated with tuberous sclerosis complex, extra-renal AML is sporadic.¹⁰

Of all the AML arising from sites other than kidney and liver, the most commonly found are those on the skin. Skin AML has been described on the penis, head and neck, and limbs. Histopathologically, skin and nasal AML are identical, as are the oral cavity and pharyngeal types. Watanabe & Suzuki⁸ proposed a joint denomination of mucocutaneous AML for this second group of tumors.

Mucocutaneous AML are different from hepato-renal AML in many ways. Firstly, they are not associated with tuberous sclerosis complex, they usually affect older men and are usually small. Secondly, the most striking difference is that the nasal cavity and skin AML are composed of mature smooth muscle cells only, which are negative to the HMB-45 melanoma-specific antigen, contrary to those which are not mucocutaneous. There were no additional features in the present case too suggestive of tuberous sclerosis,⁸ as in other mucocutaneous AMLs described in literature till date.

Endoscopic preoperative histopathological diagnosis is difficult due to the vascularity and submucosal development of the tumor, as found in this case too. Other tumors of adipose tissue (angioliipoma, liposarcoma) and angioleiomyoma should initially be taken into consideration in the microscopic differential diagnosis. Angioliipoma lacks myoid differentiation. Lipoid component does not exist in an angioleiomyoma. In order not to misdiagnose a liposarcoma, lipoid component must be searched carefully for lipoblasts. Melanocytic marker (HMB-45) positivity is constitutional for AML.⁸ However, HMB-45 positivity was never observed in any of the cases of mucocutaneous AML mentioned in the literature. The presence of adipose tissue, smooth muscle fibres and tortoise vessels allowed us to make the diagnosis of angiomyolipoma easily in the present case, so an IHC examination was not requested.

Although renal AML may show peri-renal fat involvement and clinically behave in a malignant fashion in case of epithelioid AML, classic AML is regarded as benign.¹¹ There is need of further investigation for clinicopathological characteristics of extrarenal AML, but extrarenal AML is also considered as benign. Surgical excision is considered curative. While small lesions may be excised through endolaryngeal microsurgery, an external approach (laryngofissure, lateral pharyngotomy, or thyrotomy) may be used for large lesions.¹² In the present case, due to inadequate access through microlaryngoscopy, surgical excision was performed through external (lateral pharyngotomy) approach with prior ligation of the feeder (lingual artery) vessel through the same neck incision after a failed attempt of pre-operative embolisation.

Conclusion

AML is a very rare tumor in the oropharynx. Only few rare cases have been reported till date from pharynx (base of tongue). Other areas in head and neck region described, are oral cavity, nasal cavity and larynx. The non-association of this particular AML with Tuberous Sclerosis has to be highlighted as well. Although there is need of further investigation on clinicopathological characteristics of mucocutaneous AML including their ability for malignant transformation, if present, the present case will certainly contribute to the analysis of these extremely rare hamartomatous lesions.

Conflict of Interest: None.

References

1. A. Piattelli, M. Fioroni, C. Rubini, E. Fiera. Angiomyolipoma of the palate. Report of a case. *Oral Oncol* 2001;37(3):323-325.
2. K. Yamamoto, H. Nakamine, T. Osaki, Angiomyolipoma of the oral cavity: report of two cases. *J Oral Maxillofac Surg* 1995;53(4):459-461.
3. F. Ide, T. Shimoyama, N. Horie. Angiomyolipomatous hamartoma of the tongue. *Oral Surg, Oral Med, Oral Pathol Oral Radiol Endod* 1998;85(5):581-584.
4. M. Ito, Y. Sugamura, H. Ikari, and I. Sekine. Angiomyolipoma of the lung. *Arch Pathol Lab Med*, 1998;122(11):1023-1025.
5. D. Stodulski, C. Stankiewicz, R. Rzepko, B. Kowalska. Angiomyolipoma of the larynx: case report. *Eur Arch Oto-Rhino-Laryngol*, 2007;264(1):89-92.
6. Y. Durgun, C. Firat, M. C. Miman, and H. Kirimlioglu. A rare benign laryngeal tumor: angiomyolipoma. *J Craniofac Surg* 2010;21(6):1956-1957.
7. A. Bandhlish, E. Leon Barnes, J. T. Rabban, and J. B. McHugh, "Perivascular epithelioid cell tumors (PEComas) of the head and neck: report of three cases and review of the literature," *Head Neck Pathol* 2011;5(3):233-240.
8. K. Watanabe and T. Suzuki. Mucocutaneous angiomyolipoma: a report of 2 cases arising in the nasal cavity. *Arch Pathol Lab Med* 1999;123(9):789-792.
9. C. A. Tseng, Y. S. Pan, Y. C. Su, D. C. Wu, C. M. Jan, and W. M. Wang. Extrarenal retroperitoneal angiomyolipoma: case report and review of the literature. *Abdom Imaging* 2004;29(6):721-723.
10. Northrup H, Krueger DA, on behalf of the International Tuberous Sclerosis Complex Consensus Group. Tuberous Sclerosis Complex Diagnostic Criteria Update: Recommendations of the 2012 International Tuberous Sclerosis Complex Consensus Conference. *Pediatr Neurol* 2013;49(4):243-254.
11. Bostwick DG, Cheng L. *Urologic Surgical Pathology*, 2nd edn. Philadelphia: Mosby, 2008.
12. D. Mysiorek, D. Madnani, and M. D. Delacure, "The external approach for submucosal lesions of the larynx," *Otolaryngol—Head Neck Surg*, 2001;125(4):370-373.

How to cite this article: Chaudhary K, Ramaswamy V, Majumdar K, Prasad R, Rao V. A rare case of oropharyngeal angiomyolipoma. *Indian J Pathol Oncol* 2019;6(1):151-154.