

Post-traumatic Pseudolipoma of right side of the chest and axilla: A case report and review of literature

Dost Mohamed Khan M^{1,*}, Deepa N.²

¹Associate Professor, Dept. of Pathology, ²Associate Professor, Dept. of Surgery, Shri Sathya Sai Medical College, Nillikuppam Tamilnadu

***Corresponding Author:**

Email: dostmk@gmail.com

Abstract

Lipomas are mesenchymal neoplasms that can develop in all parts of the body which accounts for almost 50% of all soft-tissue tumours. We present a case, 40 year old male presenting with a large mass in the right axilla and right side of the chest wall following a blunt injury for 10 years duration. Due to his restricted movements, underwent surgery and diagnosed as Post traumatic pseudolipoma. The incidence of post-traumatic pseudolipoma is about 1%

Keywords: Post traumatic pseudolipoma (PTL), lipoma, Inflammation, Blunt Injury.

Introduction

Lipomas are mesenchymal neoplasms that can develop in all parts of the body. Soft tissue lipomas accounts for almost 50% of all soft-tissue tumours. Whereas the incidence of post-traumatic pseudolipoma is about 1%.⁽¹⁾ Pseudolipomas are defined as circumscribed, soft, smooth, usually movable swellings or tumefactions that grossly resemble lipomas. Post traumatic pseudolipoma describes as, lipomas that do not constitute a surrounding capsule. Post traumatic pseudolipoma are a less defined subgroup of pseudolipomas. It develops in areas that are subjected to acute traumatic injury. Initially adair et al⁽²⁾ in 1932 described two patients with lipomas secondary to trauma. This study aimed to review the literature for case reports of PTL in relation to demographic data and to identify possible mechanisms for their development. Post traumatic pseudolipoma presents as an unencapsulated soft tissue tumour of mature adipose tissue in an area where fat is usually not found and develops as a result of direct result of injury.⁽³⁾ PTL effect on the development of a neoplasm. Despite their benign nature PTLs may grow with alarming rapidity in size, making distinction from liposarcoma. PTLs may cause a functional disturbance due to pressure on a peripheral nerve. It has been suggested that the rearrangement of the lipomatous tissue after its herniation caused by deep blunt injury supports the developments of lipomas⁽³⁾ and also the prolapse of normal adipose tissue outside its normal borders has been suggested to be the trigger mechanism for lipoma development.⁽⁴⁾

Case Report

40 year old male presented with a large mass in the right axilla and right side of the chest wall. The mass has been present for over 10 years without causing any symptoms. He presented to the surgeon for the concern of large and expanding lesion. He is unable to do his

routine work because of the large mass in the axilla, which was restricting the movements (Fig. 1). A family tradition since adolescence, he was working in the metal pressing factory. He holds the metal rod in the axilla for the actual shape of the metal vessels. No pain over the swelling. The mass was hanging from the right side of the axilla till right hypochondriac region, infrascapsular region and measuring about 20x18.5cm. Skin texture has become dark brown to black with mild erythema of the overlying skin. Swelling is mobile in all directions. His breast, nipple and areola were normal. No other swelling was found. No lymph nodes were identified. X-ray chest was normal. Ultrasonography shows a hyperechoic mass in the subcutaneous tissue of the axillary region. Magnetic resonance imaging study shows an unencapsulated subcutaneous mass that is isotense to surrounding fat on both T1 weighted and fat suppressed sequence consistent with a benign post traumatic pseudolipoma. His past medical or surgical history were unremarkable. Treatment consists of surgical procedures by replacing the tissue and closing the wound primarily has achieved good results. The excised lesion submitted for histopathological examination. Grossly image shows a large soft tissue mass with skin measuring about 20x18.5cm. Cut-Section of the specimen shows skin with homogenous light yellowish areas (Fig. 2).

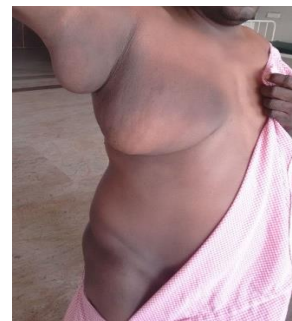

Fig. 1: The mass was hanging from right side of the axilla & infrascapsular region



Fig. 2: Shows cut-Section of the specimen skin with homogenous light yellowish areas

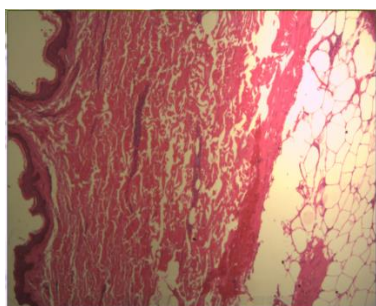


Fig. 3: Shows skin with collagenous tissue admixed with adipose tissue

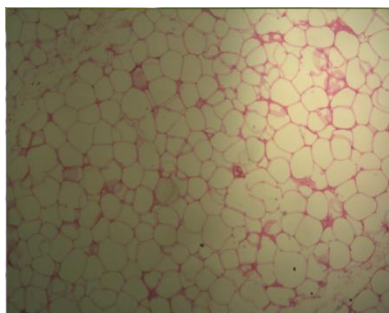


Fig. 4: Shows sheets of mature adipose tissue separated by thin septa

Slide examination reveals a connective tissue stroma with sheets and groups of adipocytes without atypia. The interstitial spaces are often occupied with extravasated red cells and mixed inflammatory cell collections. Focal thrombosis and necrosis are seen (Fig. 3, 4). Postoperative follow-up is by clinical examination and CT scan.

Discussion

Brooke et al,⁽⁴⁾ in 1969 coined the term traumatic pseudolipoma in his case of intraoral prolapse of buccal fat pad. In 1802, Bichat et al,⁽⁵⁾ defined the true fatty nature of the tissue and he was known as buccal fat pad of Bichat." Anatomical, mechanical and more recently, inflammatory factors have been implicated in the aetiology of post traumatic pseudolipoma (PTL). It has been suggested that fracturing, shearing, relocation or prolapse of fat compartments and scar contracture contribute to their development. Galea et al.⁽⁶⁾ 2009 have

postulated that four distinct processes may be of significance, namely: durotaxis; mechanotransduction; recruitment by inductive agents; and angiogenesis. The exact pathogenesis remains unknown. The initial postulated mechanisms for the development of PTL were anatomically and mechanically based. Adipose tissue is arranged in compartmental lobules that are supported by vertical and fibrous septae. Meggit and Wilson et al,⁽⁷⁾ in the original description of PTL, suggested that when excessive force is applied locally to adipose tissue, it may cause fat compartments to fracture, shearing of the anchoring between the skin and the deep fascia. This leads to pouting of adipose tissue, resulting in PTL.

Rozner and Isaacs et al⁽⁸⁾ suggested that the shearing forces of the injury causes separation of the adipose tissue from the deep fascia, resulting in haematoma, bruising and oedema. Later scar contracture in the deeper tissues causes normal adipose tissue and subcutaneous tissue to bunch up, resulting in pseudolipoma. Despite their benign nature PTLs may grow with alarming rapidity and size, making distinction from liposarcoma essential. Depending on the location, PTLs may cause a functional disturbance due to pressure on a peripheral nerve. Blunt trauma causes inflammation in soft tissues. After severe blunt trauma, the levels of chemokines such as interleukin-8 and macrophage inflammatory protein-1b rise significantly and modestly, respectively, in the first 24 hour. Adipose tissue has been identified as a source of several inflammatory factors including tumour necrosis factor-alpha, interleukin-6 and interleukin-8.⁽⁹⁾ The inflammatory factors and cytokines released from dead adipocytes and from the haematoma following blunt trauma are akin to the inductive agents in the chamber. It has been shown that circulating cell populations with adipogenic potential are mobilised by, and engraft at sites of inflammation; including mesenchymal stem cells and fibrocytes. Pre-adipocytes are recognised to express chemokine receptors and have been shown to migrate in response to inflammatory chemokines as well.⁽¹⁰⁾ These inductive agents may recruit these circulating adipogenic cells to the sites of trauma and lead to new adipose tissue formation, resulting in PTL development. Another important aspect in adipose tissue development Angiogenesis in the chamber is an essential prerequisite for growth of adipose tissue. Similarly, the high vascularity of the adipose tissue and possibly the capillary sprouting at the site of trauma is able to support the growing adipose tissue that then forms the PTL. Post traumatic pseudolipoma have to be distinguished from liposarcomas. Because they also found at unexpected locations and an association between traum and the pathogenesis of liposarcoma is not uncommon. With their distinct features on MRI, well differentiated liposarcomas can be detected preoperatively with high sensitivity.⁽¹¹⁾ Ample sampling and a diligent search for diagnostic lipoblasts and cellular atypia are required,

because a lipoma with an ordinary appearance may hide a well differentiated liposarcoma. Definitive management depends on their location, size, or associated symptoms and treatment options include surgical excision or liposuction.

Conclusion

Post-traumatic Pseudolipoma are a subgroup of pseudolipomas that can develop secondary to both acute and chronic trauma. Due to their low incidence and unpredictability of formation, it is difficult to investigate the precise mechanisms of their development and why some people who suffer blunt trauma develop PTL while many others do not. In this article, we postulate that Post-traumatic pseudolipoma development occurs as a result of inflammatory triggers and an optimal local milieu at the site of development. We cannot speculate the natural progression of this lesion however malignant transformation into liposarcoma has never been reported as sequelae of PTLs. To the best of our knowledge, only few cases have been reported in the literature regarding PTLs due to manual metal pressing method in the factories.

References

1. Weiss SW. Lipomatous tumours. In: Weiss SW, Brooks JSJ, eds. Soft tissue tumours. Baltimore, Md: Williams & Wilkins, 1996;207-251.
2. Adair FE, Pack GT, Farrow JH. Lipomas. Am J Cancer 1932;16:1104-20.
3. Lemperle G Posttraumatic lipoma. Plast Reconstr Surg 1998;101:1159-60.
4. Brooke RI, MacGregor AJ: Traumatic pseudolipoma of the buccal mucosa. Oral Surg Oral Med Oral Pathol 1969; 28:223-225.
5. Bichat F: Anatomie generale, a la physiologie et a la medicine. Paris, Grosson, Gabon et cie,1771- 1802.
6. Galea LA, Penington AJ, Morrison WA: Post-traumatic pseudolipomas – a review and postulated mechanism of their development. J plast Reconstr aesthetic surg. 2009;62:737-41.
7. Meggitt BF, Wilson JN. The battered buttock syndrome - fat fractures: a report on a group of traumatic lipomata. Br J Surg 1972;59:165-9.
8. Rozner L, Isaacs GW. The traumatic pseudolipoma. Aust N Z Surg 1977;47:779-82.
9. Bruun JM, Pedersen SB, Richelsen B. Regulation of interleukin 8 production and gene expression in human adipose tissue in vitro. J Clin Endocrinol Metab 2001;86(3):1267-73.
10. Kim CS, Kawada T, Yoo H, et al. Macrophage inflammatory protein related protein-2, a novel CC chemokine, can regulate preadipocyte migration and adipocyte differentiation. FEBS Lett 2003;548:125-30.
11. Gaskin CM, Helms CA: Lipomas, lipoma variants, and well differentiated liposarcomas (atypical lipomas): Results of MRI evaluations of 126 consecutive fatty masses. Am j roengenol. 2004;182:733-9.