

## A Diagnostic Dilemma: Angiolymphoid Hyperplasia with Eosinophilia Imitating Cylindromas

Balvinder Kaur<sup>1</sup>, Khayati Singla<sup>2</sup>

<sup>1</sup>Associate Professor, <sup>2</sup>3<sup>rd</sup> Year PG Resident, Department of Dermatology, GGSMCH, Faridkot

\*Corresponding Author:

Email: drkhayatisingla@gmail.com

### ABSTRACT

*Angiolymphoid hyperplasia with eosinophilia (ALHE) is a benign but locally proliferating vascular lesion comprising vascular channels lined by plump epithelioid endothelial cells surrounded by a lymphocytic and eosinophilic infiltrate. It presents as clustered red to brown coloured translucent nodules around the ear or the hairline in young adults. We hereby report a case of elderly female presenting as multiple nodular lesions on scalp imitating cylindromas showing the histopathological findings suggestive of ALHE.*

**Key Words:** Angiolymphoid hyperplasia with eosinophilia, Scalp, Cylindromas

### INTRODUCTION

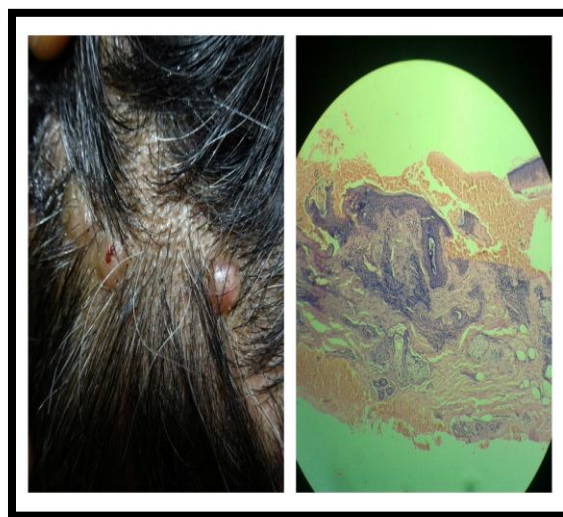
Angiolymphoid hyperplasia with eosinophilia is an uncommon distinct clinicopathological entity characterized by vascular hyperplasia. Numerous factors suggest that it is an unusual reactive process with possible role of trauma, infections (HTLY, HHV-8), hormonal factors like estrogen or arterio venous shunting but none has been proved yet.<sup>1-3</sup> Although benign but few studies have shown T cell rearrangement raising the possibility of ALHE being an early T-cell lymphoma.<sup>4</sup> This entity commonly affects young adults with a female predilection typically appearing as dome-shaped, smooth-surfaced red to brown coloured papules or nodules particularly around the ear or hair line. Less frequently lesions can involve the extremities, trunk, oral mucosa, lips, breast, penis, scrotum, deeper soft tissues or internal organs.<sup>5,6</sup>

### CASE REPORT

A 40 year old female presented to our outpatient department with a history of multiple itchy nodules over the scalp since 2-3 years with history of intermittent bleeding. Patient had no systemic complaints or any history of drug intake. Family history was absent. General physical examination revealed pallor with rest of the vitals & systemic examination within normal limits. Cutaneous examination showed multiple discrete skin coloured to slightly erythematous, soft to firm nodules of size varying from 0.5-1 cm present over the vertex of scalp (as shown in the fig. 1). Overlying skin was smooth. Regional lymphadenopathy was absent. Hairs, nails & mucosae were within normal limits. Routine examination including complete blood count, eosinophil count & urine analysis were found to be normal. Histopathology showed marked dermal vascular proliferation, lined with plump endothelial cells and surrounded by numerous eosinophils and lymphocytes consistent with

ALHE. No atypical mitotic figures were observed (as shown in the Fig. 1).

Patient was treated with cryotherapy with liquid nitrogen using dipstick method at 2 weekly intervals for 2 months with a significant reduction in size of lesions.



**Fig. 1: (Left)-Clinical presentation of the patient (Right)-Histopathology of the lesion**

### DISCUSSION

ALHE first described by Wells and Whimstar in 1961 who considered it to be a late stage of Kimura's disease, but now both are considered to be separate entities with kimura's disease involving deeper tissues like lymph nodes, salivary glands & subcutis, association with lymphadenopathy & no overlying skin lesions initially.<sup>5,7,8</sup> Peripheral eosinophilia is more common in Kimura's disease with raised IgE. Nephrotic syndrome has a stronger association with Kimura's disease as compared to ALHE. Both these entities may rarely co-exist in a same patient with such

a case reported earlier with minimal change disease occurring along with the two entities.<sup>9</sup> ALHE is also known as epitheloid hemangioma or pseudopyogenic granuloma due to its poorly circumscribed lobular appearance on histopathology. Characteristic histopathology shows proliferation of small blood vessels lined by enlarged endothelial cells with uniform ovoid nuclei and intracytoplasmic vacuoles having a cobblestone appearance with a perivascular and interstitial infiltrate composed primarily of lymphocytes and eosinophils.<sup>10</sup> Older lesions reveal more prominent endothelial cells and sclerosis of stroma. In larger lesions involvement of larger blood vessels is seen. ALHE can persist for years, but serious complications do not occur.

In our case the lesions clinically resembled cylindromas, the benign skin appendage tumors due to predilection of lesions for the scalp, the multiplicity of lesions and their gross appearance. Pre-auricular area and ears were spared.

As predicted from the natural history of the disease it is reasonable to wait for 3-9 months for spontaneous resolution to occur. Response to active treatment is variable. Though local recurrences are common, surgery & radiotherapy are effective. Management with intralesional corticosteroids may be a viable alternative in some cases, especially in cosmetically sensitive sites on the head and neck. Other treatment modalities tried are oral propranolol therapy topical timolol, topical imiquimod, topical tacrolimus, and intralesional interferon alfa-2a, systemic corticosteroids, anti-interleukin 5 antibody (mepolizumab), and isotretinoin.<sup>11-15</sup> Surgical modalities include the pulsed-dye laser, carbon dioxide laser, 5-Aminolevulinic acid, photodynamic therapy, cryosurgery and electro surgery have also been reported.<sup>16-18</sup> Recent studies show that intralesional radiofrequency ablation can produce cosmetically better results.<sup>19</sup>

Such an atypical presentation of ALHE poses a diagnostic difficulty. Thus in patients with presence of such nodules on scalp, the possibility of ALHE should be considered.

## REFERENCES

1. Kuo TT, Shih LY, Chan HL. Kimura's disease: involvement of regional lymph nodes and distinction from angiolymphoid hyperplasia with eosinophilia. *Am J Surg Pathol* 1988; 12: 843-54.
2. Zarrin-Khameh N, Spoden JE, Tran RM. Angiolymphoid hyperplasia with eosinophilia associated with pregnancy: a case report and review of the literature. *Arch Pathol Lab Med*. 2005 Sep. 129(9):1168-71.
3. Marcum CB, Zager JS, Bélongie IP, Messina JL, Fenske NA. Profound proliferating angiolymphoid hyperplasia with eosinophilia of pregnancy mimicking angiosarcoma. *Cutis*. 2011 Sep. 88(3):122-8.
4. Kempf W, Haefner AC, Zepter K, et al. Angiolymphoid hyperplasia with eosinophilia: evidence for a T-cell lymphoproliferative origin. *Hum Pathol*. 2002 Oct. 33(10):1023-9.
5. Calonje E. Soft-tissue tumours and tumour-like conditions. In: Burns T, Breathnach S, Cox N, Griffiths C, editors. *Rook's Textbook of Dermatology*. 8<sup>th</sup> ed. Oxford: Wiley-Blackwell; 2010. p. 56.27-8.
6. Chen JF, Gao HW, Wu BY, Tsai WC, Chiang CP. Angiolymphoid hyperplasia with eosinophilia affecting the scrotum: a rare case report with molecular evidence of T-cell clonality. *J Dermatol*. 2010 Apr. 37(4):355-9.
7. Wells GC, Whimster IW. Subcutaneous angiolymphoid hyperplasia with eosinophilia. *Br J Dermatol* 1969;81:1-14.
8. Googe PB, Harris NL, Mihm MC Jr. Kimura's disease and angiolymphoid hyperplasia with eosinophilia: Two distinct histopathological entities. *J Cutan Pathol* 1987;14:263-71.
9. Wang YH, Yin HF. [One patient with Kimura's disease and angiolymphoid hyperplasia with eosinophilia also suffers from kidney injury]. *Beijing Da Xue Xue Bao*. 2008 Aug 18. 40(4):405-7.
10. Olsen TG, Helwig EB. Angiolymphoid hyperplasia with eosinophilia: A clinicopathologic study of 116 patients. *J Am Acad Dermatol*. 1985;12:781-96.
11. Chacon AH, Mercer J. Successful management of angiolymphoid hyperplasia with eosinophilia in a split-face trial of topical tacrolimus and timolol solution. *G Ital Dermatol Venereol*. 2014 Jul 11.
12. Isohisa T, Masuda K, Nakai N, Takenaka H, Katoh N. Angiolymphoid hyperplasia with eosinophilia treated successfully with imiquimod. *Int J Dermatol*. 2012 May 16.
13. Shenefelt PD, Rinker M, Caradonna S. A case of angiolymphoid hyperplasia with eosinophilia treated with intralesional interferon alfa-2a. *Arch Dermatol*. 2000 Jul. 136(7):837-9.
14. Braun-Falco M, Fischer S, Plötz SG, Ring J. Angiolymphoid hyperplasia with eosinophilia treated with anti-interleukin-5 antibody (mepolizumab). *Br J Dermatol*. 2004 Nov. 151(5):1103-4.
15. Carlesimo M, Mari E, Tammara A, Persechino S, Camplone G. Angiolymphoid hyperplasia with eosinophilia treated with isotretinoin. *Eur J Dermatol*. 2007 Nov-Dec. 17(6):554-5.
16. Abrahamson TG, Davis DA. Angiolymphoid hyperplasia with eosinophilia responsive to pulsed dye laser. *J Am Acad Dermatol*. 2003 Aug. 49(2 Suppl Case Reports):S195-6.
17. Sotiriou E, Apalla Z, Patsatsi A, Panagiotidou DD, Ioannides D. Angiolymphoid hyperplasia with eosinophilia: good response to photodynamic therapy. *Clin Exp Dermatol*. 2009 Dec. 34(8):e629-31.
18. Wozniacka A, Omulecki A, Torzecka JD. Cryotherapy in the treatment of angiolymphoid hyperplasia with eosinophilia. *Med Sci Monit*. 2003 Jan. 9(1):CS1-4.
19. Singh S, Dayal M, Walia R, Arava S, Sharma R, Gupta S. Intralesional radiofrequency ablation for nodular angiolymphoid hyperplasia on forehead: A minimally invasive approach. *Indian J Dermatol Venereol Leprol*. 2014 Sep-Oct. 80(5):419-21.