

## A Novel Cell Based Treatment for Avascular Necrosis of Femoral Head: A Case Report

Pradeep V. Mahajan<sup>1</sup>, Prabhu Mishra<sup>2</sup>, Manish Khanna<sup>3</sup>, Anurag Bandre<sup>4</sup>,  
Swetha Subramanian<sup>5</sup>, Manu Menon<sup>6</sup>, Neetin Desai<sup>7,\*</sup>

<sup>1</sup>Chairman & Managing Director, StemRx Bioscience Solutions Pvt. Ltd.

**\*Corresponding Author:**

Email: neetindesai@gmail.com

---

### ABSTRACT

*Avascular necrosis (AVN) of the femoral head is a progressive disease characterized by a vascular insult to the blood supply of the femoral head, which can lead to collapse of the femoral head and subsequent degenerative changes. The femoral head, carpals, humerus are the most commonly affected bones. Regenerative medicine - a branch of translational research, uses cell based therapies in tissue engineering which deals with the process of re-engineering or regenerating human cells, tissues or organs at the defective sites to restore or establish normal function. On the basis of the concept of regenerating cells we present a case that deals with the treatment of avascular necrosis of femoral head in a 35 year old male patient with cell based therapy.*

---

### INTRODUCTION

The healthcare sector is now not just limited to the concept of organ replacement but has shifted to the concept of organ regeneration and cell based therapies have played an important role in this paradigm shift. Cell based therapies are based on the application of stem cells which are differentiating and immunomodulatory. Avascular necrosis is a condition that occurs due to disruption of blood supply to the bone which ultimately leads to collapse of the bone. The conventional treatment of AVN may be non-operative and or operative. Non-operative treatment modalities include elimination of causative factors, use of anti-osteoporotic agents (bisphosphonates etc), analgesics, non-weight bearing exercises etc. Operative treatment includes core decompression, joint preservation and replacement (total or partial) procedures. However, the results of the aforementioned treatment modalities have been unsatisfactory. The extent and the location of the lesion involving the femoral head determines the prognosis of AVN. Ohzono et al. reported that the lesions involving the lateral one third of the weight bearing area or diffuse femoral head involvement had more than 90% chance of collapse<sup>[1]</sup>. Lee et al. stated that the overall collapse rate of AVN (hips) was 78% within 2 years<sup>[2]</sup>. In a case study on AVN of the hip joint, Steinberg et al. reported that 92% of cases progressed to collapse when managed with non-operative treatment<sup>[3]</sup>.

The use of autologous stem cells has shown promise in halting the progression of AVN of the femoral head, and subsequently preventing young patients from undergoing total hip arthroplasty<sup>[4]</sup>. Animal experiments have demonstrated the potential of stem cells to promote neovascularization which effectively increase the blood perfusion in an anoxic environment and thus inhibit further necrosis of tissues<sup>[4,5]</sup>. Thus, transplantation of mesenchymal stem cells may be a

minimally invasive strategy for the treatment of femoral head necrosis.

In 2002, Hernigou and Beaujean first described a technique for injecting mesenchymal stem cells combined with standard core decompression to introduce biologics into an area of necrosis<sup>[6]</sup>. This study was done in 116 patients using autologous mesenchymal stem cells and in 5 years clinical follow up, promising results were observed for the patients of grade II AVN where the progression of the disease was stopped<sup>[7]</sup>. Thus, transplantation of mesenchymal stem cells may be a minimally invasive strategy for the treatment of femoral head necrosis.

In this case report, we describe the treatment of avascular necrosis of the femoral head with bone marrow and platelet concentrate.

### CASE REPORT

A 35 year old male patient came to our hospital with complaint of pain in left hip joint since 10 years. The patient had intermittent pain radiating to his right groin and antero-medial thigh region. He also complained of restricted hip movements with stiffness and mild pain in the lower back. History revealed that the patient had a fall from stairs 15 years ago. No other relevant medical/surgical history was reported by the patient. The patient had consulted an orthopedic surgeon who prescribed painkillers and nutritional supplements. However, relief from symptoms was minimal and temporary.

On the patients' first visit to our hospital, complete clinical, hematological and radiological investigations were done. Clinical scoring of the patients' condition was done based on Harris Hip Score. A total score of 28 (poor) was calculated based on range of motion scores and the findings of marked pain, moderate limp, use of 2 canes/crutches, ability to sit on a high chair for 30

minutes, inability to put on shoes/socks and enter public transportation.

Table 1 shows the range of motion values:

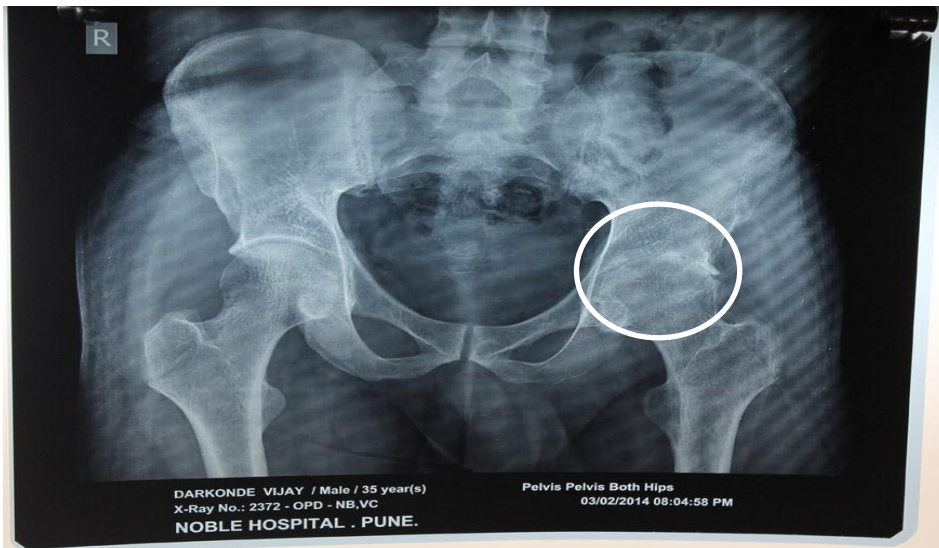
**Table 1: degree of movement**

<b>FLEXION:</b>	<b>40 degrees</b>
<b>ABDUCTION:</b>	<b>10 degrees</b>
<b>ADDUCTION:</b>	<b>10 degrees</b>
<b>EXT. ROTATION:</b>	<b>5 degrees</b>
<b>INT. ROTATION:</b>	<b>8 Degree</b>

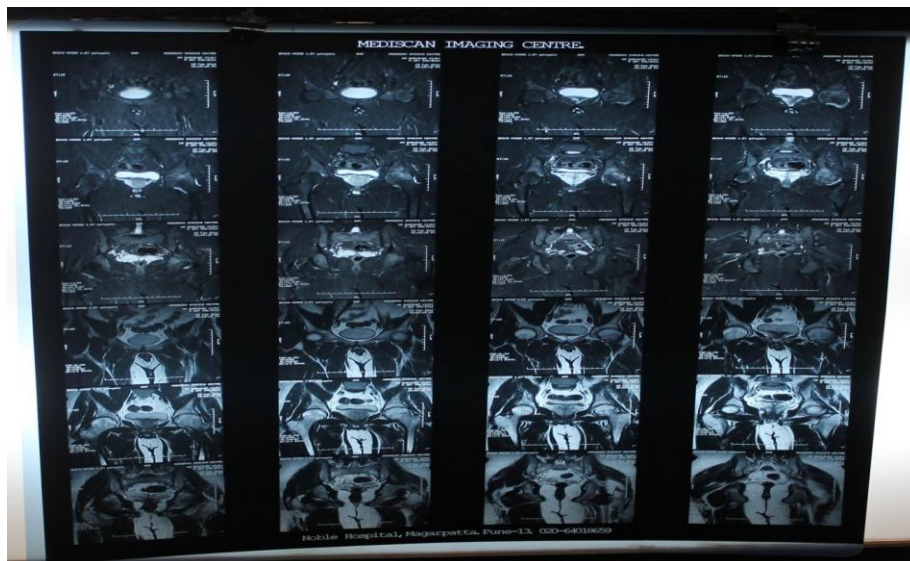Radiological investigations [X-ray (Fig. 1 and MRI Fig. 2)] revealed:

- Marrow oedema in left femoral head, left acetabulum,
- Small erosions in the acetabulum and femoral articular margins,
- Thinning of articular cartilage and reduction in joint space with synovial thickening.

A.P. view of pelvis with both hip joints reveal that left femoral head shows cortical irregularity of articular surface with gross narrowing of left hip joint space. The neck and the cortical head structure are maintained in spite of irregular erosion as described earlier. Osteopenia is visualized. Above findings are suggestive of AVN of left femoral head.



**Fig. 1: XRAY of both hip joints showing AVN affected femoral head area (circled) 03-02-2014**



**Fig. 2: MRI of the hip joint confirming AVN of the femoral head dated 03-02-2014**

Based on the assessment a final diagnosis of avascular necrosis of the left femoral head (Stage II as per FICAT and ARLET classification) was confirmed.

### Clinical Methodology & Treatment plan

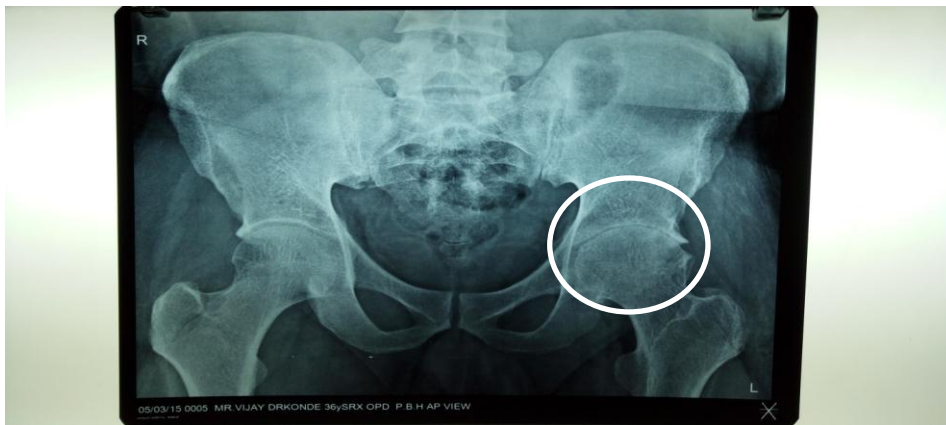
On the basis of clinical findings the patient was admitted for treatment in March 2014 and a personalized treatment protocol was made based on the severity of the condition and general factors such as age of the patient, body mass index etc. The protocol involved harvesting bone marrow concentrate, stromal vascular fraction (SVF) from adipose tissue and platelet rich plasma (PRP) from peripheral blood.

Bone marrow concentrate contains mixed population of progenitor cells comprising of mesenchymal and hematopoietic cells along with mononuclear cells. Stromal vascular fraction isolated from adipose tissue consists of endothelial cells, adipocyte progenitors, immune cells, fibroblasts, pericytes and stromal cells. Platelet rich plasma is a platelet concentrate and a reservoir of cytokines and growth factors. Vascular endothelial growth factor (VEGF), fibroblast growth factor (FGF), platelet derived growth factor (PDGF), transforming growth factor (TGF- $\beta$ ), insulin-like growth factor (IGF) and epidermal growth factor (EGF) that are present in PRP play an important role in the healing process. Transplantation dose was calculated on the basis of cell count and grade of the disease.

### RESULTS

Following treatment, the patient was kept under observation for 48 hours at the hospital. This was a non-interventional period for homing of the cells and for monitoring the general condition of the patient. The patient was advised non weight bearing physiotherapy exercises (passive) such as stretching of the hamstrings, hip flexors and abductors followed by range of motion exercises for the hip and knee. Strengthening exercises were gradually instructed to strengthen primarily the quadriceps, hip abductors and hamstrings musculature. The patient was instructed to continue the rehabilitation exercise program for 1 year.

Follow-up was done periodically wherein clinical and radiological assessment was done. The patient showed gradual improvement in clinical parameters of pain and movements. Harris hip score calculation was done at the 3<sup>rd</sup>, 6<sup>th</sup> and 12<sup>th</sup> month follow-up. At the end of the first year, the score was 89 (good). The patient was free of pain 6 months after treatment. The patient is now able to walk unlimited distances without using cane/crutches, can sit comfortably on any chair and is able to enter public transportation.



**Fig. 3: One year post-operative X-ray of the hip joints dated 05/03/2015**

### Clinical Impression of the result

A.P view of pelvis with both hip joints reveals right hip joint normal and left hip showing improvement in joint space (circled area) compared to the pretreatment X-ray. The cortical irregularity of the articular surface of the femoral head shows improvement. Osteopenia is visualized.

**Impression** Reduction in cortical irregularity noted.

### DISCUSSION

The common causes implicated in the etiology of avascular necrosis of bone are corticosteroid use and trauma which results in interruption of blood supply to the area thus leading to necrosis of the bone. The other causes of AVN may be systemic lupus erythematosus

(SLE), pancreatitis, alcoholism, gout, radiation, sickle cell disease and infiltrative diseases (e.g. Gaucher's disease).

The occurrence of AVN among younger adults, use of prosthesis and risk of surgery limit the application of conventional treatment modalities such as arthroplasty, core decompression etc. Cell based therapy is thus gaining popularity as a non/minimally invasive therapeutic modality in the treatment of various disorders. The unique properties of stem cells namely differentiation potential, self-renewal, anti-inflammation and immune-modulation aid in regeneration of structures/tissues rather than repair which commonly occurs after conventional/surgical treatment modalities.

In our study, the cause of AVN was traumatic injury, which possibly remained undetected in the initial phase. After undergoing cell based therapy, the patient showed gradual improvement with each follow-up which reaffirms the positive effect of cell based therapy in cases of avascular necrosis of femoral head.

Homing of stem cells is a complicated process which involves an array of molecules. Necrosis of cells induces the release of a series of signaling molecules, in which specific receptors or ligands expressed in injured tissues play an important role. Vascular endothelial cells express a variety of adhesion molecules. Stem cells are capable of adhering to these endothelial cells and reach the site of ischemia. Studies have shown that mesenchymal stem cells can not only migrate into the femoral head, but also remain in the region for a relatively long time.

The route of administration of cells also plays an important role in the degree of improvement achieved. In our study, the patient was administered intra-articular and intravenous doses of mesenchymal stem cells. In a study by Zhang-Hua Li et al., intravenous administration of cells resulted in directional migration of the cells to femoral heads to survive in the necrotic environment. The rationale behind intra-articular administration was to achieve higher concentration of cells in the localized area. Nevertheless, further studies should be done to study the directional migration of stem cells in order to formulate more specific treatment protocols.

## CONCLUSION

This case report highlights the positive outcome of cellular therapy achieved in a patient with avascular necrosis of the femoral head. The patient withstood the process fairly well with no obvious complications or adverse reactions. The results are being maintained (after 1 year) and have also resulted in an improvement in the overall quality of life of the patient.

## REFERENCES

1. Ohzono K, Saito M, Sugano N, Takaoka K, Ono K. The fate of nontraumatic avascular necrosis of the femoral head. A radiologic classification to formulate prognosis. *Clin Orthop Relat Res* 1992;277:73-8.
2. Lee MS, Chang YH, Chao EK, Shih CH. Conditions before collapse of the contralateral hip in osteonecrosis of the femoral head. *Chang Gung Med J* 2002;25:228-37.
3. Steinberg ME, Hayken GD, Steinberg DR. The "conservative" management of avascular necrosis of the femoral head. In: Arlet J, Ficat PR, Hungerford DS, eds. *Bone circulation*. Baltimore: Williams and Wilkins, 1984:334-7.
4. Tateishi-Yuyama E, Matsubara H, Murohara T, et al. Therapeutic angiogenesis for patients with limb ischaemia by autologous transplantation of bone-marrow cells: a pilot study and a randomised controlled trial. *Lancet*. 2002 Aug 10;360(9331):427-35.
5. Ikenaga S, Hamano K, Nishida M, et al. Autologous bone marrow implantation induced angiogenesis and improved

deteriorated exercise capacity in a rat ischemic hind limb model. *J Surg Res*,2001,96(2):277-283.

6. Herndon JH, Aufranc OE. Avascular necrosis of the femoral head in the adult. A review of its incidence in a variety of conditions. *Clin Orthop Relat Res*. 1972;86:43-62.
7. Hernigou P, Beaujean F. Treatment of osteonecrosis with autologous bone marrow grafting. *Clin Orthop Relat Res*. 2002;405:14-23.