

Use of Monoclonal Antibody KI-67 in Assessing the Effect of Oral Isotretinoin in Acne Vulgaris Patients

Rohini Pakhiddey^{1,*}, Shipra Paul², Ashish K. Mandal³, Vijay Kumar⁴

¹Assistant Professor, Santosh Medical College, Santosh University, Ghaziabad, ²Director Professor, Department of Anatomy, Lady Hardinge Medical College, New Delhi, ³Director Professor & HOD, Department of Pathology, Vardhaman Mahavir Medical College, New Delhi, ⁴Professor & Head, Department of Dermatology, Maulana Azad Medical College, New Delhi

Corresponding Author:

Email: rohiniddey@gmail.com

ABSTRACT

Introduction: *Acne vulgaris is emerging as a disease of teenagers and young age group which can have serious psychosocial effect if untreated. It has been observed that increased proliferation of pilosebaceous duct keratinocytes leads to its blockage and hence, the development of acne. Ki-67, a nuclear marker expressed by actively cycling cells, has been employed as an operational marker of cell proliferation. Ki-67 can be used immunohistochemically to detect ductal hyper proliferation seen in clinical and subclinical acne lesions. Oral isotretinoin is being increasingly used in treatment of moderate to severe cases of acne vulgaris, the mechanism by which it exerts its action is quite debatable.*

Aim: *To study the effect of oral isotretinoin in the skin of acne vulgaris patients by using Ki-67.*

Methods: *Skin biopsy was procured from untreated patients of severe cases of acne vulgaris. Out of these, twenty histopathologically confirmed patients were included in the study. They were treated with oral isotretinoin in the dose of 0.5mg/Kg/day for 12 weeks, following which their skin biopsies were repeated. Immunostaining for Ki-67 was performed using rabbit monoclonal antibodies. Ki-67 index was calculated for the acne patients before and following treatment with oral isotretinoin. Statistical analysis was done using Wilcoxon Signed-Rank Test.*

Result: *Ki-67 positivity was seen in intrafollicular and interfollicular epidermis in all the 20 patients of acne (12 males and 8 females) before treatment. The Ki-67 index (mean \pm SD) in these patients was higher in females (43.85 \pm 12.24) as compared to males (39.84 \pm 6.98). The Ki-67 index (mean \pm SD) in patients of acne after 12 weeks of treatment showed a reduction in both males and females (19.52 \pm 5.60 and 21.15 \pm 5.2 respectively) as compared to acne patients before treatment. Statistically highly significant post-treatment reduction in Ki-67 index was seen in both male and female patients.*

Conclusion: *By using Ki-67 immunohistochemically, our study implicates that oral isotretinoin causes a reduction in proliferation of follicular and inter-follicular epidermal keratinocytes thereby, having a positive effect on acne skin.*

Keywords: *Ki-67, Ki-67 index, Isotretinoin, Acne vulgaris*

INTRODUCTION

Acne vulgaris represents a significant challenge to dermatologists because of its prevalence, complexity and range of clinical expression¹. Acne is a multifactorial disease, developing in the sebaceous follicles involving pilosebaceous unit and is characterized by follicular hyperkeratinisation, colonization with Propionibacterium acnes (P. acnes) bacteria, increased sebum production, and inflammation². Although, superficial and not life threatening, acne is a disease that, if untreated, can have serious physical and psychological consequences.

The lesions seen in acne may be either non-inflammatory or inflammatory. The non-inflammatory lesions are comedones, which may be open (blackheads) or closed (whiteheads). The inflammatory lesions vary from small papules with an inflammatory area, to pustules to large, tender, and fluctuant nodules. Severe cases of inflammatory acne with large nodule are termed as Nodulocystic or Severe nodular acne. Comedogenesis is due to the accumulation of corneocytes in the pilosebaceous duct. This could be due to hyper proliferation of ductal keratinocytes, inadequate separation of the ductal corneocytes or a

combination of both factors³. Increased sebum production, follicular epithelial cell development and abnormal desquamation play key roles in acne pathogenesis. The epidermis is under constant state of proliferation and desquamation. Abnormal epithelial development or desquamation, either due to increased production of ductal keratinocytes or inadequate separation of ductal corneocytes, or a combination of two, are implicated in acne pathogenesis¹. Although not clinically inflamed, "non-inflamed" lesions including microcomedones (which are considered to be the earliest subclinical "lesion") have been observed to have inflammatory cells present in the peripheral dermis⁴.

Ki-67 antibody is an Ig G1 class, murine monoclonal antibody, raised against a crude nuclear fraction of the Hodgkin's disease derived cell line L428. Ki-67 has been employed as an operational marker of cell proliferation. A number of studies have shown that there is a very tight association between Ki-67 immunoreactivity and the cell cycle, with its expression appearing in mid to late G1 phase of cell cycle⁵. The monoclonal antibody Ki-67 offers a quick and convenient method for estimating the number of

cells in the G 1, S, M, and G2 phases of the cell cycle⁶. The monoclonal antibody stains basal nuclei of keratinocytes in interfollicular and intrafollicular epithelium⁷. Hyper proliferation of ductal keratinocytes has been demonstrated immunohistochemically using a monoclonal antibody to Ki-67, a nuclear marker expressed by actively cycling cells, which labels increased numbers of basal keratinocytes of the follicle wall of both comedones and microcomedones (subclinical lesions) compared with normal follicles⁸.

Isotretinoin is well recognized as a successful therapy for acne vulgaris. Isotretinoin is becoming the drug of choice for severe recalcitrant nodulocystic acne^{9,10}. It has been suggested that Isotretinoin exerts its action by decreasing proliferation of basal sebocytes, suppressing sebum production and inhibiting sebocytes differentiation *in vivo*, reducing sebaceous gland size and sebum production, and as a result alters skin surface lipid composition¹¹. Studies also suggest that Isotretinoin alters the terminal differentiation of sebocytes towards a non-keratinizing, mucosa-like epithelium with reduction of tonofilaments, decreased cohesiveness of the stratum corneum, impaired function of the permeability barrier, and increased transepidermal water loss causing the keratolytic retinoid effect¹². The exact mechanism by which this is achieved remains uncertain, there is no evidence to suggest that isotretinoin affects the metabolic activity of the keratinocytes¹³.

Extensive review of literature indicates the complexity of the pathophysiology of acne vulgaris. The mechanism by which isotretinoin exerts its response on acneic skin is equally debatable. Additionally, ethnic and racial differences have been seen in the clinical presentation of acne vulgaris and hence, in the treatment modality used. Most of the published work on Ki-67 in patients with acne refers to western population. To the best of our knowledge no literature is available on Ki 67 expression in the skin of acne patients in Indian population. To the best of our knowledge, there is hardly any data on the effect of isotretinoin on Ki- 67 expression in acne patients in Indian population. Therefore, the present study was an attempt to assess the effect of oral isotretinoin on the cellular proliferation of acne using Ki-67antibody.

MATERIALS AND METHODS

Sample Collection: The study was conducted on patients between 16 to 25 years of age who presented in dermatology OPD with acne vulgaris in LN Hospital, New Delhi, India. A detailed history of patients presenting with acne was taken. Their lesions were examined thoroughly.

Their lesions were graded as follows:

- Grade I- < 25 comedones without pustules.
- Grade II- 25 - 50 comedones with pustules.
- Grade III- > 50 comedones with pustules and truncal involvement.

- Grade IV- nodular and cystic lesions truncal involvement.

We included twenty histopathologically confirmed patients (twelve males and eight females) with grade III and IV acne vulgaris in our study. A written and informed consent was taken from the patients for the investigations, biopsy and subsequent oral isotretinoin treatment. Before starting the treatment, each patient underwent the following investigations: Complete haemogram, Liver function tests, Kidney function tests, Lipid profile and Serum calcium levels. Patients having normal blood investigations were included in the study. Pregnant patients and patients with past history of hepatitis were excluded from the study.

After taking due approval from Institutional ethical committee, the patients were subjected to punch biopsy from the affected skin before starting the treatment. Oral isotretinoin in the dose of 0.5 mg/kg/day was administered to the patients for 12 weeks. Punch biopsy was obtained from the patients two weeks after stopping isotretinoin treatment.

Study Design: We divided our study into following groups:

- Group I A- 20 patients of grade III & IV acne vulgaris, before oral isotretinoin treatment.
- Group I B- 20 patients of Group IA after 12 weeks of oral isotretinoin treatment.

Specimens were fixed in 10% formalin for 24 hrs. Paraffin blocks were made and 5µm thick sections were cut by rotary microtome. The sections were stained with hematoxylin and eosin.

Immunohistochemical Staining

Thin sections of paraffin block were cut using microtome and taken on poly-L-Lysine coated slides. The sections were deparaffinised followed by three changes of acetone. The slides were then washed and kept in P.B.S. buffer. The slides were then kept in 0.03% Hydrogen Peroxide – methanol block for 30 minutes on shaker. The peroxide block was discarded and three washes of P.B.S. buffer were given. Antigen Retrieval was done. The slides were dipped into pre-warmed citrate buffer (pH 6.0) and were micro waved for 15-30 minutes and then cooled. After antigen retrieval, three washes of P.B.S. buffer were given for 5 minutes each on shaker. Fresh 5% milk block was prepared in working P.B.S. buffer and slides were kept in it for 30 minutes on shaker.

The slides were then cleaned and the sections were covered with primary antibody and kept in the moist chamber for overnight at 4°C followed by three washes of P.B.S. The sections were covered with secondary antibody and kept in the moist chamber at room temperature for 20 minutes. The sections were recovered with tertiary antibody and kept in the moist chamber at room temperature for 20 minutes. Rabbit

monoclonal antibody to human Ki-67 was used for immunostaining. The area surrounding the tissue section was cleaned & covered with working DAB solution and observed under the microscope to see appearance of brown colour. The colour reaction was stopped by dipping the slide into the distilled water. The slides were then washed in running tap water. The sections were counter stained with Harri's Haematoxylin for 10 seconds to 2 minutes. The slides were then washed in running tap water. The sections were dehydrated using three changes of acetone for 5 minutes each. The sections were cleared using three changes of Xylene for 5 minutes each. The sections were then mounted in D.P.X and slides were viewed under the microscope.

Calculation of Ki-67 index: Single block per biopsied material was cut and ten slides per case were made. Digital images of 5 randomly selected high- power fields were obtained per case using a Nikon microscope (Nikon Corp, Tokyo, Japan). Positive cells showing nuclear staining were counted in the basal layers of epidermis. Ki-67 index per case was calculated by the following formula-number of positive cells/total number of cells counted \times 100. The mean Ki-67 index was calculated for each group and data was tabulated separately for males and females.

Statistical Analysis: Pre and post treatment data (mean \pm SD) was tabulated separately for males and female patients. Statistical analysis was done using Wilcoxon Signed-Rank Test for non-parametric data. W-value was used to evaluate our hypothesis. However, Wilcoxon test was not successful in female patients as sample size was very less. Therefore, Levine's test was used to compare AR index in female patients. The p-value $<$ 0.05 was considered to be statistically significant.

OBSERVATIONS

Ki-67 positivity was seen in intrafollicular and interfollicular epidermis in all the 20 patients of acne (12 males and 8 females) before treatment (Figure I, II). There was a visible reduction in Ki-67 positivity in the epidermis of all acne patients after treatment. The Ki-67 index (mean \pm SD) in these patients was higher in females (43.85 \pm 12.24) as compared to males (39.84 \pm 6.98) (Table I). The Ki-67 index (mean \pm SD) in patients of acne after 12 weeks of treatment showed a reduction in both males and females (19.52 \pm 5.60 and 21.15 \pm 5.2 respectively) as compared to acne patients before treatment. Statistically highly significant post-treatment reduction in Ki-67 index was seen in both male and female patients (W=1, critical value of W, at $p \leq 0.05$ was 1 for males and W=0, critical value of W, at $p \leq 0.05$ was 3, Table II & III).

Table 1: Wilcoxon Signed-rank test for Group IA (male acne patients before treatment) & Group IB (male acne patients after isotretinoin treatment) showing statistically significant post treatment reduction in Ki-67 index

W value	Z value	Mean difference	Sum of positive ranks	Sum of negative ranks	Critical value of W at $p \leq 0.05$
1	-2.981	-13.44	77	1	13 (statistically significant)

Table 2: Wilcoxon Signed-rank test for Group IA (female acne patients before treatment) & Group IB (female acne patients after isotretinoin treatment) showing statistically significant post treatment reduction in Ki-67 index

W value	Z value	Mean difference	Sum of positive ranks	Sum of negative ranks	Critical value of W at $p \leq 0.05$
0	Couldn't be calculated as sample size is low	Couldn't be calculated as sample size is low	Couldn't be calculated as sample size is low	Couldn't be calculated as sample size is low	3 (statistically significant)

Table 3: Levene's Test showing statistically significant post-treatment reduction in Ki-67 index in males and female patients having acne

Cases	n	Ki-67 Group IA	Index(Mean \pm SD) Group IB	S.E of difference	p-value
Males	12	39.84 \pm 6.98	19.52 \pm 5.60	2.638	0.0001
Females	8	43.85 \pm 12.24	21.15 \pm 5.2	3.991	0.0007

n- no. of cases

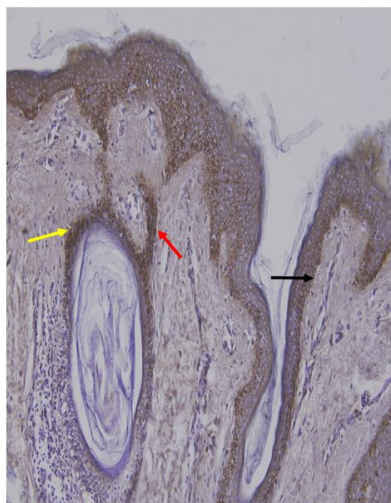
S.D - Standard deviation

S.E of difference -standard error of difference

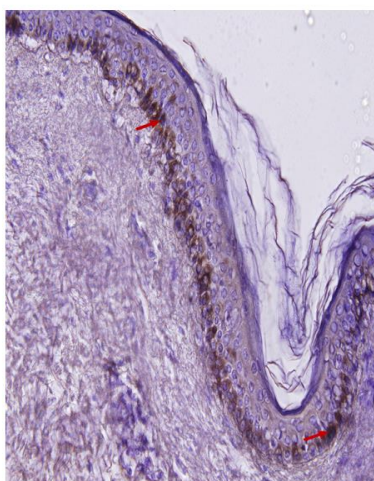
Group IA- Acne patients before treatment

Group IB- Acne patients after isotretinoin treatment

$p < 0.05$, statistically significant



Ki-67 Positivity seen in follicular epithelium (yellow arrow), pilosebaceous duct (red arrow) and interfollicular epidermis (black arrow) of acne patient before treatment



Reduction in Ki-67 Positivity seen in epidermis (red arrows) after isotretinoin treatment

DISCUSSION

Acne vulgaris is a very challenging dermatological disorder seen in all age groups but predominantly in adolescents. Follicular hyperkeratinisation of sebaceous duct is a feature seen in acne. Previous studies have also revealed that a large quiescent population of basal keratinocytes exists in normal pilosebaceous ducts. An unexpected finding of a study was the increased proportion of Ki-67-positive basal nuclei in the interfollicular epidermis contiguous to acne lesions compared with normal epidermis. The results clearly demonstrated that in intrafollicular and interfollicular epidermis of acne individuals there is an increase in actively dividing cells compared with skin from non-acne patients⁵. Use of Ki-67 allows actively dividing cells to be differentiated from quiescent cells. Using Ki-67, the growth fractions of the interfollicular and intrafollicular epidermis of acne have been quantitated. Studies indicate that acne also directly or

indirectly affects the interfollicular areas of the epidermis.

Our study revealed that Ki-67 positivity was seen in intrafollicular and interfollicular epidermis in all the 20 patients of acne (12 males and 8 females) before treatment. Ki-67 positivity was seen in the follicular epithelium, in ductal epithelium and also in the interfollicular epidermis. The results were in conformity with previous study which revealed an increased proportion of Ki-67 positive basal nuclei (percentage positivity of 6.83%-25.26%) in the epidermis contiguous to acne lesions compared with normal epidermis¹⁴. Our study also revealed that females showed more Ki-67 positivity as compared to males in contrast to previous studies which indicated that males are more prone to acne, acne being an androgen dependent dermatoses^{15,16}. Our study also found out a significant post treatment reduction in Ki-67 positivity in both male and female patients

indicating the effectiveness of isotretinoin in acne patients. Our study also indicates that the mechanism by which isotretinoin acts in treating severe acne lesions does involve the reduction in the hyperproliferation seen in follicular and interfollicular epidermal keratinocytes.

CONCLUSION

By using Ki-67 immunohistochemically, our study implicates that oral isotretinoin causes a reduction in proliferation of follicular and inter-follicular epidermal keratinocytes thereby, having a positive effect on acne skin.

LIMITATIONS OF OUR STUDY

The study was a part of PG training program with a limited availability of time. Moreover, owing to certain ethical issues with respect to taking biopsies twice in a patient who was already seeking medical advice for a clinical condition associated with scarring and social stigma, we limited the sample size to 20 patients. Additionally, only clinical grade III & IV patients were histopathologically confirmed and included in our study. However, clinical Grade II patients could exhibit features of moderate acne histopathologically, but these patients are administered only topical and not oral isotretinoin, hence they were not included in our study. Correlation of serum androgen levels in acne patients is suggested in further studies to establish sex differences in the clinical presentation of acne lesions.

ACKNOWLEDGEMENTS

Our study was funded by the Institution for the purpose of research work and we acknowledge our Institution for the support. There were no other financial grants and there were no conflict of interests. We also want to thank the support given by our colleagues and the technical staff who assisted in our research work.

REFERENCES

- Gollnick H. Current concepts of the pathogenesis of acne: Applications for drug treatment. *Drugs* 2003;63(15):1579-1596.
- Cunliffe W, Forster R. Androgen control of the pilosebaceous duct. *Br J Dermatol* 1987;116:449.
- Cunliffe WJ, Holland DB, Clarke SM, Stable GI. Comedogenesis: some new aetiological, clinical and therapeutic strategies. *Br J Dermatol* 2000;142:1084-1091.
- Anthony H.T., Jeremy N, Diana B et al. Inflammatory Events Are Involved in Acne Lesion Initiation. *J Invest Dermatol* 2003;121:20-27.
- Knaggs HE, Holland DB, Morris C, Wood EJ, Cunliffe WJ. Quantification of cellular proliferation in acne using the monoclonal antibody Ki-67. *J Invest Dermatol* 1994;102:89-92.
- Rijzewijk JJ, Van ERP and Bayer FW. Two binding sites for Ki-67 related to quiescent and cycling cells in human epidermis. *Acta Derm Venereol (Stockh)* 1989;69:512-515.
- Liang T, Hoyer S, Yu R, Soltani K, Lorincz AL, Hiipakka RA and Liao S. Immunocytochemical localization of androgen receptors in human skin using monoclonal antibodies against the androgen receptor. *J Invest Dermatol* 1993;100:663-666.
- Cunliffe W J, Holland D B, Clark S M, Stables GI. Comedogenesis: some aetiological, clinical and therapeutic strategies. *Dermatology* 2003;206:11-16.
- Pierard GE, Pierard-Frandchimont C, Le T. Seborrhea in acne-prone and acne-free patients. *Dermatologica* 1987;175(1):5-9.
- Holmes RL, Williams M, and Cunliffe WJ. Pilosebaceous duct obstruction and acne. *Br J Dermatol* 1972;87:327-332.
- Goldstein JA, Comite H, Mescon H, Pochi PE. Isotretinoin in the treatment of acne-histological changes, sebum production, and clinical observations. *Arch Dermatol* 1982 Aug;118:555-558.
- Orfanos CE, Zouboulis Ch.C. Oral retinoids in the treatment of seborrhea and acne. *Dermatology* 1998;196:140-147.
- Dalziel K, Barton S, Marks R. The effects of isotretinoin on follicular and sebaceous gland differentiation. *Br J Dermatol*. 1987;117:317-323.
- Thiboutot et al. Acne vulgaris [Editorial]. *Arch Dermatol* 1999 Sept;135:1101-1102.
- Chaudhary R, Hodgins MB, Van der Kwast TH, Brinkmann AO and Boersma WJA. Localisation of androgen receptors in human skin by immunohistochemistry: implications for the hormonal regulation of hair growth, sebaceous glands and sweat glands. *J Endocrinol* 1992;133:467-475.
- Mowszowicz I, Riahi M, Wright F, Bouchard P, Kuttann F, and Jarvis PM. Androgen receptor in human skin cytosol. *J Clin Endocrinol Metab* 1981;32:338-344.