

Fallopian Tube Prolapse- A Rare Complication of Hysterectomy

Ambarisha Bhandiwad¹, Surakshith L Gowda^{2,*}, Anupama N K³

¹Professor & Head, ^{2,3}Junior Resident, Department of OBG, JSS Medical College & Hospital, JSS University, Mysore, Karnataka, India.

*Corresponding author
E-mail: surakshithlgowda@gmail.com

Abstract

Fallopian tube prolapse is a rare complication of hysterectomy and can be easily mistaken as vaginal granulation tissue or vaginal adenocarcinoma. We are presenting a case of post vaginal hysterectomy fallopian tube prolapse in a 63 year old lady which was managed effectively by vaginal route. By combining routine salpingectomies with hysterectomy can prevent this condition and also provide an additional protection against tubal and ovarian cancers.

Key words: Fallopian tube, Prolapse, Hysterectomy, Salpingectomy, Vaginal granulation, Vaginal adenocarcinoma

Access this article online	
Quick Response Code:	Website: www.innovativepublication.com
	DOI: 10.5958/2394-2754.2016.00017.5

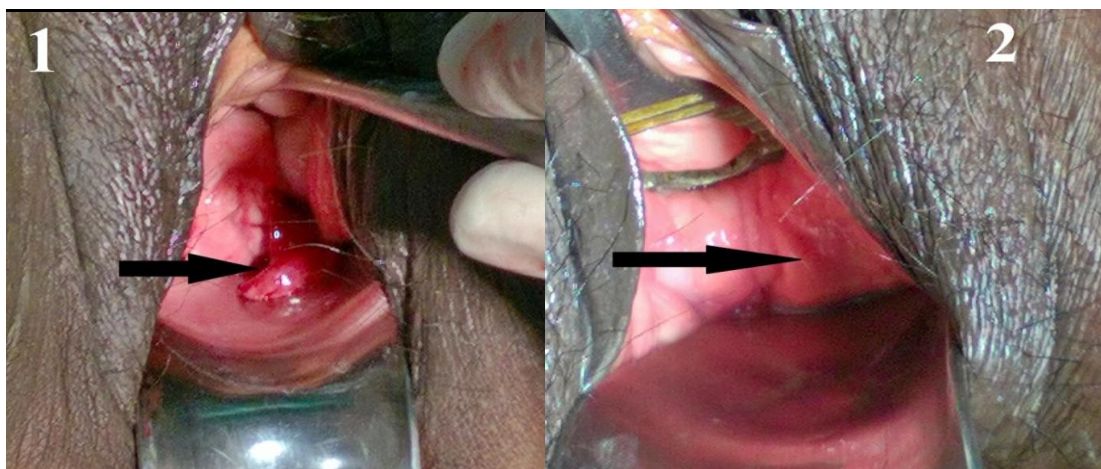
Introduction

Fallopian Tube Prolapse (FTP) is one of the rarely reported complications of hysterectomy. Till 2008 some 100 odd cases were reported [1] and the first case report of 2 cases following vaginal hysterectomy was given by Pozzi in 1902 [1-3] and it was first reported by Funnell et al following abdominal hysterectomy in 1955 [1].

Case Report

A 63 year old Mrs X, para 4 who had attained menopause 20 years back and with post hysterectomy status came to gynaec OPD with a history of excessive watery discharge per vagina since one month with no

other complaints. She had undergone vaginal hysterectomy with rectocele repair 6 months back and had an uneventful post operative recovery. Speculum examination revealed a red fleshy mass from the right side of the vaginal vault which was not bleeding on touch. She was once called for follow up after a month following hysterectomy when she was examined and vaginal vault was healthy without any tag like thing attached to it. Since the fleshy mass attached to the vault was looking like hyperemic fimbrial end of the fallopian tube and also the lumen was visible probable diagnosis of fallopian tube prolapse was made (Figure 1) and it was removed in a minor OT by scraping at the base near its attachment to the vaginal vault and the bleeding point was cauterized using copper sulphate (Figure 2). Specimen obtained was sent for histopathological examination which showed polypoidal structures with many capillaries and fibromixoid stroma resembling a granulation tissue with features consistent with fallopian tube prolapse.



Arrow showing the prolapsed fimbrial end of the fallopian tube fallopian in Figure1 and Figure 2 showing the area of the vaginal vault one week later after removal of the tube vaginally.

Discussion

Incidence

The overall incidence is estimated to be around 0.1% of hysterectomies [2]. It is quoted in the literature that 0.5% of vaginal hysterectomies and 0.06% of abdominal hysterectomies can be complicated by FTP [4]. Fallopian tube prolapse can occur at an average of 4 months following hysterectomy [2]. It is reported as early as during the immediate post operative period to up to 32 years after hysterectomy also, so it can occur at any time following the procedure [2, 3].

Predisposing factors

Early resumption of coitus before complete healing of vaginal vault, uncontrolled diabetes, malnutrition, conditions which increases the intra abdominal pressure like chronic cough and constipation and post operative vault infections, vault hematoma, malignancy and exposure to radiation are some of the predisposing factors for FTP [2,3,5]. Along with the above mentioned predisposing factors for FTP the tube should be of sufficient length and ability to reach the vagina and there should be a defect in the peritoneum or adequate vaginal cuff opening should be there for FTP to occur [6].

Symptoms

Most cases of fallopian tube prolapse will be symptomatic and at times patients can be even asymptomatic [2, 5]. Profuse vaginal discharge (watery or bloody), leaking of urine, post coital bleeding, dyspareunia, lower abdominal pain, foul smelling vaginal discharge are the common symptoms [1,2]. At times patients might complain of certain nonspecific symptoms like abdominal distention, fever, nausea, vomiting, dragging sensation in lower abdomen, which could mislead to a wrong diagnosis [2]. If the diagnosis is delayed, sometimes it can cause potentially catastrophic complication like peritonitis. The most common triad of symptoms are vaginal discharge, dyspareunia and lower abdominal pain [5].

Diagnosis

Definitive diagnosis is by histological examination [2,3] which can be aided by immunohistochemistry by the use of pankeratin antibodies to detect the fallopian tube epithelium in doubtful cases[2]. Sometimes a traction test is useful in diagnosing FTP. On holding the prolapsed part of fallopian tube and pulling down gently, patient experiences pain[3]. Differential diagnosis for FTP includes granulation tissue, vaginal adenosis, endometriosis, vaginal adenocarcinoma, rarely vesicovaginal and ureterovaginal fistulas should also be considered [2].

Management

FTP can be treated surgically by vaginal route, abdominal route or by laparoscopic method, or it can be

a combination of vaginal and laparoscopic route. Total salpingectomy with closure of the vault defect is considered to be the ideal treatment [2]. Laparoscopic route is proposed to be the best as it gives an opportunity to peep into the entire abdomen for any coexisting pathology [1].

Conclusion

Even though FTP is a rare complication of hysterectomy, at times it can be troublesome to the patients. Meticulous tissue handling and proper surgical technique at the time of primary surgery and good postoperative care to prevent infections of the vaginal vault can reduce the incidence of fallopian tube prolapse, however combining routine salpingectomies with hysterectomy can prevent this condition and also provide an additional protection against tubal and ovarian cancers.

Conflict of Interest: None

Source of Support: Nil

References

1. Zutshi V, Aggarwal P, Batra S, Post-hysterectomy Fallopian Tube Prolapse: Elementary Yet Enigmatic, J Turkish-German Gynecol Assoc, Vol. 9(2); 2008:117-119.
2. Ouldamer L, Caille A, Body G (2013) Fallopian Tube Prolapse after Hysterectomy: A Systematic Review. PLoS ONE 8(10): e76543. doi:10.1371/journal.pone.0076543.
3. Bharti A, Kumari S. Fimbrial Prolapse after Abdominal Hysterectomy: A Case Report. Int J Sci Stud 2015;3(2):217-219. doi: 10.17354/ijss/2015/244.
4. Fan QB, Liu ZF, Lang JH, Sun DW, Leng JH, Zhu L, et al. Fallopian tube prolapse following hysterectomy. Chin Med Sci J 2006;21:20-3.
5. Ramin SM, Ramin KD, Hemsell DL. Fallopian tube prolapse after hysterectomy. South Med J 1999;92:963-6.
6. Wetchler SJ, Hurt GJ. A technique for surgical correction of fallopian tube prolapse. Obstet Gynecol 1986;67(5):747-9.