

Pitfalls in Diagnosis of Degenerating Uterine Leiomyomas: A Case Report

Nayana H. Patel¹, Jayprakash Shah², Niket H. Patel³, Nilofar R. Sodagar^{4,*}

¹Gynecologist, ²Honorary fetal medicine expert, ³Clinician,
⁴Research Associate and Research Analyst, Akanksha Hospital and Research Institute,
 Nr. Shrishti English Medium School, Lambhvel, Anand- 388001, Gujarat, India.

***Corresponding Author:**

E-mail: nilofar137@gmail.com

Abstract

Uterine fibroids are very common non-cancerous (benign) growths, occurring in 20% - 30% of women of reproductive age that develop in the muscular wall of the uterus. The sonographic diagnosis of uterine fibroids generally is accepted as accurate with transvaginal sonography. In women who have pelvic masses of unknown cause, unusual manifestations of fibroids such as necrosis or degeneration may simulate a carcinoma or hydrometra resulting in problems with image interpretation. We report a case of an unsuspected large degenerated uterine fibroid in a lady mistakenly diagnosed as didelphysic uterus on ultra sonography.

Key words: Uterine fibroids, didelphysic uterus, ultra sonography, IVF.

Access this article online	
Quick Response Code:	Website: www.innovativepublication.com
	DOI: 10.5958/2394-2754.2016.00019.9

Introduction

Fibroids (leiomyomas) are benign smooth muscle cell tumors of the uterus. Although they are extremely common, with an overall incidence of 40% to 60% by age 35 years and 70% to 80% by age 50 years. Symptomatic uterine leiomyoma are relatively common during the later reproductive years and require treatment in approximately 25% of patients but precise etiology of uterine fibroids remains unclear(1). The diagnosis of fibroids during pregnancy is neither simple nor straight forward(2). Only 42% of large fibroids (>5 cm) and 12.5% of smaller fibroids (3-5 cm) can be diagnosed on physical examination(3). The ability of ultrasound to detect fibroids during pregnancy is even more limited (1.4%-2.7%) primarily due to size of uterus and due to the difficulty of differentiating fibroids from physiologic thickening of the myometrium(4-7). The prevalence of uterine fibroids during pregnancy is therefore likely underestimated.

Acute complications of fibroids are rarely seen but may be serious(8). Spontaneous hemoperitoneum due to fibroid rupture is a rare entity with less than 100 cases reported in the literature(9,10). Intratumor massive bleeding leading to hypovolemia is extremely rare. We report a case of a woman who presented with acute abdomen pain with intraleiomyoma hemorrhage due to rupture of degenerative fibroid during ultrasonography. Our case also illustrates the pitfalls of USG and MRI for diagnosis of complicated uterine fibroid.

Case Report

A 40 year-old woman presented with amenorrhea from last 3 months consulted our clinic for treatment of infertility. Her husband age was 45 year old. In the history of her 25 years of marriage life, she never had conceived pregnancy naturally. Semen analysis of her husband revealed azoospermia. Previously, she had taken IVF treatment using donor sperm, which had led to chemical pregnancy in 2012. She has had history of normal and regular menstruation cycle. On the basis of different indications, it was decided to use donor embryo for IVF. As a standard follow up for IVF, all blood tests were done. 3D sonography and hysteroscopy of uterus revealed certain abnormality. Ultra sound of uterus was done. Ultra sound finding diagnosed possibility of Didelphys Bicolis uterus (Figure 1A to 1B).

After 10 minutes of ultra sound sonography, patient came up with complaint of severe abdominal pain with vasovagal shock, vomiting and hypotension. Patient was duly treated with antispasmodic and pain killers and IV fluid was started. But pain did not subside and the condition even got worse. Again Ultra sound of uterus was done. It's finding showed enlarge and ecogenic mass on right side with tenderness, not showing feature of Didelphys Bicolis uterus, bleeding in the mass was suspected with query of degenerative changes in fibroid (Figure-1C). Magnetic resonance (MR) imaging of the pelvis was performed to determine the cause of symptoms. MRI findings suggested possibility of perforation at right lateral wall of cervix with large collection / hematoma in right adnexa (Figure 2A to 2F). Laparotomy was done; it revealed presence of uterine degenerative fibroid with hematoma (Figure-3). Uterine fibroid was removed measuring 10×9×4 cm. Also there were two sided adnexa. Biopsy was sent for histopathological

examination. Report of histopathological examination stated diagnosis of leiomyoma with degenerative

changes (Figure-4). No evidence of granulomatous pathology or malignancy was found.

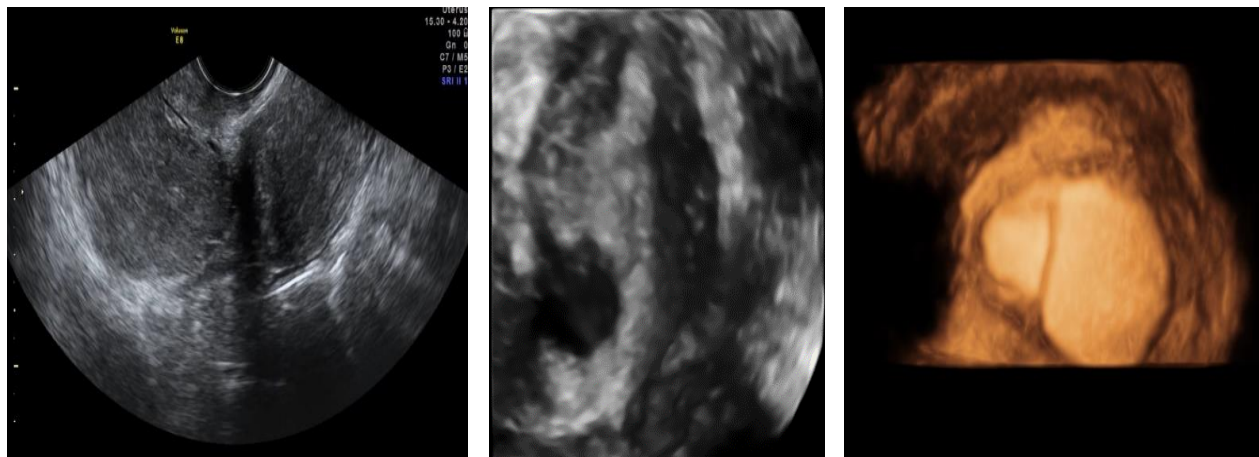


Fig. 1A, 1B, 1C: Ultra sonography Findings

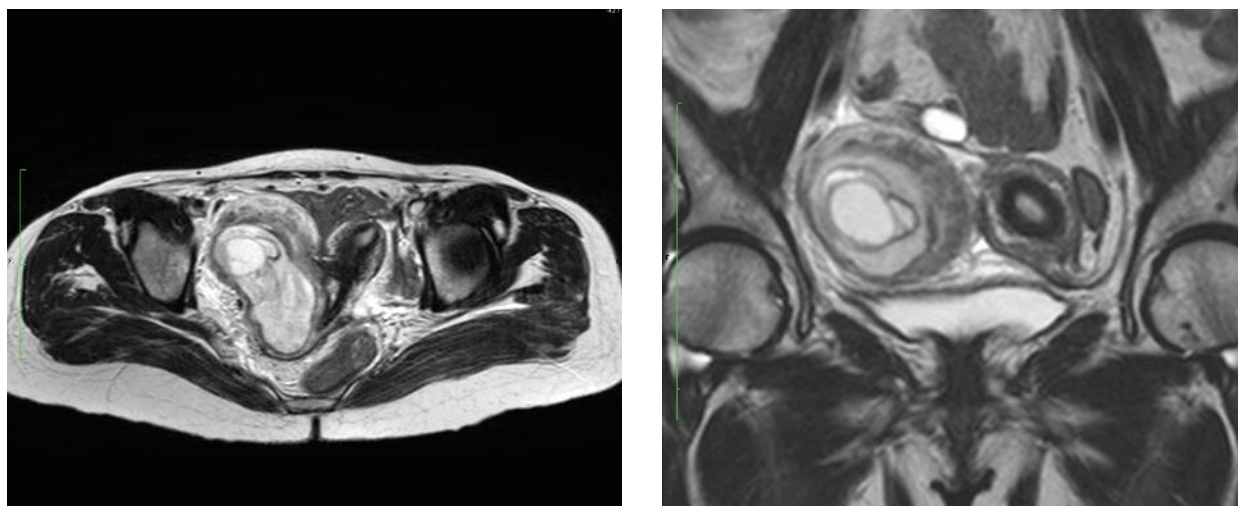


Fig. 2A, 2B: MRI findings: Suggest possibility of perforation at right lateral wall of cervix with large collection/hematoma in right adnexa

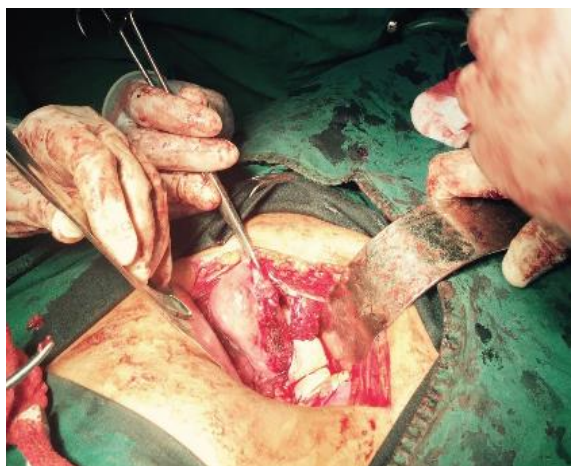


Fig. 3: Laparotomy showing degenerating fibroid

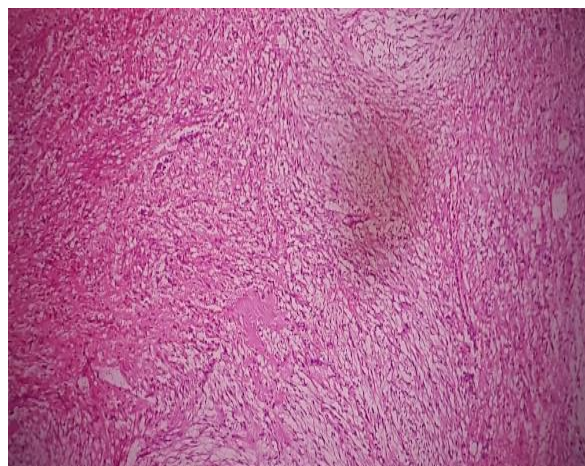


Fig. 4: Histopathological examination showing leiomyoma with degenerative changes

Discussion

Uterine fibroids are common tumors that can cause heavy menstrual bleeding, pelvic pressure symptoms and reproductive disorders.(11) Uterine fibroids have a variety of different sonographic appearances and presentations that sometimes create difficulty in establishing the correct diagnosis. We did extensive literature survey of articles stating pitfalls in diagnosis of uterine fibroids by ultra sonography. Fibroids were most often mistaken for an adnexal mass, bicornuate uterus(12), different forms of internal degeneration(13), hemorrhage, or proteolytic liquefaction(14) or a hydatidiform mole(15, 16). Due to such variable nature of uterine fibroid, with our case, it was misinterpreted as Didelphys Bicolis uterus. Not only USG but also MRI reports were not able to clearly reveal the bleeding uterine fibroid. Due to increased vascularity because of priming of endometrium for IVF, in this case, pressure applied during bimanual transvaginal ultra sonography was suspected to be a cause of spontaneous intra leiomyoma hemorrhage and hemoperitoneum which are very rare complications of uterine leiomyoma.

Conclusion

Though advancement in diagnostic technology, still complicated fibroid are difficult to diagnose due to differentiation in their presentation. Management of ruptured degenerating fibroid requires both surgical and supportive treatments. Intravenous fluids and blood should be infused for significant blood loss. The definitive treatment is surgical, requiring vessel repair and/or myomectomy.

Conflict of interest disclosure statement: The authors declare that they have no conflict of interest.

Source of Support: Nil

References:

1. Day Baird D, Dunson DB, Hill MC, et al. High cumulative incidence of uterine leiomyoma in black and white women: ultrasound evidence. *Am J Obstet Gynecol* 2003; 188:100.
2. Lee HJ, Norwitz ER, Shaw J. Contemporary Management of Fibroids in Pregnancy. *Rev. in Obstet & Gynecol* 2010; 3:20.
3. Muram D, Gillieson M, Walters JH. Myomas of the uterus in pregnancy: ultrasonographic follow-up. *Am J Obstet Gynecol* 1980; 138:16.
4. Burton CA, Grimes DA, March CM. Surgical management of leiomyomata during pregnancy. *Obstet Gynecol* 1989; 74:707.
5. Rice JP, Kay HH, Mahony BS. The clinical significance of uterine leiomyomas in pregnancy. *Am J Obstet Gynecol* 1989; 160:1212.
6. Qidwai GI, Caughey AB, Jacoby AF. Obstetric outcomes in women with sonographically identified uterine leiomyomata. *Obstet Gynecol* 2006; 107: 376.
7. Cooper NP, Okolo S. Fibroids in pregnancy common but poorly understood. *Obstet GynecolSurv* 2005; 60:132.
8. Roche O, Chavan N, Aquilina J, et al. Radiological appearances of gynaecological emergencies. *Insights Imaging* 2012; 3: 265.
9. Lotterman S. Massive hemoperitoneum resulting from spontaneous rupture of uterine leiomyoma. *Am J Emerg Med* 2008; 26: 974.
10. Manopunya M, Tongprasert F, Sukpan K, et al. Intra-leiomyoma massive hemorrhage after delivery. *J Obstet Gynaecol Res* 2013; 39:355.
11. Van Voorhis B. A 41 year old woman with menorrhagia, anemia and fibroids- Review of treatment of uterine fibroids. *JAMA* 2009; 301:82.
12. Baltarowich OH, Kurtz AB, Pennell RG, et al. Pitfalls in the sonographic diagnosis of uterine fibroids. *AJR Am J Roentgenol.* 1988;151:725-728
13. Persaud V, Argcon PD. Uterine leiomyoma: incidence of degenerative change and a correlation of associated symptoms. *Obstet Gynecol* 1970; 35:432.
14. Nocera RM, Fagan CJ, Hemandez JC. Cystic parametrial fibroids mimicking ovarian cystadenoma. *J Ultrasound Med* 1984; 3: 183.
15. Rinehart JS, Hemandez E, Rosenshein NB, et al. Degenerating leiomyomata uteri: an ultrasonic mimic of hydatidiform mole. *J Reprod Med* 1981; 26: 142.
16. Reid MH, McGahan JP, Oi R. Sonographic evaluation of hydatidiform mole and it's look-alike. *AJR Am J Roentgenol* 1983;140:307-311.