

# Can the temporoparietal fascia flap be an alternative for Radial forearm free flap for large defects of the buccal mucosa after ablative surgery for oral cancer? A Case Report

Himanshu Sharma<sup>1</sup>, A. Mohamed Iliyas<sup>2</sup>, Rinku George<sup>3</sup>, Shankar Raja<sup>4</sup>

<sup>1,2</sup>Fellow Student, <sup>3</sup>Chief & HOD, Department of Oral Oncology, <sup>4</sup>PG Student, Department of Oral Surgery, Saveetha Dental College, Tamil Nadu

## Corresponding Author:

**Himanshu Sharma**

Fellow Student, Department of Oral Oncology, Saveetha Dental College, Tamil Nadu

Email: drhimanshuoralsurgeon@gmail.com

---

## Abstract

*The use of temporoparietal fascia as a flap for intra oral defects is a simple and effective alternative among other local flaps like buccal fat of pad, nasolabial flap, palatal flap, forehead flap and sternocleidomastoid muscle flap. Instead of using more complex free flaps like the Radial forearm free flap, this flap can be considered as an alternative.*

*Modified preauricular incision was used to harvest the graft and was tunneled through zygomatic arch to reach the defect site. After surgery defect site showed satisfactory healing with reduced morbidity with no significant complications. The temporoparietal fascia flap proved to be useful alternative for surgeons for reconstruction of buccal mucosa defects with minimal morbidity. It can definitely replace the radial forearm free flap in most instances.*

*In this article we report the use of temporoparietal fascia flap to reconstruct the buccal mucosa defect.*

**Keyword:** Temporoparietal fascia flap, Radial forearm free flap, oral cancer

---

## Introduction

Globally, “oral cancer” is the sixth most common cause of death, although many people are unaware of its existence. In developing countries like India, oral cancer is known to be the commonest of all the cancer accounting for 20 to 30% of all cancer.<sup>1</sup>

More over the person who both smoke and consume alcohol regularly have a multiplicative increase in risk that is up to 10-20 times higher than that of nonsmokers/nondrinkers.

The buccal mucosa and the retromolar trigone are the most frequently encountered primary sites in those areas of world where the chewing of tobacco and the betel nut is common. Buccal mucosa squamous cell carcinoma is considered as aggressive form oral cancer with higher rate of loco regional recurrences.

The risk of nodal metastasis increases from anterior to posterior aspect of the upper aerodigestive track. The factors that determines the rapidity and extent of metastasis are size and thickness of the primary lesion, extent of local

invasion, extracapsular spread, site of the lesion, number and location of lymph nodes.<sup>2</sup>

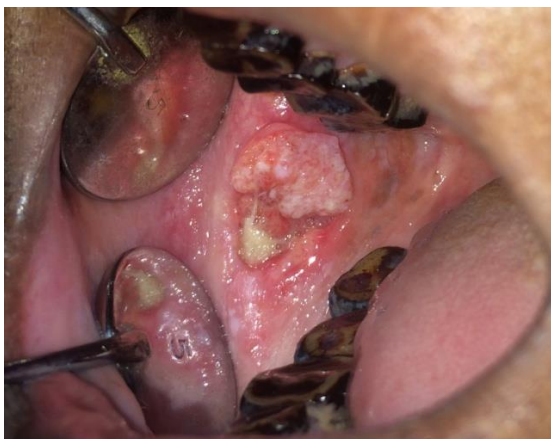The gold standard management for most of the head and neck cancer is surgery that includes wide local excision of the lesion with adequate margins, removal of the draining lymph nodes followed by the reconstruction of the defect.

Now a day, conservative surgical management is suitably accepted than radical surgery by the patient and also by the surgeons. It includes surgical selective neck dissection and modified neck dissection depending upon the severity of the lesion and finally reconstruction with loco-regional flaps.

The presented here is a case of well differentiated squamous cell carcinoma (WDSCC) involving the buccal mucosa with no clinical palpable lymph nodes and was surgically managed by a wide local excision of primary lesion with selective neck dissection addressing level Ia, Ib, level IIa, IIb, level III followed by the reconstruction of surgical defect with temporoparietal fascia.

## Case Report

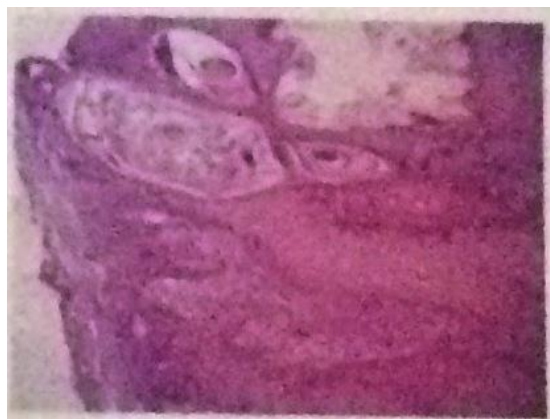
A 55 year old female reported to the oral cancer institute in Saveetha Dental College with chief complaint of ulcer in right side of cheek since past three months. An ulcerative exophytic growth involving the right buccal mucosa extending anteriorly 20 mm away from the angle of the mouth, posteriorly 10 mm away from the pterygomandibular raphe, superiorly till the occlusion plane of maxillary teeth, inferiorly 10 mm away from the labial vestibule (Fig. 1).



**Fig. 1: Intraoral Presentation**

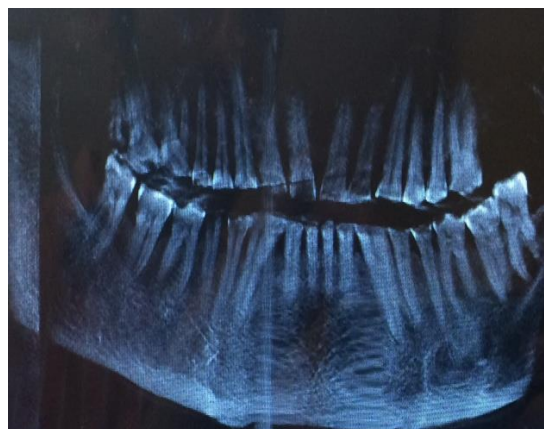Patient had a habit of chewing betel nut chewing for over 40 years. Clinical examination revealed no sign of lymphadenopathy. Patient was recommended denta scan and chest radiograph. No significant findings were present in chest radiograph and clinical staging T2N0M0 was assigned.

Incisional biopsy was performed and it was diagnosed as well differentiated squamous cell carcinoma of buccal mucosa with the suggestive features of the hyperparakeratinised stratified squamous epithelium of variable thickness, with severe dysplasia and break in continuity of the basement membrane (Fig. 2).



**Fig. 2: Histopathology section**

CBCT revealed that the underlying alveolus was uninvolved and lesion was confined to the soft tissues (Fig. 3).



**Fig. 3: CBCT to rule out underlying bone involvement**

A wide local excision of the primary lesion with selective neck dissection and reconstruction with temporoparietal fascia was planned.

## Material and Methods

Under general anesthesia nasotracheal intubation was done. Part preparation was done with povidone betadine. Neck Incision and TPF flap marking was done with ink. Preoperative assessment for planning of the TPF flap was done with a handheld Doppler for the superficial temporal artery (Fig. 4).

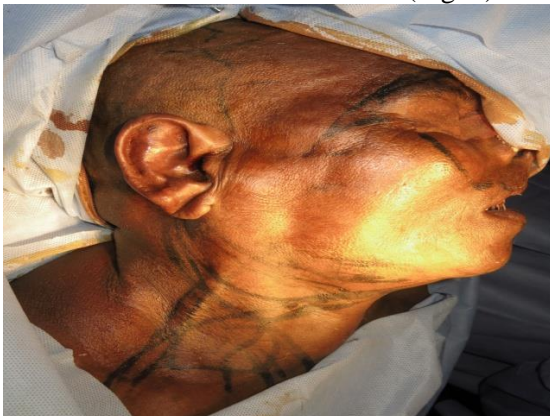Neck incision crossing midline with the posterior limb extending up to the mastoid region was used to expose level Ia, Ib nodes along the submandibular gland, IIa, IIb. Hay's Martins technique was executed to preserve the marginal mandibular nerve. Facial artery and vein was encountered and was ligated. Sternocleidomastoid

muscle was retracted to facilitate the exposure of Level Ia, Ib, and submandibular gland was removed. Dissection was continued to inferiorly, along the SCM and lateral to the sternohyoid muscle to expose the level III and the attached lymph nodes were removed. Spinal accessory nerve was identified and preserved to reach level IIa, IIb and desired node was removed (Fig. 5).

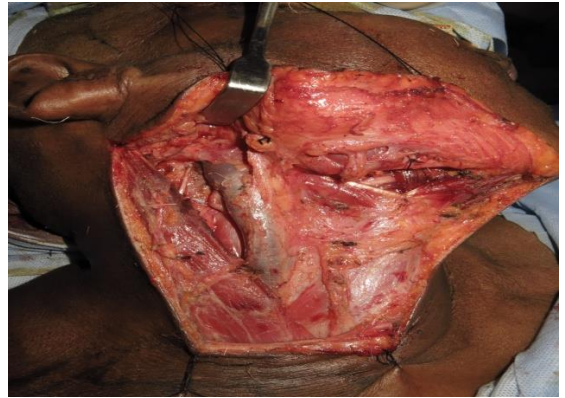
Mucosal markings were placed and was followed by using diathermy. Margins of 1.5 cm were maintained throughout. The specimen was sent for histopathology examination (Fig. 6a, 6b).

Ipsilateral temporal region prepared and flap was outlined after evaluating the size of the defect. Modified preauricular incision was made to gain access to TPF. As the TP fascia is adherent to the subcutaneous tissue which makes the dissection very skillful. Dissection was performed in the subcutaneous plane. To ease harvesting, the dissection was performed in inferior to superior direction. Once the fascia was exposed the location of artery was identified. With the planned flap dimension decided, an incision was made central to the vessel and deep to temporalis fascia. Following this, dissection was carried down from superior to inferior direction elevating the TPF (Fig. 7). While doing so temporal branch of facial nerve should be preserved, which crosses the zygomatic arch 2cm away from the external auditory canal<sup>3</sup>. The nerve is 3cm superior and 2cm lateral to the superior orbital rim.<sup>4</sup>

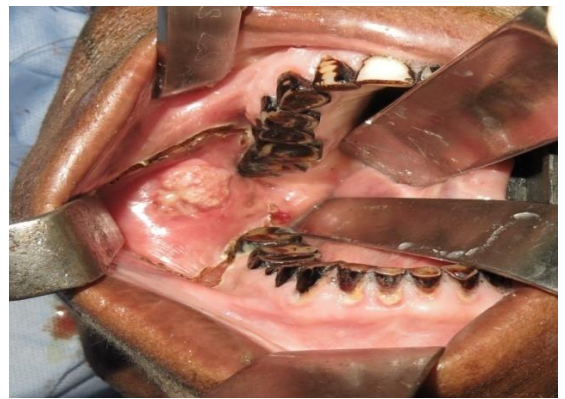Once the flap was raised, a soft tissue tunnel was made intraorally following the zygomatic arch with artery forceps. The TPF was delivered to the recipient tissue bed through the prepared tunnel over the zygomatic arch and was secured with sutures (Fig. 8a, 8b). Care should be taken to avoid injury to Stensen duct. The donor site and neck wound was closed with derma bond (Fig. 9).



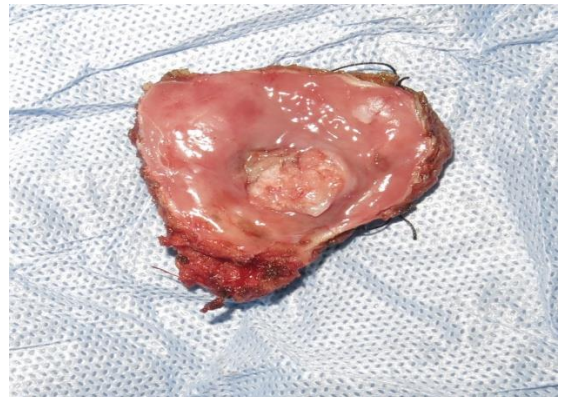**Fig. 4: Incision marking**



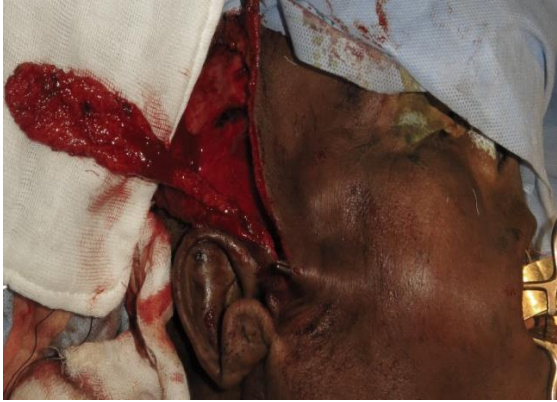**Fig. 5: Selective Neck Dissection**



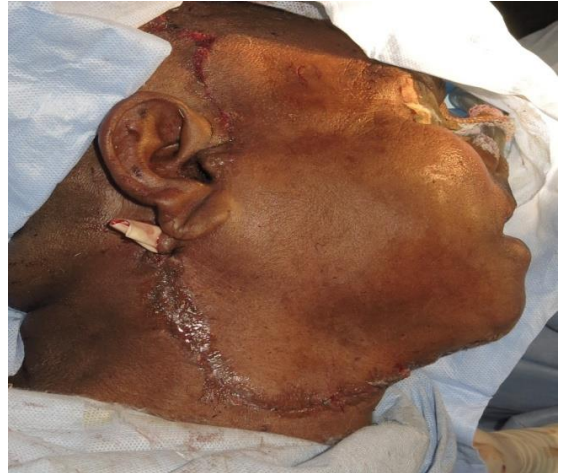**Fig. 6 a: Primary lesion marking**



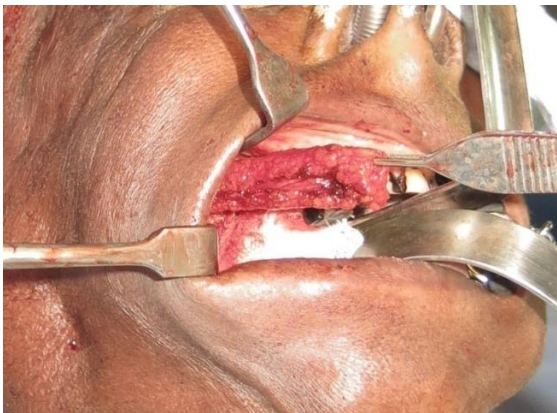**Fig. 6 b: Specimen for Excisional biopsy**



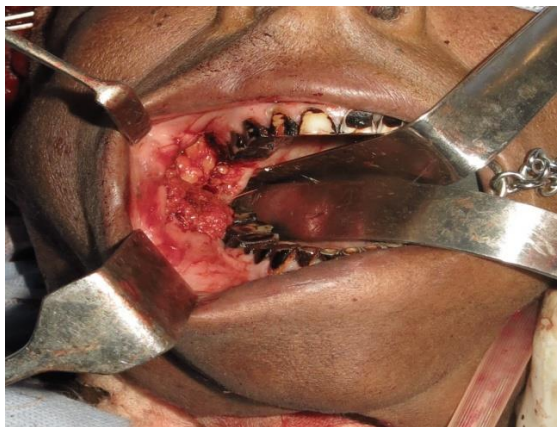**Fig. 7: TPF flap elevated**



**Fig. 9: Closure**



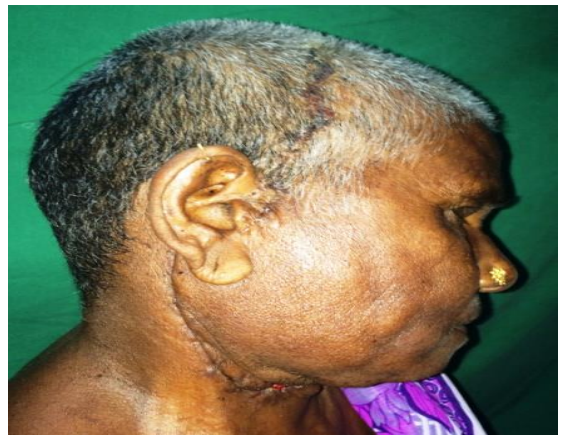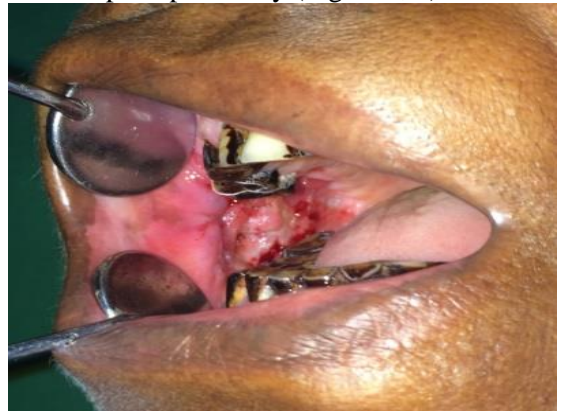**Fig. 8 a: TPF tunneled intra orally**



**Fig. 8 b: TPF over recipient site**

### Result

The flap showed significant healing to the recipient site and minimal scar visibility at the donor site. No functional complications were present and esthetically acceptable result was obtained with minimal morbidity. Use of derma bond also proved to be beneficial with no scar formation postoperatively (Fig. 10a, b).



**Fig. 10a, b: 1 month postoperative**

## Discussion

Temporal arterial system consisting of temporalis muscle flap, temporoparietal fascia (TPF) flap provides the favorable donor site for head and neck reconstruction. Temporalis system flap was introduced in 1800s and made its special position among reconstructive surgeons. Low donor site morbidity and proximity to the recipient sites makes the flap more versatile and primary reason for their popular demand.<sup>5</sup>

Few Indications of TPF are reconstruction of oral defects<sup>6</sup>, obliterations of orbital defects<sup>7</sup>, auricular reconstruction<sup>8</sup>, midface reconstruction<sup>9</sup>, reconstruction of hair bearing upper lip or brows.<sup>10</sup> Contraindications associated with this flap are previous trauma to scalp and temporozygomatic region.

Flaps used for buccal mucosa reconstruction depends upon the defects size. Small defects can be closed primarily. Larger superficial defects by quilted skin/mucosal grafts, TPF flap. Large full thickness defects by PMMC flap, Latissimus dorsi myocutaneous flap, fasciutaneous free flap.<sup>11</sup> Additional consideration should be given when extending the pedicle length by extending the superior margin of flap to midline of scalp, dissection of facial nerve<sup>12</sup>. Complications associated with this flap are flap necrosis, alopecia. Park and colleagues<sup>13</sup> conducted a review of 109 pedicle TPF flaps and reported 5 cases of partial necrosis. It can be managed by excising the necrotic tissue and by further advancing the distal portion of flap. Second complication associated with this flap is alopecia. Thermal damage during dissection or excess of superficial plane is commonest cause. Helling and colleagues<sup>14</sup> suggested that endoscopic assisted TPF flap minimizes the risk of alopecia.

Usage of free flaps like radial forearm lengthens the surgery and in cases of flap failure it causes much morbidity with the necessity for another flap. There is also the problem of donor site morbidity. The temporoparietal fascia flap produces virtually no morbidity with the donor site, can be closed primarily and is a robust pedicled flap supported by the superficial temporal artery.

## Conclusion

Flap from the temporal arterial system is an excellent option for head and neck reconstruction

with minimal donor site morbidity, ease of harvesting and versatility in flap defects.

Even damage to facial nerve branches are rarely encountered as the flap is tunneled subcutaneously and brought into the oral cavity, which can be quite safely performed.

In patients with defects which may be too large to be covered with the buccal fat of pad, this flap can be used with good results instead of more complicated and time consuming radial free flap which even produces lot of donor site morbidity. This flap does not need special equipment's to harvest but a loop with a magnification of 2.5x. This will help to avoid cutting through the hair follicles which if damaged will cause loss of hair growth from that follicle.

## References

1. Nair UJ, Friesen M, Richard I. Effect Of lime composition on the formation of reactive oxygen species from areca nut extract in vitro. *Carcinogenesis* 1990;11(12):2145-2148.
2. Gnepp DR. Diagnostic surgical pathology of the head and neck. Philadelphia: Saunders; 2001. p(xi,888).
3. Ellis E, Zidde MF. Surgical approaches to the facial skeleton section III p69.
4. Seckel BR. "Facial danger zone2". Facial danger zones; avoiding nerve injury in facial plastic surgery. 1<sup>st</sup> edition. St Louis (MO); Quality Medical Pub; 1994.p. 12-7.
5. Verneuil AA. De la creatuind'une fausse articulation par sectio ou resection partielle de l'os maxillaire inferieure. *Arch Gen Med V Serie* 1872;15:284.
6. Pinto FR, de Magalhaes RP, et al. Pedicled temporoparietal galeal flap for reconstruction of intraoral defects. *Ann Otol Rhinol Laryngol* 2008;117:581-6.
7. Lai A Cheney ML. Temporoparietal fascial flap in orbital reconstruction. *Plast Reconstr Surg* 2000;2:196-201.
8. Ibrahim SM, Zidan A, Madani S. Totally avulsed ear: new technique of immediate ear reconstruction. *J Plast Reconstr Aesthet Surg* 2008;61:S29-36.
9. Parhiscar A, Har-El G, Turk J et al. Temporoparietal osteofascial flap for head and neck reconstruction. *J Oral Maxillofac Surg* 2002;60:619-22.
10. Ward BB. Temporalis system in maxillary reconstruction: temporalis muscle and temporoparietal galea flaps. *Atlas Oral Maxillofac Surg Clin North Am* 2007;15:33-42.
11. Song M, Chen FJ, Guo ZM, Zhang Q, Yang Ak. Applications of various flaps to intraoral reconstruction of buccal defects after resection of buccal mucosa carcinoma. *Ai Zheng*. 2009 Jun;28(6):663-7.
12. Din Lam, Eric R, Carlson. The local and regional flaps of head and neck. *Oral maxillofacial Surg Clin N Am* 2014;26:359-69.
13. Park C, Lew DH, Yoo WM. An analysis of 123 temporoparietal fascial flaps: anatomic and clinical considerations in total auricular reconstruction. *Plast Reconstr Surg* 1999;104:1295-306.
14. Helling ER, Okoro S, Kim G, et al. endoscopic assisted temporoparietal fascia harvest for auricular reconstruction. *Plast Reconstr Surg* 2008;121:1598-605.