

Management of Idiopathic Clubfoot By Ponseti Method – Our Experience

Sameer Wooly¹, Anand Kumar.B.S^{2,*}

^{1,2}Assistant Professor, Dept. of Orthopaedics,
PESIMSR, Kuppam, AP, India

***Corresponding Author:**

E-mail: anandsrinivasappa@gmail.com

Abstract

Background: Clubfoot occurs approximately 1 in 1000 live births and is one of the most common congenital birth defects. There have been many reports of successful treatment of idiopathic clubfoot with Ponseti method in the western world, but there are only few studies done in the developing country like India. So the present study was undertaken with the following objective.

Objective: To evaluate the efficacy of Ponseti method in the treatment of idiopathic clubfoot.

Methodology: A study was conducted from August 2013 to August 2014 in our Hospital attached to PESIMSR. 25 patients (36 clubfoot) were evaluated in our study. All patients were treated by manipulation and casting as described by Ponseti. Main outcome measures included in the study were, the degree of correction of the deformity and the effect of different variables in the course of management.

Results: In our study, we treated 25 babies with idiopathic clubfoot by Ponseti method, among them 11 had bilateral affection. The mean age of the babies was 14 weeks. Out of the 25 babies, 30 of the 36 feet had deformity of a severe grade i.e., Pirani score of 5. The mean number of casts required was 5.8. Tenotomy was required for 26 feet. The average number of casts required were increased as age of presentation increases indicating increasing difficulty and delay in correction of babies who presented late. The results were excellent in 64% (16 out of 25) and good in 28% (7 out of 25). The average Pirani score for the group at the presentation was 5.47 (4.5 to 6) and the mean Final Pirani score was 0.25 (0 to 0.5) which was statistically significant.

Conclusion: Ponseti method is a very safe, efficient and economical treatment for the correction of clubfoot which radically decreases the need for extensive corrective surgery. The results are excellent when treatment begins early.

Keywords: Ponseti method, Idiopathic clubfoot, Pirani score, Tendotomy.

Access this article online	
Quick Response Code:	Website: www.innovativepublication.com
	DOI: 10.5958/2395-1362.2016.00013.X

Introduction

It is estimated that more than 1,00,000 babies are born worldwide with congenital clubfoot every year ; incidence being one in every 1000 births.⁽¹⁾ A large proportion of these babies are born in countries where they remain untreated or poorly treated leaving them to face disability. Neglected clubfoot causes physical, social, psychological and financial burden on the patients, their families and the society. Surgical management was in focus for many years in developed countries. But extensive corrective surgeries were associated with disturbing failures and complications.⁽²⁾

Non-Operative management, though preached and practiced for centuries was not very popular because of their lower success rates. French, kites and Copenhagen techniques were followed by orthopaedists for a long period. The initial management of clubfoot is now Non-Operative.⁽³⁾

Late Dr. Ignacio Ponseti developed a method of clubfoot correction that is effective, inexpensive and long term follow up studies reveal that foot treated by

Ponseti technique are strong, flexible and pain free.^(2,4) This method is very effective especially in developing countries as the treatment is economical to parents and more effective on the babies. More recently studies have been and are still being conducted worldwide to prove that Ponseti method should be the initial management of clubfoot, be it idiopathic or associated with any neurological defects.

There is a need for similar study in our Indian setup where blind beliefs, superstitions, poverty and ignorance pose a bigger challenge. Hence the above study was taken with the objectives, to assess the efficacy of Ponseti method in the management of Idiopathic Clubfoot and to study the effect of age of presentation on the course of management and the end result.

Late Dr. Ignacio Ponseti developed a method of clubfoot correction that is effective, inexpensive. Studies with long term follow up reveal that foot treated by Ponseti technique are strong, flexible and pain free.^(2,4) This method is especially effective in developing countries as the treatment is economical to parents and very much effective on the babies. More recently studies have been and are still being conducted worldwide to prove that Ponseti method should be the initial management of clubfoot, be it idiopathic or associated with any neurological defects.

There is a need for similar study in our Indian setup where blind beliefs, superstitions, poverty and

ignorance pose a bigger challenge. Hence the above study was taken with the Clubfoot and to study the effect of age of presentation on the course of management and the end result.

Materials and Methodology

A prospective study was done among all the patients below 1 year of age with Idiopathic Clubfoot presenting to our Hospital attached to PESIMSR, Kuppam, Andhra Pradesh between August 2013 to August 2014 who were treated by Ponseti method.(Fig. 1) Ethical clearance was taken from institution ethical committee. Data was collected by taking complete history including consanguinity, prenatal, intra-natal, postnatal and developmental milestones. A written informed consent was taken from parents. Parents were educated about the condition, various methods of management and more importantly the course of Ponseti method. Babies were followed up for a minimum of 1 year. The severity of the deformity was graded according to Pirani Scoring.⁽⁵⁾ A total of 36 feet confirmed by experts to have Untreated Idiopathic Clubfoot were enrolled in the study.

Inclusion Criteria: Babies aged less than one year with idiopathic clubfoot were included in the study.

Exclusion Criteria: Babies with clubfoot associated with neurological defects, congenital spine and hip deformities and whose foot previously treated by same or other methods were excluded from the study.

Treatment Regimen – The Ponseti Way

The treatment was in 2 stages: Correction of the deformity by weekly serial casting and Maintenance of that correction by bracing. Casting should be done as soon as possible after birth. In some babies with fragile neonatal skin treatment can be postponed to a week or two later. Initial severity of club foot was assessed by Pirani scoring. The cavus deformity was corrected first by supinating the forefoot to bring it in alignment with the hind foot. Long leg cast was applied to maintain this correction for 1 week. (Fig. 2a, b) Next week the cast was removed in the outpatient and again scoring was done to check the improvement and compliance. Over the next 2 to 3 weeks the foot was serially abducted and casting was done to bring about over correction. (Fig. 3) Additional casting sometimes would be needed.

When the calcaneum was sufficiently abducted beneath the talus, scoring was done. When mid foot score falls below 1 but hind foot score remained over 1, it was indicative of residual equinus deformity requiring release of the contracture, for which Percutaneous Tendo-Achillis Tenotomy should be done. Tenotomy was done under sedation achieved by syrup pedicloryl and local anaesthesia. (Fig. 4) Long leg cast was applied for the next 3 weeks. (Fig. 5) All tenotomy wounds were inspected by 1 week.

Babies were then shifted to Maintenance phase by bracing them in Denis Browne splint (Fig. 6) ; 23 hours a day for the first 3 months and then 14 hours a day for 3 years. Weekly follow up was done during initial periods of bracing to ensure compliance and to periodically assure and educate the parents. Later monthly follow up was done for about 1 year. (Fig. 7)

Each foot was evaluated cosmetically, functionally and rated according to the following criteria:

A. Excellent

- Complete correction of all components of the deformity
- Plantigrade cosmetically acceptable foot
- Pliable subtalar motion and dorsiflexion to less than 90 degrees

B. Good

- Complete correction of all components of the deformity
- Fully plantigrade, supple and mobile foot with minor degree of persistent
- metatarsus adductus

C. Average

- Plantigrade and functionally acceptable
- Cosmetically less acceptable
- Some loss of initial correction, which amenable to re manipulation or repeat tenotomy.

D. Poor

- Loss of correction and recurrence of the deformity requiring soft tissue release
- Rigid clubfoot resistant to manipulation in first place

Observations and Results

In our study, 15(60%) of the babies were males and remaining 10(40%) were females, among which 11(44%) of the babies had bilateral deformity, 8(32%) had right foot deformity and 6(24%) had left foot deformity. So practicality we were dealing with of the 15 babies(22 foot) presented in less than 4 months group, 7 babies (9 foot) presented between 4-8 weeks and 3 babies(5 foot) presented to us after 8 months.(Fig. 8)

The mean of the initial Pirani scores and the mean of the final Pirani scores of the 3 age groups in which the babies presented were calculated and the following data was obtained. (Table 1).The trends to be noted in the graph are deformity was more severe among those who presented late which is depicted by rise of the blue line. The gap between the two lines in the graph shows the difference in the Initial Pirani score and Pirani score after the treatment, which depicts the improvement of Pirani score, in turn the condition of the child. Later the presentation more severe will be deformity. The response may be good even in late presentation but not as much as early presentation which is depicted by the rise in the red line. (Fig. 9)

Percutaneous Tendo achillis tenotomy is an integral part of Ponseti method. Objectively the decision is taken when Midfoot score has fallen below 1 indicating complete correction of cavus, varus and adduction. In our study tenotomy was done in 72% of the cases. (Table. 2)

The graph clearly depicts the direct correlation between initial severity of the deformity and the number of casts required to correct it. So, more the deformity or later the presentation, more are the number of castings required with more number of visits. (Fig. 10). The results were excellent in 64% (16 out of 25) and good in 28% (7 out of 25) when graph was plotted number of clubfoot in y-axis and outcomes in x-axis. (Fig. 11) The average Pirani score for the group at the presentation was 5.47 (4.5 to 6) and the mean final Pirani score was 0.25 (0 to 0.5) with a 'p' value of 0.001 hence being statistically significant. (Table 3)

Table 1: Initial and final Pirani scores

Age group	Mean initial Pirani	Mean final Pirani
< 4 months	5.34	0.13
4-8 months	5.61	0.27
>8 months	5.8	0.7

Table 2: Percutaneous tenotomy

Treatment	No. of feet	Percentage
Only serial casting	10	28
Casting + tenotomy	26	72

Table 3: Paired t test to compare initial and final outcomes

variables	Mean	Standard Deviation	P value
Initial Pirani score	5.4722	0.67554	< 0.001
Final Pirani score	0.2500	0.30472	

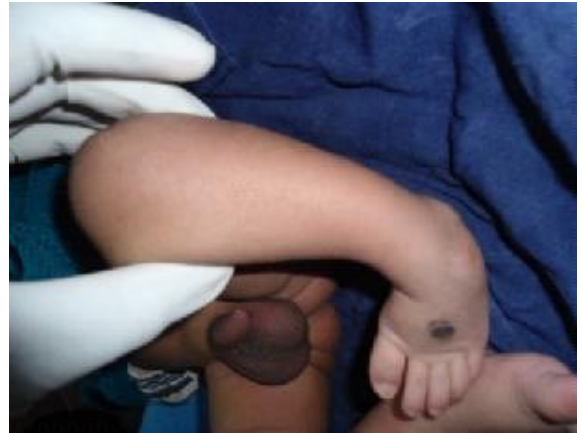

Fig. 1: At presentation

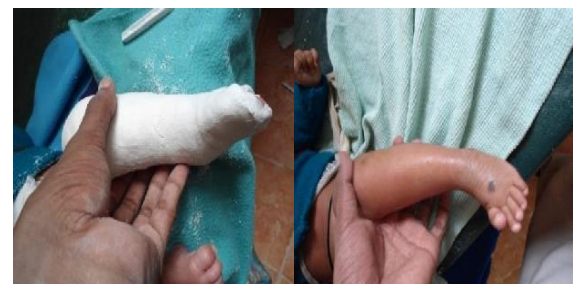

Fig. 2(a,b): Second visit

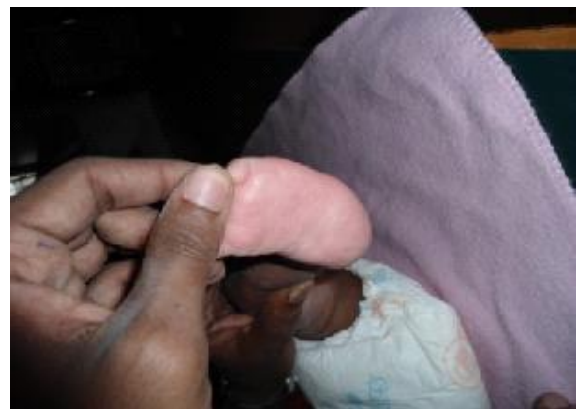

Fig. 3: Subsequent follow ups

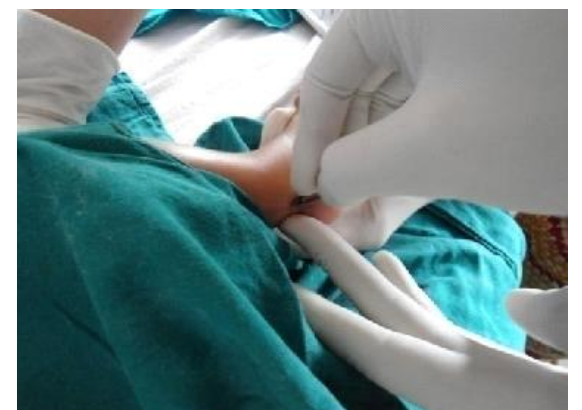

Fig. 4: Tenotomy

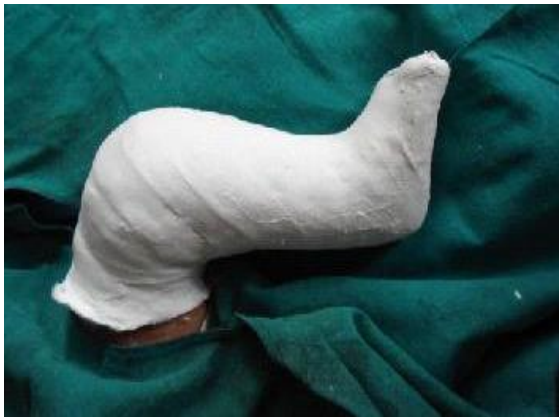

Fig 5 Post tenotomy cast

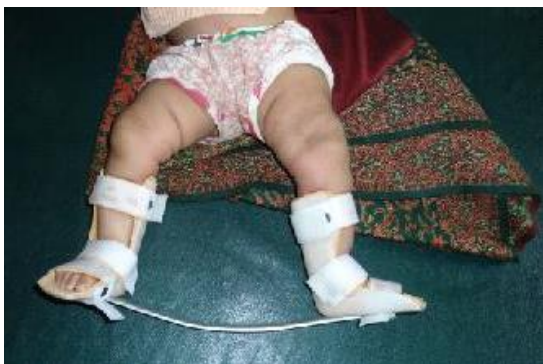

Fig 6: On DB splint

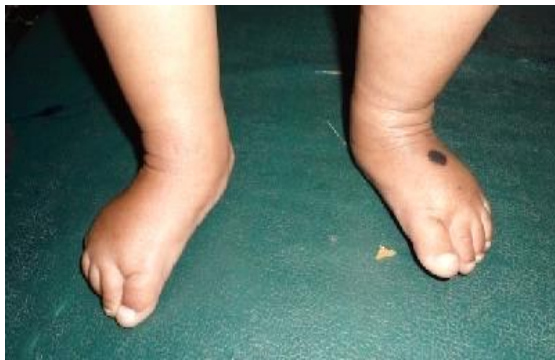

Fig 7: One year follow up

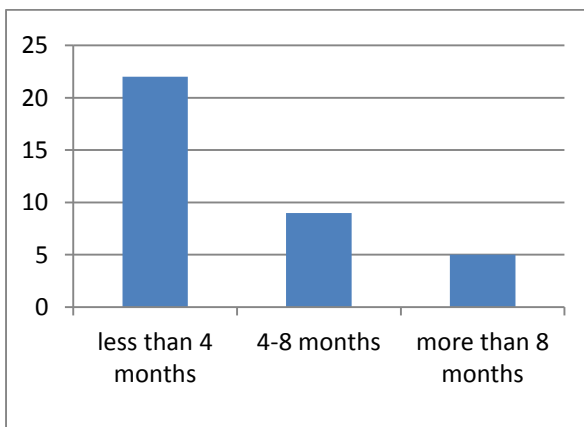


Fig 8: Age distribution of the no. of clubfoot

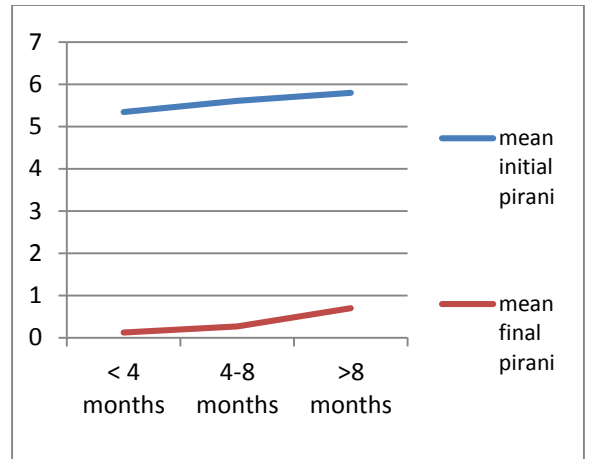


Fig. 9: Mean Initial and final Pirani scores

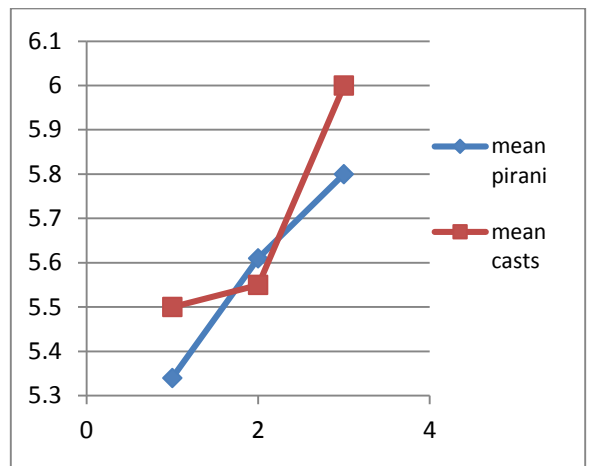


Fig. 10: Relationship between initial severity and no. of casting required

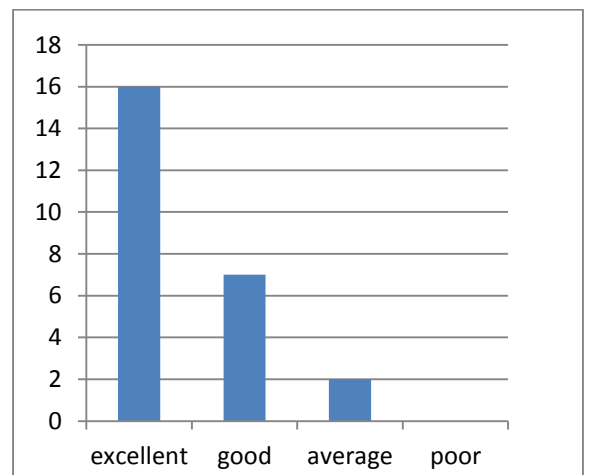


Fig. 11: Final outcome

Discussion

Clubfoot or congenital talipes equinovarus is a complex deformity of foot whose etiopathogenesis remains poorly understood. The effect of the deformity on the social and physical life of the patients and their parents cannot be over emphasized. The management of

this deformity had been a puzzle for treating doctors for centuries.^(6,7,8,9) The Ponseti method of correction of clubfoot deformity has recently acquired the status of first line management.^(10,11) This study demonstrates the effective use of manpower and guided motivation to identify the cases and correction of the deformity in all the cases without the use of extensive procedure like posteromedial soft tissue release.

In our study, male to female ratio is 1.5:1 when compared to other similar studies which ranges from 2.33:1 to 2.5:1 done in various parts of the world.^(12,13) Few Indian studies showed that the ratio ranges from 2:1 to as high as 4:1^(14,15,16,17) The prevalence of laterality 44%(bilateral), 24%(right), 32%(left) was almost similar other study i-e 56%, 22% and 22%.⁽¹³⁾ The number of cast per feet in our study was four to seven (average 5.8), Other studies showed 4.9 to 7 casts.^(16,18,19,20) Of the children who presented to us, 60% (15 out of 25 babies) were below 4 months of age and 40% above suggesting poor referral system in our area and ignorance on the part of the parents.

In present study, good to excellent results were achieved in 92% of cases. Postero medial soft tissue release was avoided in all cases. Percutaneous tenotomy, which is an integral part of Ponseti method. Tenotomy was required in 72% of the cases (26 out of 36 feet) in our study which was higher compared to other studies.^(5,16,18) Complications such as severe bleeding due to injury to Peroneal artery after tenotomy was showed in a study which was done at Washington university but in our study we did not come across any such complication.⁽²¹⁾

2 cases had relapse of equinus deformity and tenotomy had to be repeated. 2 babies had developed pressure sores because of cast which healed uneventfully. Cast was delayed for 2 weeks. In most cases we believe that the reason for relapse was lack of compliance in keeping the foot in the DB splint for the required periods.

Conclusion

Ponseti method of clubfoot treatment is an excellent method as per our study. It avoids the surgical complications and gives a painless, mobile, normal looking functional foot which requires no special shoes and allows good mobility. In a developing country like India, where poverty and ignorance still have a say, a dearth of proper operative facilities in remote area, this technique is a very safe, easy, result-oriented, economical method of clubfoot management.

Conflict of Interest: None

Source of Support: Nil

References:

1. Canale & Beaty: Campbell's Operative Orthopaedics, 11th ed. Part VIII. Chapter 26:1079.
2. Lynn Staheli: Clubfoot - Ponseti Management 3rd ed. Global Help Organisation:4-5.

3. Canale & Beaty: Campbell's Operative Orthopaedics, 11th ed. Part VIII. Chapter 26:1083.
4. Ponseti IV, Campos J. The classic: observations on pathogenesis and treatment of congenital clubfoot. 1972. Clinical Orthopedics and Related Research 2009; 467(5):1124-32.
5. Pirani S, Outerbridge HK, Sawatzky B *et al*. A reliable method of clinically evaluating a virgin clubfoot evaluation. 21st SICOT Congress 1999.
6. Cummings RJ, Davidson RS, Armstrong PF *et al* Congenital Clubfoot. Journal of Bone and Joint Surgery 2002; 84-A: 290-308.
7. Cummings RJ, Lovell WW. Operative Treatment of Congenital Idiopathic Clubfoot. Journal of Bone and Joint Surgery 1988; 70-A: 1108-1112.
8. Ponseti IV. Treatment of Congenital Clubfoot. Journal of Bone and Joint Surgery 1992; 74-A: 448-454.
9. Ponseti IV. Congenital Clubfoot: Fundamentals of Treatment. Oxford Medical Publications, Oxford University Press, Oxford UK, 1996.
10. Abbas M, Qureshi OA, Jeelani LZ *et al*. Management of congenital talipes equinovarus by Ponseti technique: a clinical study. Journal of Foot and Ankle Surgery 2008; 47(6):541-5.
11. Cooper, D.M, Dietz F.R. Treatment of idiopathic clubfoot. A thirty year follow-up note. Journal of Bone and Joint Surgery 1995; 77A: 1477-89.
12. Turco V J. Resistant congenital club foot. One-stage posteromedial release with internal fixation. Journal of Bone and Joint Surgery 1979; 61-A: 805-814.
13. Kite JH .Principles involved in the treatment of congenital clubfoot. Journal of Bone and Joint Surgery 1939; 21:595-606.
14. Yamamoto H .A clinical, genetic and epidemiologic study of congenital clubfoot. Jinrui Idengaku Zasshi 1979; 24(1):37-44.
15. Chesney D, Barker S, Miedzbrodzka Z *et al* Epidemiology and genetic theories in the aetiology of congenital talipes equinovarus. Bulletin of the Hospital for Joint Diseases 1999; 58: 59-64.
16. Gupta.A, Singh.S, Patel.P *et al*. Evaluation of the utility of the Ponseti method of correction of clubfoot deformity in a developing nation. International Orthopaedics 2008; 32(1): 75-79.
17. Palmer RM. Genetics of talipes equinus varus. Journal of Bone and Joint Surgery American 1964; 46:542- 556.
18. Laaveg SJ, Ponseti IV. Long-term results of treatment of congenital clubfoot. Journal of Bone and Joint Surgery American 1980; 62(1):23-31.
19. Morcuende JA, Abbasi D, Ponseti IV *et al*. Results of an accelerated Ponseti protocol for clubfoot. Journal of Paediatrics Orthopaedics 2005; 25(5):623-626.
20. Morcuende JA, Dolan LA, Ponseti IV *et al*. Radical reduction in the rate of extensive corrective surgery for clubfoot using the Ponseti method. Paediatrics 2004; 113(2):376-380.
21. Dobbs MB, Gordon JE, Walton T *et al* .Bleeding complications following percutaneous tendoachilles tenotomy in the treatment of clubfoot Deformity. Journal of Paediatric Orthopaedics 2004; 24(4):353-357.