

Late presentation Subtrochanteric femur fracture in 12 year old child

Rajeev Shukla^{1,*}, Agrawal Utkarsh², Gurjar Abhishek³, Jain Ravikant⁴

¹Asst. Professor, ^{2,3}Final Year Post-graduate resident, ⁴Professor and HOD, Department of Orthopaedics, SAIMS, Indore, M.P., India

***Corresponding Author:**

Email: dr_rajeevshukla@rediffmail.com

Abstract

Background: Paediatric sub trochanteric femoral fractures are rare injuries with having limited attention received in the available literature. Different treatment options have been used for the treatment of sub trochanteric femur fractures like skin traction, skeletal traction, spica casting, cast bracing and internal fixation. Methods of internal fixation include: intramedullary nails and compression plating. This case report is about a 12 years old female child with late presentation of sub trochanteric femur fracture treated with Titanium Elastic Nailing system(TENS).

Method: A 12 years old female child presented to our Emergency with chief complaint of pain in right thigh along with inability to bear weight on her right lower limb following history of road traffic accident around 14 days back. On presentation her right lower limb was in abduction and external rotation and hip in flexion. Previous X-rays revealed undisplaced fracture sub trochanteric femur. She was managed conservatively on skin traction for 14 days at some other hospital before presenting to us. So repeat x-rays were done which revealed that fracture was displaced. So operative intervention planned and the fracture was fixed with three TENS Nails.

Results: Follow-up x-rays after 2 months showed good fracture healing and after 1 year showed complete union with pain free range of motion at hip and knee joints and no residual deformity.

Conclusion: Internal fixation with flexible intramedullary nailing appears as an excellent treatment option for sub trochanteric femoral fractures in children especially in age group of 6-12 years.

Keywords: Sub trochanteric femur fracture, late presentation, paediatric age group, Closed reduction and internal fixation, TENS.

Access this article online	
Quick Response Code:	Website: www.innovativepublication.com
	DOI: 10.5958/2395-1362.2016.00019.0

fracture, floating knee, vascular or neurological injuries, failure of conservative treatment, older child or adolescent and social indications^{5,6,7,8}. Methods of internal fixation include: intramedullary nails and compression plating^{5,7,9,10}

This case report is about a 12 years old female child with sub trochanteric femur fracture treated with Titanium Elastic Nailing system(TENS).

Introduction

Femoral fractures includes fractures of diaphysis, sub trochanteric and supracondylar region. They represent approximately 1.6% of all fractures in children 1. Paediatric sub trochanteric femoral fractures are though not so common but needs special attention^{2,3}. The sub trochanteric femoral fracture in children occurs 1 to 2cm below the lesser trochanter. The proximal fragment tends to flex, abduct and rotate externally⁴.

The treatment of sub trochanteric femoral fractures in children is controversial. Various treatment options are available which includes skin traction, skeletal traction, spica casting, cast bracing and internal fixation. The choice of treatment is influenced by child's age and size, economic concerns of the family, family's ability to care for a child with spica cast or external fixator, and the pros and cons of any operative procedure¹. Indications for operative treatment include multiple trauma, head injury, open

Material and Methods

A 12 years old female child presented to our Emergency department with chief complaint of pain in right thigh along with inability to bear weight on her right lower limb since 14 days. She had a history of Road traffic accident due to collision of 2-wheeler versus 4-wheeler around 14 days back. On presentation, her right lower limb was in abduction and external rotation and hip in flexion. She was managed conservatively on Thomas splint and skin traction at some other hospital for 2 weeks before patient came to our institute. Immediate post-trauma x-rays(Fig. 1) which were done at other hospital showed undisplaced sub trochanteric femur fracture. At our institute, repeat x-rays (Fig. 2) were done which showed displaced sub trochanteric femur fracture. Since reduction cannot be maintained in traction and Thomas splint, so operative intervention was planned. Under all aspectic precautions, closed reduction was done and the fracture was fixed with three TENS Nails (Fig. 3). Post-operatively she was

immobilised on derotation splint. Physiotherapy was started from post-operative day two. Sitting at edge of bed was started after 1 week and non-weight bearing mobilisation was started after 2 weeks. Partial weight bearing mobilisation was started after one month. Full weight bearing mobilisation was started after 2 months. Follow-up x-ray after 2 months showed good bone healing (Fig. 4) and after 1 year (Fig. 5) showed

complete union with pain free range of motion at hip and knee joints and no residual deformity (Fig. 6). At 1 year follow-up, TENS removal was planned. Patient was prepared for implant removal but we were unable to remove the implant most probably due to excessive callus deposition at the fracture site. So implant was left inside due to risk of re-fracture.

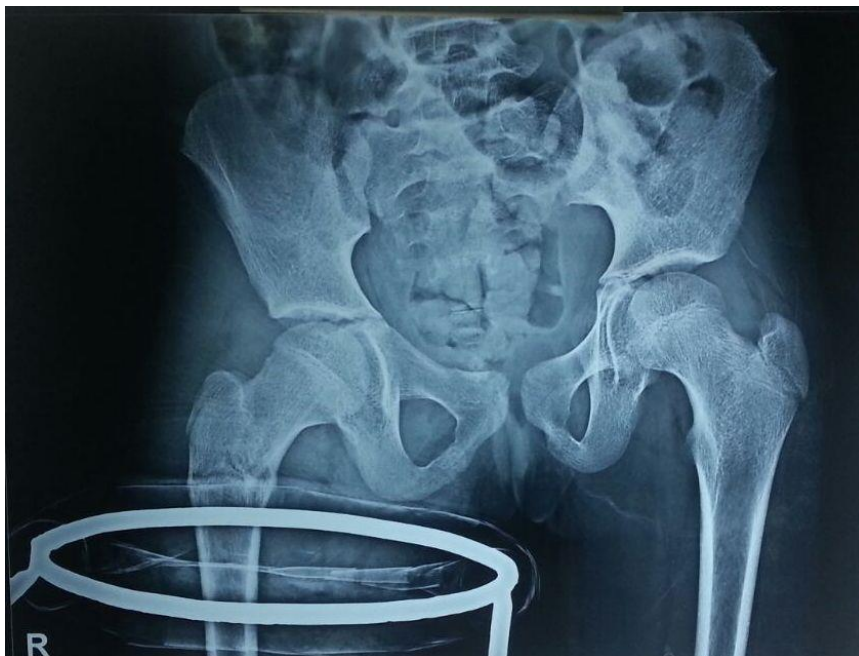

Fig. 1: Pre-operative x-ray of pelvis with both hip showing undisplaced Sub trochanteric femur fracture

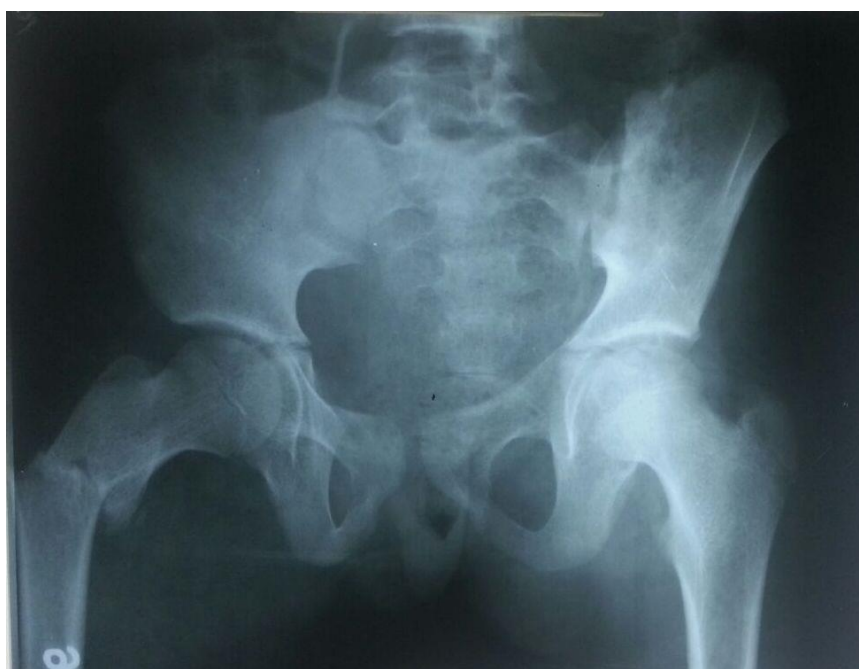


Fig. 2: Pre-operative x-ray at 2 weeks of pelvis with both hip showing displaced sub trochanteric femur fracture

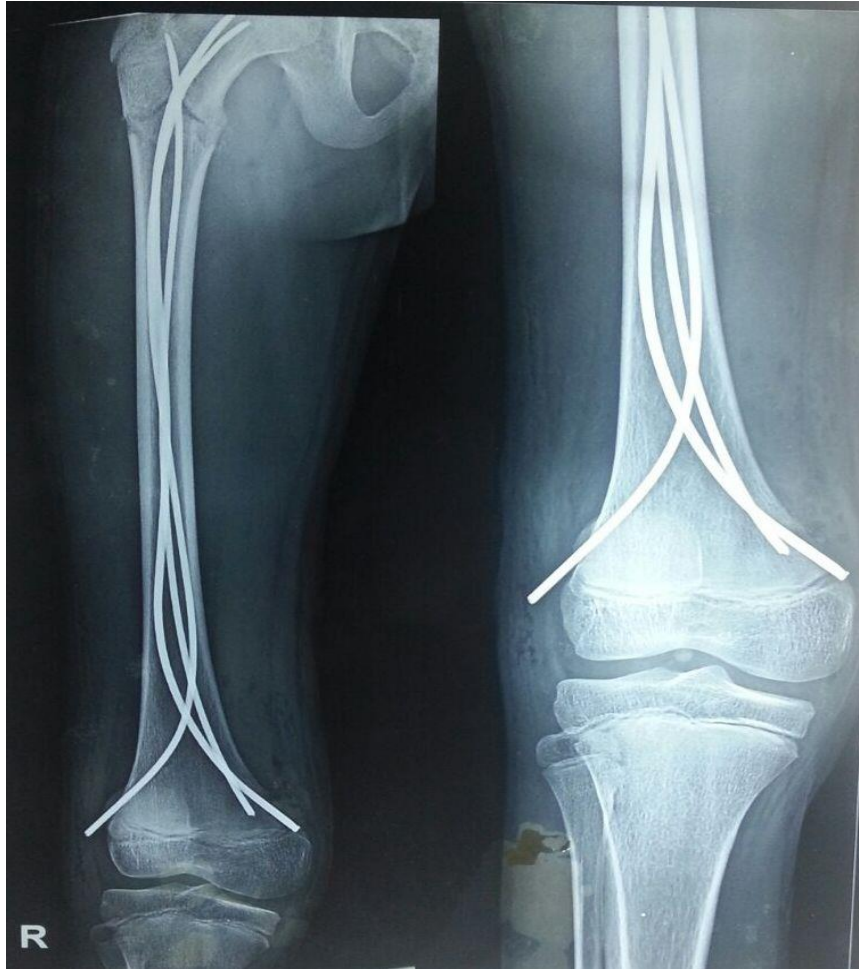

Fig. 3: Immediate post-operative x-ray of right hip with thigh showing sub trochanteric femur fracture fixed with 3 TENS nails

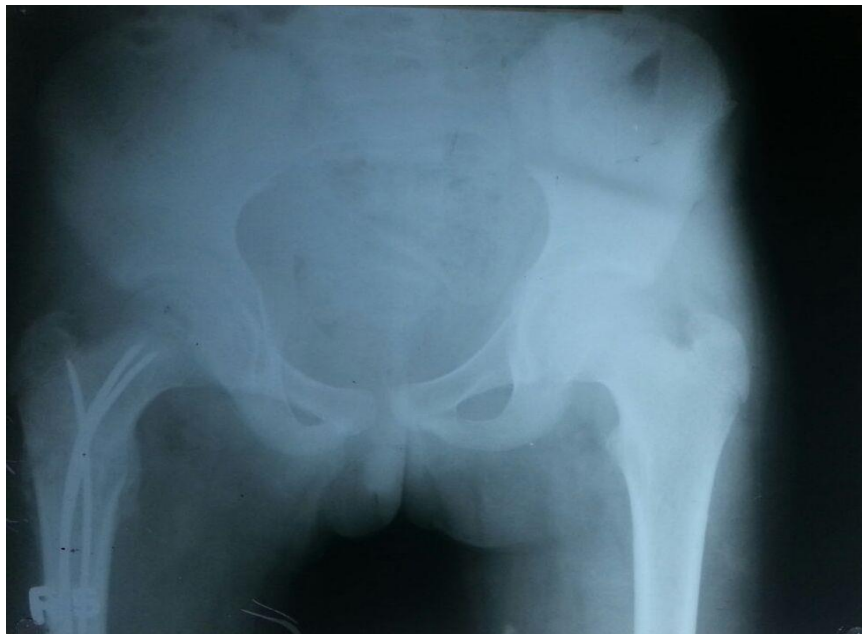


Fig. 4: Post-operative x-ray at 2 months of pelvis with both hip showing good callus formation with 3 TENS nails in place

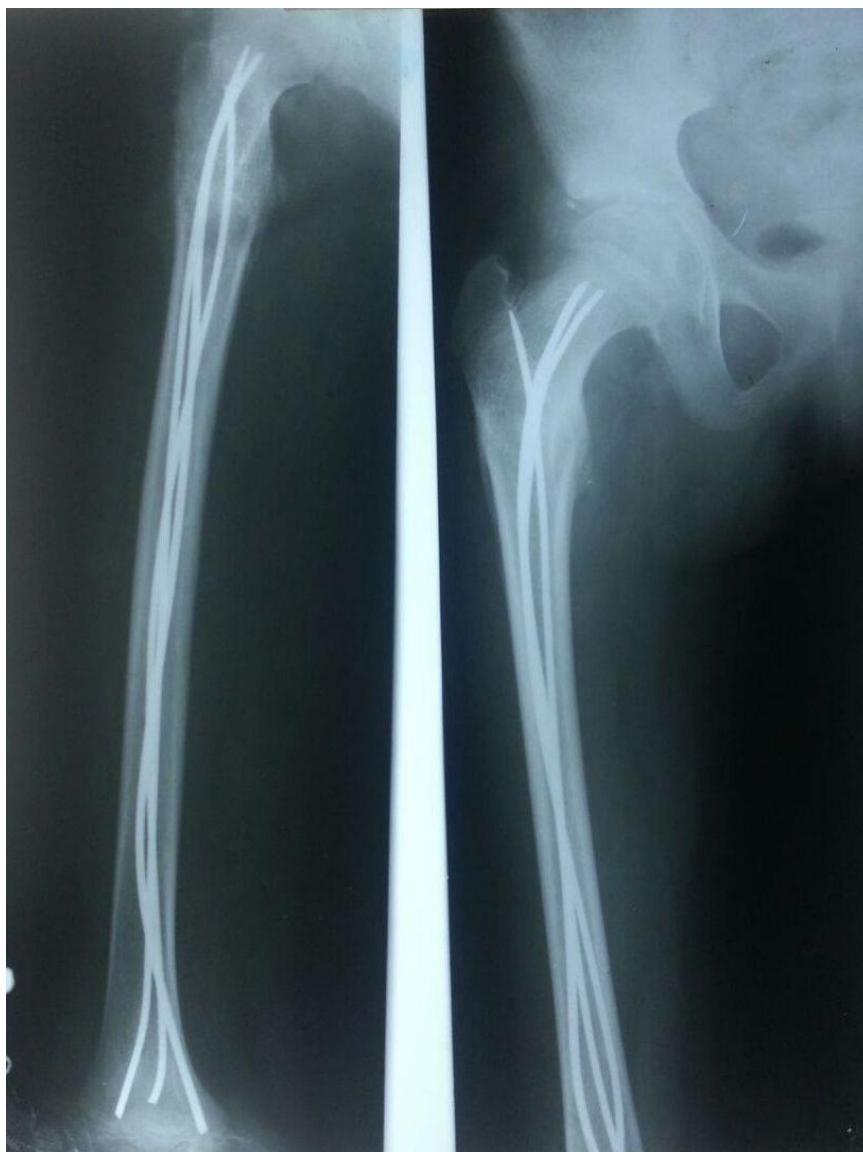

Fig. 5: Follow-up x-ray at 1 year of right hip with thigh showing good union



Fig. 6: Clinical Images at 1 year follow-up

Discussion

Sub trochanteric femoral fractures present a special unstable type of fracture which have received limited attention in the literature^{2,3}. The treatment for children

between the ages 6-12 years is controversial. Treatment options include traction followed by hip spica cast, immediate spica casting, cast bracing and internal fixation.

The preferred method by many surgeons for the treatment of children aged 6-10 years is traction followed by hip spica cast⁸. But this method is associated with few disadvantages like relatively long hospitalization and accurate control of fracture alignment with frequent radiographs and adjustment in traction as needed. Immediate spica casting has the advantage of its simplicity, low cost, and generally good results but Ferguson et al²² reported higher risk of failure of this technique in children more than 7 years of age. Internal fixation with plating is associated with a number of disadvantages like the need for plate removal, poor cosmetic scar, blood loss and higher degree of overgrowth induced by the plates compared with intramedullary fixation^{13,14}.

Flexible intramedullary nailing is now-a-days the treatment of choice in paediatric sub trochanteric femoral fractures. Advantages are patient is able to partially weight bear early, rapid fracture healing and a low incidence of malunion and non-union^{6,9,15,16,17}. Few disadvantages are lack of rotational stability and backing of implant¹⁵ but these can be overcome with slightly longer duration of immobilisation. Also, Intramedullary nailing has the disadvantage of subjecting the patient to second surgery for implant removal but the added advantage of nailing is low rates of infection, less blood loss, dissection and periosteal stripping.

Conclusion

Internal fixation with flexible intramedullary nailing appears as an excellent treatment option for subtrochanteric femoral fractures in children especially in age group of 6-12 years.

Source of Support: No support or funding has been received for this research in any form from any organization.

Conflict of Interest: The authors declare that they have no conflicts of interests.

References

1. Kasser JR, Beaty JH. Femoral shaft fractures. In: Beaty JH, Kasser JR eds. Rockwood and Wilkins, Fractures in Children, 6th ed: Lippincott Williams and Wilkins; 2006;Vol 3,pp 894-936.
2. DeLee JC, Clanton TO, Rockwood CA Jr. Closed treatment of subtrochanteric fractures of the femur in a modified cast brace. J Bone Joint Surg 1981;63-A:773-779.
3. Ireland DC, Fisher RL. Subtrochanteric fractures of the femur in children. Clin Orthop 1975;110:157-166.
4. Staheli LT. Fractures of the shaft of the femur. In: Rockwood CA Jr., Wilkins KE, and King RE eds. Fractures in Children, 3rd ed.: Lippincott; 1991,Vol 3B,pp 1121-1163.
5. Kregor PJ, Song KM, Routt MLC et al. Plate fixation of femoral shaft fractures in multiply injured children. J Bone Joint Surg 1993;75-A:1774-1780.
6. Ligier JN, Metaizeau JP, Prevot J et al. Elastic stable intramedullary nailing of femoral shaft fractures in children. J Bone Joint Surg 1988;70-B:74-77.
7. Miner T, Carrol KL. Outcomes of external fixation of pediatric femoral shaft fractures. J Pediat Orthop 2000;20:405-410.
8. Tolo VT. Treatment of fractures of the long bones and pelvis in children who have sustained multiples injuries. J Bone Joint Surg 2000;82-A:272-280.
9. Flynn JM, Hresko T, Reynolds RA et al. Titanium elastic nails for pediatric femur fractures: a multicenter study of early results with analysis of complications. J Pediat Orthop 2001;21:4-8.
10. Fyodorov I, Sturm PF, Robertson WW Jr. Compression plate fixation of femoral shaft fractures in children aged 8 to 12 years. J Pediat Orthop 1999;19:578-581.
11. Reeves RB, Ballard RI, Hughes JL. Internal fixation versus traction and casting of adolescent femoral shaft fractures. J Pediat Orthop 1990;10:592-595.
12. Humberger FW, Eyring EJ. Proximal tibial 90-90 traction in treatment of children with femoral shaft fractures. J Bone Joint Surg 1969;51-A:499-504.
13. Ziv I, Blackburn N, Rang M. Femoral intramedullary nailing in the growing child. J Trauma 1984;24:432-434.
14. Ziv I, Rang M. Treatment of femoral fractures in the child with head injury. J Bone Joint Surg 1983;65-B:276-278.
15. Buechsenschuetz KE, Mehlman CT, Shaw AH et al. Femoral shaft fractures in children: traction and casting versus elastic stable intramedullary nailing. J Trauma 2002;53:914-921.
16. Kissel EU, Miller ME. Closed Ender nailing of femur fractures in older children. J Trauma 1989;29:1585-1588.
17. Oh CW, Park BC, Klim PT et al. Retrograde flexible intramedullary nailing in children's femoral fractures. Int Orthop 2002;26:52-55.