

A comparison of surgical outcome between modified external dacryocystorhinostomy with endoscopic endonasal dacryocystorhinostomy

Ankita Mahendra Kabra^{1,*}, Archana Sunil Nikose², Arpita Sthapak³, Rachana Kabra⁴

^{1,3}Junior Resident, ²Associate Professor, N.K.P. Salve Institute of Medical Sciences & Research, Maharashtra

⁴Senior Resident, L.V. Prasad Eye Institute, Telangana

***Corresponding Author:**

Email: ankitakabra49@gmail.com

Abstract

Purpose: A comparison of surgical outcome between modified external dacryocystorhinostomy with endoscopic endonasal dacryocystorhinostomy.

Methods: This was a prospective, randomized, interventional study on 84 patients with chronic dacryocystitis. They were divided into two groups; one group underwent modified external dacryocystorhinostomy whereas another group underwent an endoscopic endonasal dacryocystorhinostomy. Follow up period was six months and were evaluated on the basis of sac syringing and Munk's score. The patients were followed up postoperatively on 1st day, 7th day, 1st month, 3rd month and 6th month. Statistical analysis was done by chi square test.

Results: The mean age of the patients in our study in group I was 49.51 ± 5.08 SD years and group II was 44.00 ± 8.11 SD years. The female patients were more in both groups. Surgical success depends upon creating a wide osteotomy and preservation of mucosa around the bony ostium to reduce the chances of post-operative scarring and stenosis and defined on the basis of patency of sac on syringing and improvement in Munk's score at the end of six months. The overall success rate of external dacryocystorhinostomy was 92.50% and that of endoscopic endonasal dacryocystorhinostomy was 75.67% and the difference was statistically significant ($P = 0.02$, $P < 0.05$).

Conclusion: Primary procedures of the surgeries, external dacryocystorhinostomy and EN-DCR have almost comparable success rates. The minimal differences in outcomes between the two techniques are due to advances in technology of endoscopic endonasal dacryocystorhinostomy, experience of the surgeon and patient characteristics.

Keywords: Modified external dacryocystorhinostomy, Endoscopic endonasal dacryocystorhinostomy, Lacrimal sac syringing, Munks score, Hypertrophic scar, Obstruction at rhinostomy site

Introduction

“There is no such thing as weeping for joy” goes a very famous saying. A tear can mean anything like sorrow, elation, emotion, awe or pleasure, laughing or yawning. It can be healthy or pathological. A persistent tearing is, however, a pathological feature.

Normal drainage of the tear is from the conjunctival sac into the inferior meatus of the nose through the nasolacrimal passage. Inflammation of the lacrimal sac is termed as dacryocystitis. It can be congenital or acquired, the later is further classified as acute and chronic¹. Obstruction can be due to inflammation, scarring, trauma or neoplasm². Nasal duct lower end obstruction may be caused by nasal polyp, hypertrophied inferior turbinate or extreme deviation of the nasal septum, which leads to various grades of epiphora. Accumulation of the secretions and tears in the sac can easily get infected by presence of bacteria like

staphylococci, pneumococci, streptococci from the conjunctival flora¹.

Dacryocystitis never undergoes spontaneous resolution³ and hence, almost always requires surgery for correction of the block. Dacryocystorhinostomy (DCR) is a procedure in which lacrimal flow is diverted in the nasal cavity by making an opening at the level of lacrimal sac. This surgical procedure can be carried out by either an external approach or endoscopic endonasal approach⁴.

External dacryocystorhinostomy (EXT-DCR) is well established as the standard surgical procedure for the treatment of complete nasolacrimal duct obstruction (NLDO) in adults⁵. This initial procedure was modified by Dupuy-Dutemps and Bourguet in 1921, in which the lacrimal sac was incised to form anterior and posterior flaps and then sutured to nasal mucosa⁶. EXT-DCR is the gold standard because it has major

advantage of higher success rate ranging from 90% to 95%⁷. It is easier to master the surgical technique and requires lesser capital equipment costs as compared to the endoscopic endonasal dacryocystorhinostomy (EN-DCR)⁸. However, external dacryocystorhinostomy has got certain disadvantages like facial scar, altered physiological lacrimal pump mechanism, longer surgical time, bleeding during the surgery, disturbed medial canthus ligament and sometime persistent pain⁹.

It was Caldwell in 1893 who first described endonasal approach by fiberoptic endoscope¹⁰ which was later developed by West in 1910⁹. EN-DCR has minimal blood loss and is cosmetically more acceptable as it avoids scar¹¹. Also, it is more physiological as it preserves the lacrimal pump mechanism. Disadvantages of EN-DCR are small rhinostomy size, lesser success rates, more expensive equipment's and a steep learning curve¹².

In our study, we attempt to compare the procedure, complications and surgical outcome between modified external dacryocystorhinostomy and endoscopic endonasal dacryocystorhinostomy.

Material and Methods

A hospital based prospective interventional comparative randomized control trial of 84 patients was conducted in a rural based tertiary care center. Group I had 43 patients and group II had 41 patients. This study was carried out from September 2013 to August 2015. Patients were selected from the Ophthalmology & ENT outpatient department randomly by a computer generated sheet. Patients complaining of epiphora and diagnosed as acquired NLDO were included in the study. The study protocol, patient information sheet and consent form was approved by the Institutional ethics committee and followed the tenets of Helsinki. Written informed consent was obtained from all patients.

All patients with aged above 18 years and both sexes were included in the study. A detailed history and a complete ocular examination were done in all cases. All patients were subjected to nasal examination to rule out any nasal pathology. The exclusion criteria were patients less than 20years, those who had previous lacrimal sac surgery, any nasal or bony deformities, post traumatic sac area, external lacrimal fistula and failed DCR cases. Patients with common cannicular block were also not included. All patients underwent preoperative sac syringing to find out the site of a block. Patients were asked to quantify the epiphora by asking them

the number of times they require to wipe their eyes and Munk's score was noted. Clinical classification of epiphora based on Munk's score¹³⁻¹⁴ is as follows-

Grade	Description
1.	No epiphora
2.	Occasional epiphora once or twice a day
3.	Epiphora 2-4 times a day
4.	Epiphora 5-10 times a day
5.	Epiphora >10 times a day

Surgical technique: All patients underwent the surgical procedure under local anesthesia. The nasal cavity of the side to be operated was packed with gauze soaked in xylocaine jelly 2% and an ampoule of adrenaline 1:100,000. The nasal packing was effective for decongestion and analgesia of the nasal mucosa.

A precise incision site was found to be very important for a blood less and better exposure of the surgical field. A vertical skin incision about 14-16mm was given medial to the medial canthus above the medial canthal ligament avoiding the angular vein. Dissection of the periosteum was carried out using periosteal elevator. Angular vessels were avoided, and were cauterized whenever was necessary. The wound was opened with four traction sutures. The subcutaneous tissue and orbicularis muscle fibres were separated with artery forceps and then with blunt dissector. Medial palpebral ligament was identified, exposed and excised at its mid-part. A periosteal (Cottle or Freer) elevator was used to reflect the periosteum and the superficial (anterior) head of the medial canthal tendon. The lacrimal sac was encountered and was carefully reflected laterally exposing the fossa. A natural point of weakness was present at the juncture of the frontal process of maxillary and lacrimal bone within the lacrimal fossa. Firm pressure of the periosteal elevator was frequently sufficient to fracture the bone and start the bony ostium. The osteotomy was then enlarged using various sized Citelli punch. The osteotomy was made approximately 10-12 mm in size (Fig. 1). Oozing of the blood was controlled by packing with gauze moistened with 2% Xylocaine jelly with adrenaline.

The puncta were then dilated. A Bowman probe was passed into the lacrimal sac and used to tent up the lacrimal sac wall. With the help of a Bard Parker 11 no. blade, lacrimal sac was opened in „I” shaped fashion to form large anterior flap and smaller posterior flaps of medial wall of lacrimal

sac. A periosteal elevator was passed into the naris and was used to tent up the nasal mucosa. A 11 no. Bard-Parker blade was used to incise the nasal mucosa in a line parallel to the lacrimal sac incision (single 'U' shaped nasal mucosal flap).

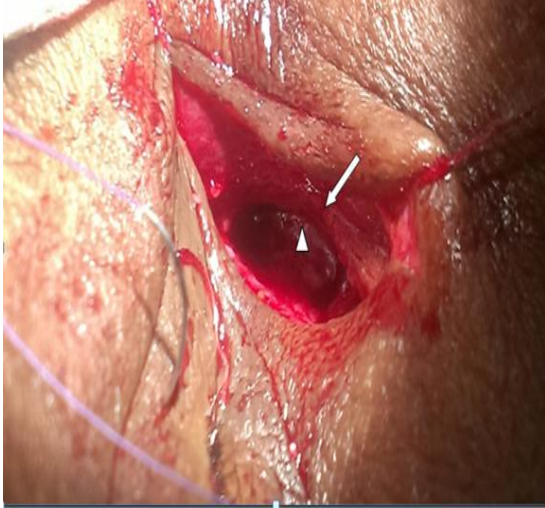

Fig. 1: Large osteotomy (white arrow) extending superiorly slightly above level of medial palpebral ligament, inferiorly till the level of inferior orbital margin and posteriorly upto lamina papyracea. Posterior to the ostium nasal mucosa (white arrowhead) is seen

The posterior flap of the lacrimal sac was excised. The anterior lacrimal sac and mucosal flaps were then sutured using 5-0 polyglactin suture. 5-0 polyglactin suture was also used to reconstitute the anterior crus of the medial canthal tendon which was detached during the initial dissection. The wound was closed in layers in which subcutaneous tissue was sutured by 5-0 polyglactin suture. Skin was approximated by continuous subcutaneous sutures with 6-0 polypropylene.

Antibiotic drops were instilled into the eye, antibiotic ointment was applied to the operated site and dressing was done. Any complications during the surgery like bleeding, damage to lacrimal sac, damage to nasal mucosa and damage to orbital structures were noted and treated accordingly.

In endoscopic endonasal dacryocystorhinostomy, nasal pack was removed; 0° Storz Hopkins endoscope was introduced into the nasal cavity and whole of the nasal cavity was visualized. The mucosa of the lateral nasal wall was infiltrated with 2% xylocaine with 1:2,00,000 adrenaline just anterior to the uncinat process and anterior to the attachment of middle turbinate and into the middle turbinate.

An incision was made in lateral wall of nose with sickle knife. Starting just anterior to axilla of middle turbinate and proceeded in forward direction for 0.5-0.7cm then vertically downward for 1.25cm and thereafter it proceeded posteriorly. Mucosal flap was then elevated medially and removed with straight Blakesley's forceps from the bone in posterior direction until base of the uncinat process was reached. The bone underlying the flap constitutes of anterior lacrimal crest of the maxilla anteriorly and lacrimal bone posteriorly.

At this junction, lacrimal bone, which was papery thin, was nibbled with 2mm Kerrison's punch and edges were smoothed with electric drill (Fig. 2). Lacrimal part of the fossa was removed upto the base of uncinat process carefully in postero-lateral part, thus about 7×8 mm of bone was removed to expose medial wall of the sac. Lacrimal sac was confirmed endoscopically by putting pressure over the lacrimal sac from outside at the medial canthus, bulging of sac was noticed intranasally.

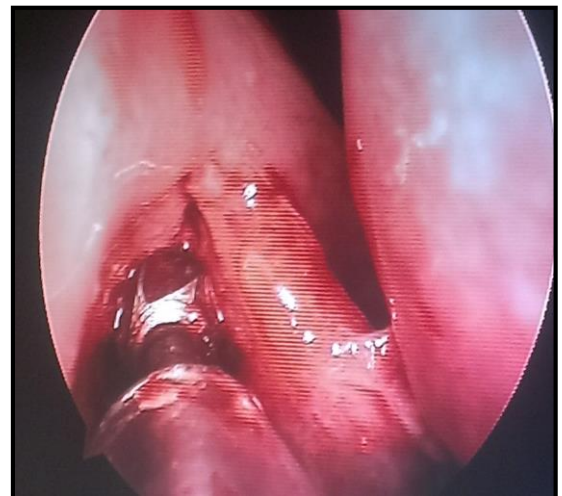

Fig. 2: Enlarging and smoothing of the ostium with electric drill

If still some doubt persisted about correct identification of the sac, externally eye was anaesthetized with 2% xylocaine drops, upper punctum was dilated with punctum dilator. Bowman's probe was inserted into the superior canaliculus and directed against the medial wall of the lacrimal sac in order to tent it intranasally. With sickle knife, the tented mucosa of the sac was incised immediately, and serous or muco-purulent discharge coming out of the sac was noticed. Then with a special right angled true cut forceps or with

Blakesly's forceps, infero-medial wall of the sac was removed.

With the help of suction tip, muco-purulent discharge or blood was removed, then lacrimal sac syringing was done with diluted methylene blue dye from outside by the assistant and free flow of the methylene was observed endoscopically.

Medicated nasal packing was done with gauze piece soaked with Neosporin ointment. Any complications during the surgery bleeding, damage to lacrimal sac, damage to nasal mucosa and damage to orbital structures were noted and treated accordingly.

Postoperatively, all patients were given systemic antibiotics and analgesics for 5 days. Antibiotic eye drops were advised 4 times daily for 15 days. Nasal pack was removed after 24 hours in most cases and if required fresh nasal packing was done and kept for next 24 hours.

In case of group I patients, dressing was removed after 24 hours and sutures were removed on 7th post-operative day. In case of group II patients, after removing nasal packing after 24 hours, patients were advised to instil nasal decongestant drops 3 times a day for 5 days, 2 times a day for next 5 days and 1 times a day for next 5 days. Lacrimal sac syringing was done on 1st post-operative day in both the groups. Most of the patients were discharged after 2-4 days of hospitalization and called for regular follow up at 1st week, 1st month, 3rd month and 6th month post-operatively.

Results

Demography: The mean age of the patients in our study in group I was 49.51 ± 5.08 SD years and group II was 44.00 ± 8.11 SD years (Figure 3). Female preponderance was seen in both groups, group I had 25 cases (58.139%) and group II 27 cases (65.853%). The male to female sex ratio being 0.6:1. 55 (65.47%) of the 84 patients were affected on the left side while 29 (34.52%) the patients were affected on the right side.

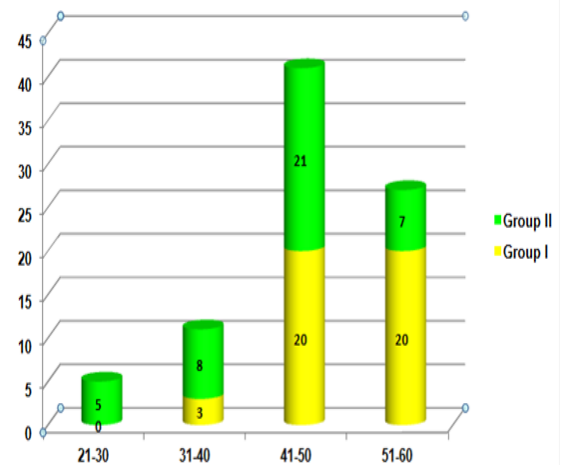


Fig. 3: Graph of age distribution in the two study groups

Intra-operative complications: The surgical procedure was uneventful in 32 patients (74.41%), nasal flap laceration occurred in 3 (6.97%), damage to lacrimal sac in 2 patients (4.65%) and intraoperative hemorrhage in 6 (13.95%) in group I whereas in group two it was uneventful in 37 patients (90.24%), nasal flap laceration was seen in 1 patient (2.43%), damage to lacrimal sac in 1 patients (2.43%) and excessive hemorrhage in 2 patients (4.87%) (Fig. 4).

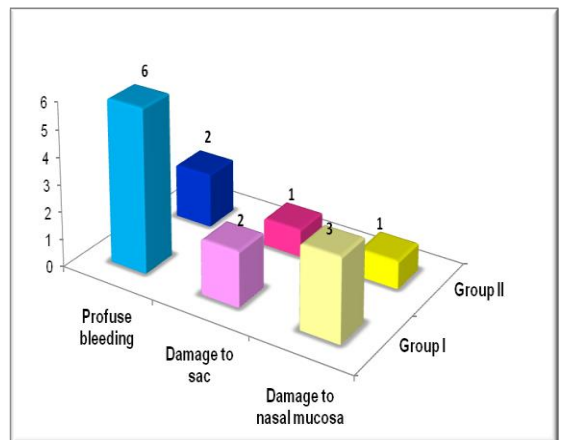


Fig. 4: Chart showing distribution of intra-operative complications in the two study groups

Post-operative complications: 7 (16.27%) of Group I patients had lid oedema on 1st post-operative day while 1 patient (2.32%) had delayed wound healing one week after surgery. Hypertrophic scar was observed in 6 patients (13.95%) at 4th week of follow up. 2 patients (4.65%) presented with obstruction at the rhinostomy site at 3rd month of follow up (Table

1).

Table 1: Post-operative complications in group I

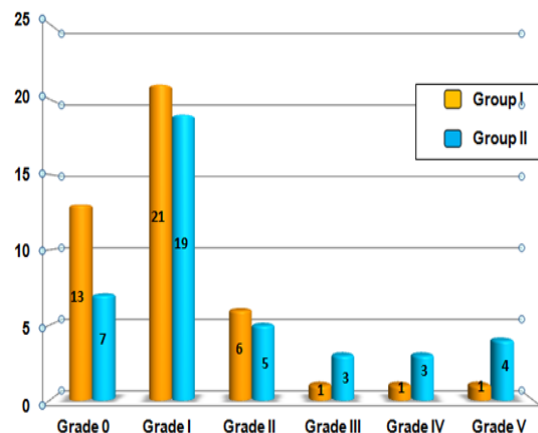
Complication	No. of Cases	Percentage %
Lid oedema	7	(16.27%)
Delayed wound healing	1	(2.32%)
Hypertrophic Scar	6	(13.95%)
Obstruction at rhinostomy site	2	(4.65%)

In group II, lid oedema was present in 1 patient (2.43%) while 2 patients (4.87%) had bleeding per nose on 1st post-operative day. On follow up, late complications were - 3 patients (7.31%) had delayed wound healing; 3 (9.75%) and 5 (12.19%) presented with synechiae formation and obstruction at rhinostomy site respectively (Table 2).

Table 2: Post-operative complications in group II

Complication	No. of Cases	Percentage %
Lid oedema	1	(2.43%)
Epistaxis	2	(4.87%)
Delayed wound healing	3	(7.31%)
Synechiae formation	3	(9.75%)
Obstruction at rhinostomy site	5	(12.19%)

Munk's score: Epiphora was found to be more in group II than group I in our study group. 20 (23.80%) of the 84 patients had grade 0 Munk's score, out of which 13 patients (30.23%) were from group I and 7 (17.07%) were from group II. 40 (47.61%) patients had grade 1 Munk's score- 21 (48.83%) were from group I and 19 (46.34%) were from group II. Grade 2 Munk's score was seen in 6 (13.95%) patients of group I and 5 (12.19%) of group II. In group I, out of the remaining patients, 1 patient each had grade 3, grade 4 & grade 5 Munk's score. In group II similar number of patients i.e. 3 patients (7.31%) were observed in grade 3 and 4. 4 patients (9.75%) were present in grade 5 (Fig. 5).

**Fig. 5: Chart showing post-operative grading of epiphora (Munk's Score) in the two study groups**

Munk's score of the group I was 1.04 with SD of 1.06 and that of group II was 1.78 with SD of 1.62 on 30th post-operative day. There was significant difference between the Munk's score of group I and group II on 30th day ($P = 0.01$, $P < 0.05$).

Sac syringing: Figure 6 shows in group I, 42 (97.67%) cases out of 43 were patent on 1st post-operative day, while 41 (95.34%) cases were patent at 1st post-operative week. At 1st month 40 (93.02%) cases were patent, out of total of 43 patients. At 3rd month follow up, there was a drop out of 2 patients, so out of 41 patients 38 (92.68%) had patent NLD. 3 patient dropped out of study at 6 months follow up. Sac syringing revealed patent NLD in 37 (92.50%) out of 40 patients.

In group II, 40 (97.56%) cases out of 41 were patent on 1st post-operative day, while 38 (92.68%) were patent at 1st post-operative week. 31 (75.60%) cases out of 41 were patent at 1st month. 3 patients dropped out at the end of 3 months. Out of 38 remaining patients patency was noted in 29 (76.31%) patients.

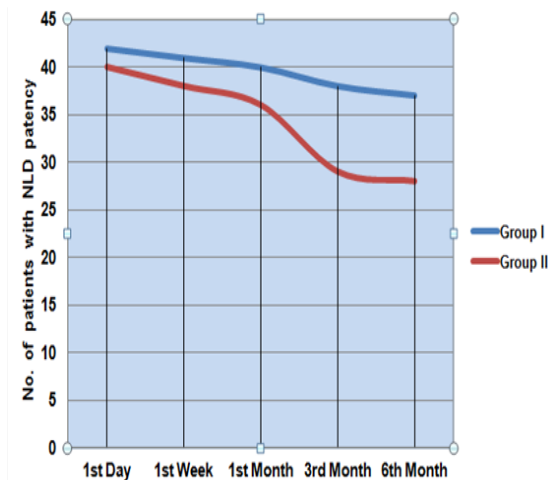


Fig. 6: Graph showing post-operative evaluation by sac syringing in the two study groups

At the end of 6th month 4 patients did not come for the follow up. NLD patency was observed in 28 patients of the remaining 37 patients. Thus, anatomical patency and symptom relief was higher in group I patients as compared to group II. This difference was statistically significant at 3rd and 6th months of follow up ($P = 0.04$, $P < 0.05$).

Success rate: In group I, 42 (97.67%) cases out of 43 were patent on 1st post-operative day, while 41 (95.34%) cases were patent at 1st post-operative week. At 1st month 40 (93.02%) cases were patent, out of total of 43 patients. At 3rd month follow up, there was a drop out of 2 patients, so out of 41 patients 38 (92.68%) had patent NLD. 3 patient dropped out of study at 6 months follow up. Sac syringing revealed patent NLD in 37 (92.50%) out of 40 patients.

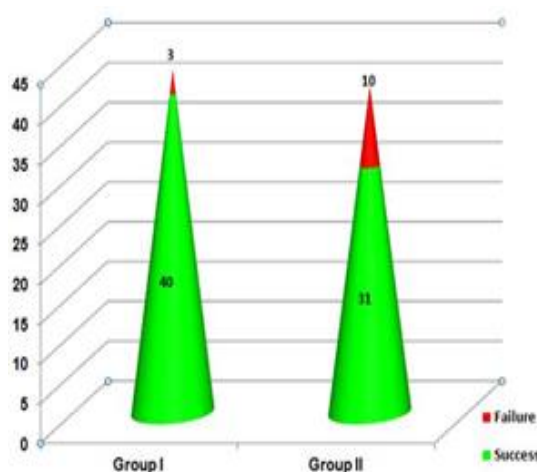


Fig. 7: Figure showing comparison of success rate in the two study groups

In group II, 40 (97.56%) cases out of 41

were patent on 1st post operative day, while 38 (92.68%) were patent at 1st post-operative week. 31 (75.60%) cases out of 41 were patent at 1st month. 3 patients dropped out at the end of 3 months. Out of 38 remaining patients patency was noted in 29 (76.31%) patients. At the end of 6th month 4 patients did not come for the follow up. NLD patency was observed in 28 patients of the remaining 37 patients. Thus, anatomical patency and symptom relief was higher in group I patients as compared to group II. This difference was statistically significant at 3rd and 6th months of follow up ($P = 0.04$, $P < 0.05$).

Discussion

Dacryocystitis is a very common affection sparing no specific age group. Epiphora is an annoying symptom of dacryocystitis and NLDO, embarrassing the patient both socially and functionally. Obstruction of NLD can be approached either externally or endonasally.

In both modified EXT-DCR and EN-DCR groups, 48.80% of cases were between the age group of 41-50 years followed by 32.14% cases in the age group of 51-60 years. The mean age of our study was 49.51 ± 5.08 years in group I and 44.00 ± 8.11 years in group II. The maximum incidence was seen in 4th and 5th decade of life. In the recently conducted study by **Acharya Ishan et al in 2015**, titled 'transition to external to endoscopic endonasal dacryocystorhinostomy: learning curve of an oculoplasty surgeon', the mean age of the patients in EXT-DCR as well as EN-DCR was 43.8 ± 20.2 years¹⁵. In the retrospective study of **Jha K. N, et al in 2009**, comparison of EXT-DCR versus EN-DCR, 53.4% patients belonged to the age group of 41-60 years².

The number of females undergoing surgery was much higher than the male in our study. Out of 84 patients 32 (38.09%) were male and 52 (61.90%) were female. **Tonuzi O et al in 2015** conducted a comparative study of EXT-DCR and EN-DCR and found that number of female patients were 57% more than male 43%¹⁶. In another recent prospective study by **Gupta M et al in 2015**, a comparison of EN-DCR and EXT-DCR also noticed that females outnumbered the males. Ratio of male to female was 1:3 and 1:4¹⁷.

In our study of total 84 patients, 26 patients (34.52%) had involvement of the right eye and 55 patients (65.47%) of the left eye. **Telang R. et al in 2015** carried out a study of EN-DCR with mucosal flap technique. In their study, the percentage of

patients having right eye involvement was 42% (21 patients) and left eye involvement was 58% (29 patients)¹⁸. Similarly, **Singh H et al in 2015** in their comparative study of EN-DCR and EXT-DCR found that right eye involvement in the study was 32% whereas left eye involvement was 54%. Rest 14% cases had bilateral involvement¹⁹.

Intra-operative complications that occurred in our study were excessive bleeding, damage to sac and damage to nasal mucosa. Excessive bleeding was seen in 8 patients (9.52%) in which 6 (13.95%) patients were from external and 2 (4.87%) patients were from endoscopic endonasal group ($P = 0.1$, >0.05). Major difficulty which was encountered in group I was bleeding that hampered visualisation. Profuse bleeding was caused during skin incision due to injury to the angular vein, during punching of the lacrimal bone or while making an incision on the nasal mucosa. The bleeding was stopped by placing a guaze soaked in dilute adrenaline at the site of bleeding.

Other intraoperative complications were damage to sac and damage to nasal mucosa. 2 patients (4.65%) in group I and 1 patient (2.43%) in group II had damage to the sac whereas 3 patients (6.97%) from group I and 1 (2.43%) from group II had damage to nasal mucosa ($P = >0.05$). **Nailwal S et al in 2015**, conducted a prospective comparison study of external and endoscopic dacryocystorhinostomy and noticed that moderate bleeding was present in 23.33% patients of the EXT-DCR group and in 16.67% patients of endonasal group. Tearing of anterior nasal flap was seen in external group in 6.67% of the patients. 3.33% of the patients in endonasal group had accidental entry into ethmoidal air cells and trauma to the middle turbinate during the surgery. Difficulty in making a bony window was seen in 6.67% patients of endonasal group²⁰. **Gaubha V et al in 2014**, in prospective study on external versus endonasal dacryocystorhinostomy in a specialized lacrimal surgery centre noticed that intra-operative hemorrhage was seen in 18% patients in EXT-DCR and in 13% patients in EN-DCR²¹.

In our study, 16 out of 43 (37.20%) patients operated by EXT-DCR and 14 out of 41 (34.14%) patients operated by EN-DCR had post-operative complications. But difference is not statistically significant ($P = 0.43$, >0.05).

Success rate was defined by symptomatic relief of epiphora and presence of sac patency on subsequent follow up on 1st day, 1st week, 1st month, 3rd month and 6th month post-operatively. On mean

follow up of 6 months, improvement was noted in epiphora of both the groups. Epiphora, if present, was graded using Munk's score. The mean Munk's score in EXT-DCR was 1.04 ± 1.06 SD and in EN-DCR was 1.78 ± 1.62 SD and the difference was statistically significant ($P = 0.01$, $P < 0.05$).

Of the 43 patients in group I, 40 completed follow up for 6 months and 3 patients dropped out of the study. At the end of 6 months, 37 patients (92.50%) had patent NLD and sac. 3 patients had blocked NLD on syringing after 6 months of follow up and were advised to undergo revision EN-DCR. Out of 41 patients in group II, 37 patients came for regular follow up for 6 months and 4 patients lost to follow up. At the end of 6 months, 28 cases (75.67%) were having patent NLD and sac on syringing. 9 patients who were having block NLD on sac syringing after 6 months of follow up were advised to undergo revision EN-DCR. So, the success rate of EXT-DCR as compared to EN-DCR is higher and the difference is statistically significant ($P = 0.02$, $P < 0.05$). **Gupta M et al in 2015**, in their prospective comparison study of EN-DCR and EXT-DCR, conducted on 40 patients, noticed that the success rates of EN-DCR and EXT-DCR were 80% and 90% respectively ($P > 0.05$)¹⁷. **Khan MKH et al in 2011**, compared EN-DCR and EXT-DCR for the treatment of chronic dacryocystitis in 30 patients. They found that the success rate was 73.3% with endoscopic approach and 80% with external approach¹.

In all the above discussed studies, the success rate in EXT-DCR is reported to be better than in EN-DCR which is commensurate with our study. From this discussion we can say that patency of the NLD (sac syringing) and symptomatic relief is the ultimate goal of dacryocystorhinostomy and we observed better success rate with external approach than endoscopic endonasal approach in dacryocystorhinostomy technique.

Author disclosure statement: The authors have no financial involvement, financial interest or financial conflicts.

References

1. Khan MKH, H.M., Hossain MJ, Al-Masud A, Rahman MZ, Comparative study of external and endoscopic endonasal dacryocystorhinostomy for the treatment of chronic dacryocystitis. JAFMC, 2011.7(2):p.15-17.
2. Jha K.N, R.W., External Versus Endoscopic Dacryocystorhinostomy. MJAFI, 2009.65(1):p.23-25.
3. Silhota R, T.R., Parson's Diseases of the Eye. 21 ed. 2011, New Delhi: Elsevier.

4. Jokinen K, K.J., Endonasal dacryocystorhinostomy. Arch Otolaryngol, July 1974.100:p.41-44.
5. Delaney YM, K.R., External dacryocystorhinostomy for the treatment of acquired partial nasolacrimal obstruction in adults. British journal of ophthalmology, 2002;86:533-5.86: p.533-5.
6. Gazmend Kacaniku, Iiir Begolli. External Dacryocystorhinostomy: with and without suturing the posterior mucosal flaps. Med Arh.2014;68:54-56.
7. Mirza S, A.B.A., Douglas SA, Bearn MA, Robson AK, A retrospective comparison of endonasal KTP laser dacryocystorhinostomy versus external dacryocystorhinostomy. Clin Otolaryngol, 2002Oct(27):p.347-51.
8. Kacaniku G, S.K., Hoxha G et al, Anterior flaps anastomosis in external dacryocystorhinostomy. MED ARH, 2011.65(1):p.32-34.
9. Saroj Gupta, R.G., A S Thakur, Harpal Singh, Conventional dacryocystorhinostomy versus endonasal dacryocystorhinostomy - A comparative study. People's journal of unscientific research, 2008.1.
10. Woog JJ, K.R., Custer PL, Kaltreider SA, Meyer DR, Camara JG, A Endonasal dacryocystorhinostomy Report American academy of ophthalmology, 2001. Dec:108:p.2369-77.
11. PJ, D., Comparison of external dacryocystorhinostomy with nonlaser endonasal dacryocystorhinostomy. Ophthalmology, 2003 Jan(110):p.78-84.
12. Mohammad etezad razavi, M.N., Alireza Eslampoor, Non-endoscopic mechanical endonasal dacryocystorhinostomy. Journal of ophthalmic and vision research, 2011.6(No.3):p.219-224.
13. 13 Munk PL, Lin DT, Morris DC. Epiphora: treatment by means of dacryocystoplasty with balloon dilatation of the nasolacrimal drainage apparatus. Radiology 1990;177:687-690.
14. Deka A, Saikia S, Bhuyan S. Combined posterior flap and anterior suspended flap dacryocystorhinostomy: A modification of external dacryocystorhinostomy. Oman J Ophthalmol 2010;3:18-20.
15. Acharya Ishan, H.S., Harsh Shah et al, Transition to external to endoscopic endonasal dacryocystorhinostomy: learning curve of an oculoplasty surgeon. Journal of clinical ophthalmology and research, 2015 Jan-Apr.3(1):p.19-22.
16. Tonuzi O, T.A., Voka B et al, A comparative of external and endoscopic endonasal dacryocystorhinostomy for the treatment of chronic dacryocystitis. National journal of otorhinolaryngology and head and neck surgery, Apr 2015.3(12)(number 1):p.11-12.
17. Gupta M, S.P., Mehta N et al Comparison of endonasal endoscopic dacryocystorhinostomy and external dacryocystorhinostomy- A prospective study. JK-Practitioner, Jan-June 2015.20(1-2):p.7-11.
18. Telang R, M.M., Joshi S A study of endoscopic endonasal dacryocystorhinostomy with mucosal flap technique. J of evidence based med & hlth care, Nov 2015.2(44):p.8050-59.
19. Singh H, M.N., comparative study of endonasal endoscopic dacryocystorhinostomy and external dacryocystorhinostomy. Clinical rhinology: An international journal, January-April 2015.8(1):p.1-4.
20. Nailwal S, R.A., Mehrotra N et al, Comparison of external and endonasal dacryocystorhinostomy in a acquired nasolacrimal duct obstruction. journal of evolution of medical and dental sciences, Feb 2015.4(14):p.2263-2273.
21. V. G., external versus endoscopic dacryocystorhinostomy in a specialized lacrimal surgery centre. Saudi journal of Ophthalmology, 2014(28):p.36-39.