

Sinonasal embryonal rhabdomyosarcoma presenting as bilateral visual loss: Case report

Sucheta Parija^{1,*}, Indranil Saha²

¹Assistant Professor, AIIMS, Bhubaneswar, ³PG Student, Department of Ophthalmology, SCB Medical College & Hospital, Odisha

***Corresponding Author:**

Email: suchetaparija@yahoo.com

Abstract

A 12 year old female, presented with rapidly progressive visual loss following left hemi facial pain for 15 days duration. Anterior segment and fundus examination was normal. She was diagnosed as retro bulbar neuritis and received steroid therapy. CT scan of PNS revealed a mass limited to the nasopharyngeal area and an endoscopic biopsy of mass revealed to be rhabdomyosarcoma, embryonal type. She was enrolled with pediatric oncology group rhabdomyosarcoma, as intermediate risk group to receive chemo-radiotherapy. A repeat MRI of brain done two weeks later, showed an intracranial extension of the tumor involving the optic nerve and chiasma. The fundus examination showed bilateral optic disc pallor. The patient responded well to chemotherapy but there was no visual improvement at four weeks follow-up. This case highlights the aggressive nature of rhabdomyosarcoma and should be kept as a differential diagnosis in cases of sudden loss of vision with normal fundus in children.

Keywords: Embryonal rhabdomyosarcoma², Optic atrophy⁴, Nasopharyngeal mass³, Chemotherapy¹

Introduction

Rhabdomyosarcoma (RMS) is a fast growing, highly malignant and the most common sarcoma in children^[1]. Proptosis, pain, restriction of ocular movements and vision loss and nasal obstruction are common symptoms of paranasal RMS, but, only eye symptoms without nasal symptoms are observed less often depending on the area involved^[2]. Optic neuropathies caused by nasal or paranasal sinus lesions are uncommon. Radiotherapy and chemotherapy is preferred with a combination of surgery for treatment^[3]. In this case we emphasize earlier imaging study and a multidisciplinary approach and prognosis of this rare case.

Case report

A 12 year old girl, presented with complaints of progressively worsening dull aching pain involving the left side of the face for 15 days and sudden diminution of vision in both eyes of 5 days duration. Past medical history was insignificant. Ophthalmological examination revealed normal anterior segment findings. Her visual acuity in the right eye was 6/60 and the left eye was projection of light. The pupils were mid-dilated and a relative afferent pupillary defect was seen in the left eye with a sluggishly reacting right pupil. Fundus picture of both eyes were normal (Fig. 1). She also

had a 2.1x1.7 cm, firm, mobile swelling on the right side of the neck corresponding to level II cervical lymph node. CT scan of the brain and orbits were normal. With a possibility of retrobulbar neuritis, she was initially started on intravenous, weight corrected dose of methylprednisolone once daily for 3 days.

Pediatric and ENT consultation was advised as there was no improvement in her visual status. The nasal endoscopic examination revealed the presence of a homogeneous, blue-purple color and well vascularized mass which filled out the left middle meatus.

Computed Tomography (CT scan) of the paranasal sinuses revealed an asymmetric soft tissue mildly enhancing mass of approximately 2.4 x 2.8cm in the left nasopharynx and left posterior nasal cavity (Fig. 2). The lesion was seen to displace the pterygoid muscle with minimal widening of the petro-clival fissure. Trans-nasal tumor biopsy was performed. In hematoxylin and eosin (H&E) stain, there were many small blue round cells along connective tissue strands and desmin stain reported as rhabdomyosarcoma, embryonal type (Fig. 3 a, b & c). FNAC of the lymph node was reported as reactive hyperplasia.

Patient was immediately referred to pediatric oncology department where she underwent CSF analysis, bone marrow biopsy, bone scan, and CT

scan for neck, chest, abdomen and pelvis to rule out systemic involvement. The patient belonged to stage 3 by TNM staging system and clinical group III by Intergroup rhabdomyosarcoma study group (IRSG) clinical grouping system. The patient was enrolled in the Pediatric Oncology Group Rhabdomyosarcoma 2007, Intermediate-risk Treatment Protocol for combined radio chemotherapy. She was started on chemotherapy with vincristine, actinomycin D and etoposide under the cover of steroids. Her visual symptoms were deteriorating and she had no perception of light in both eyes, after two weeks of starting chemotherapy. A repeat MRI Scan showed gross intracranial invasion involving the optic chiasma and the optic nerves (Fig. 4). Fundus picture now revealed signs of bilateral optic atrophy. The grave visual prognosis was explained and the patient was advised to complete the full chemotherapy cycles and radiation therapy.

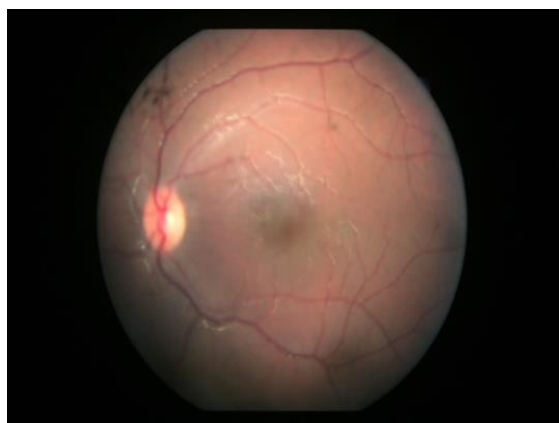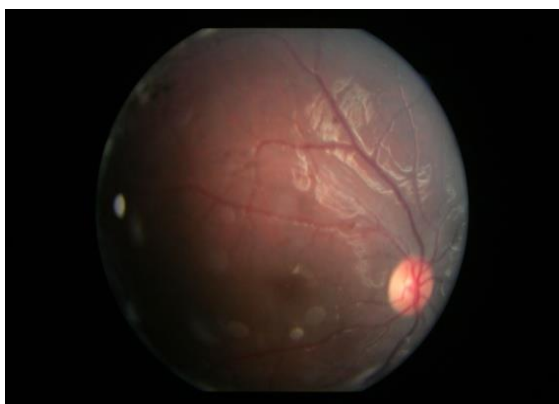


Fig. 1: Normal fundus at presentation

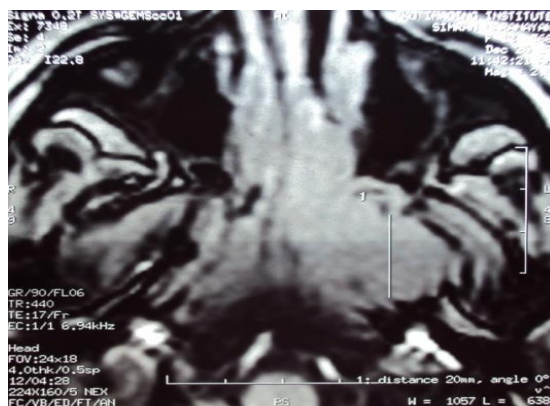


Fig. 2: CT scan of paranasal sinus showing a 2.4x 2.8cm tumor isolated in the nasopharyngeal area with no intracranial extension

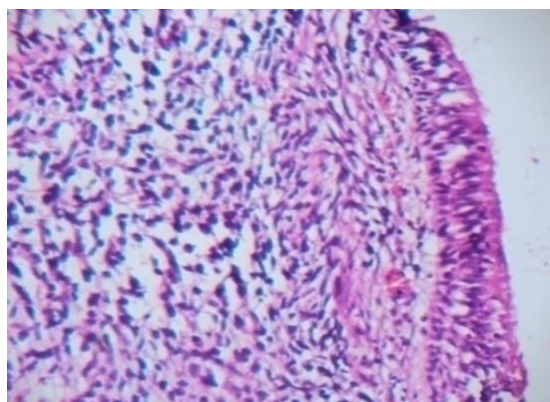


Fig. 3a: Microphotograph (100X, H&E) showing ovoid, round, and spindle cells with abundant eosinophilic cytoplasm

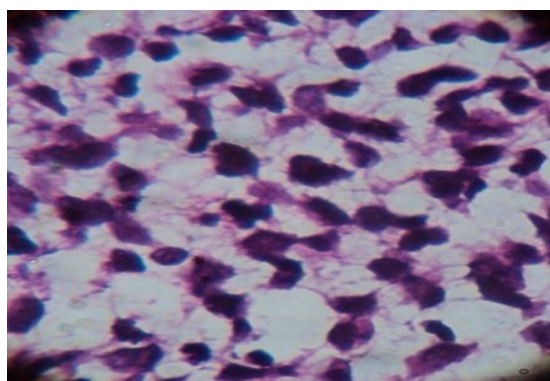


Fig. 3 b: Magnified view (400X) showing characteristic appearance of "small round blue cell tumor" on hematoxylin and eosin staining

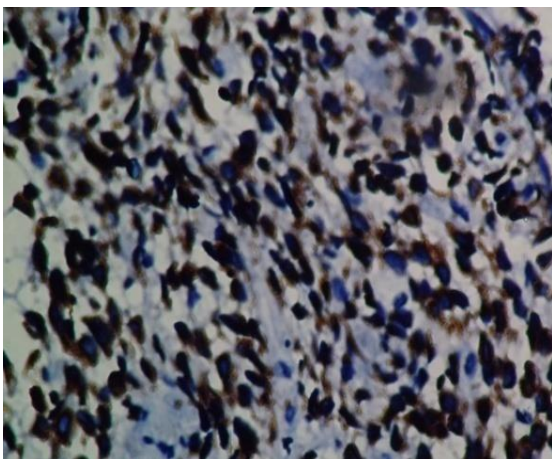


Fig. 3 c: Tumor cells showing diffuse cytoplasmic positivity by desmin stain

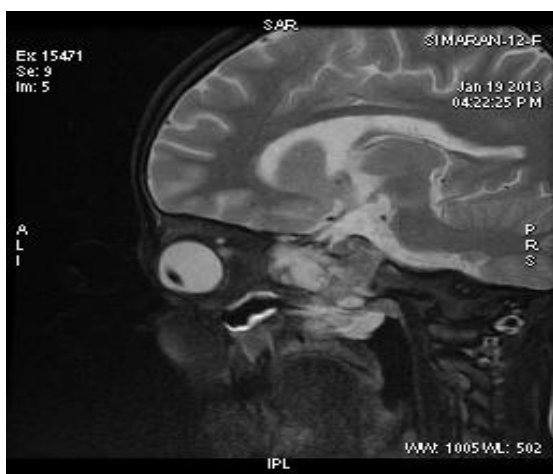

Fig. 4: MRI-T1 weighted sagittal plane shows an extension of the tumor involving the optic chiasma

Discussion

RMS is the most common soft tissue sarcoma in children. RMS grows from mesenchymal tissue and accounts nearly for 5% to 10% of all childhood malignancies.^[1] The annual incidence is approximately 4.5 cases per million in children and 50% of cases are seen in the first decade of life^[4]. Males are commonly affected, with a male to female ratio of 1.3 : 1^[1,5]. Head and neck RMS are more common in younger children accounting for 25-30%, with orbital involvement in 16% and paranasal sinuses in 10% of cases^[4,6]. RMS is found in three sites; orbital, parameningeal (nasal cavity, paranasal sinus, nasopharynx, infratemporal fossa) and superficial (pharynx, scalp, buccal mucosa, parotid, external ear, tonsil, face)^[1,2]. In non-metastatic RMS, parameningeal tumor belongs to stage 2 or 3 and orbital tumor

belongs to stage 1. The survival rate of RMS from parameningeal site is poorer than that from RMS from orbit.^[6]

Ahmed and Tsokos^[2] reported 14 cases with paranasal sinus involvement of the 39 patients with head and neck RMS. There were 9 ethmoidal and 5 maxillary sinus involvements^[2]. RMS of the paranasal sinus is often arising from ethmoid and maxillary region and is locally aggressive tumor. Our case was determined in ethmoid sinus. Even though the etiology is unknown, regional radiation is accused mostly. However, in one study, only two patients with RMS had a history of radiation out of 13 adult cases^[6] and also our case had no history of radiation.

Distinctive features appear to cluster around the site of the primary tumor, the age at diagnosis, and the histologic subtype. RMS from paranasal sinuses often presents with paranasal sinuses swelling, pain, proptosis, epistaxis, sinusitis, obstruction, and cranial nerve palsies.^[7] They are often advanced and locally invasive when the definite diagnosis is made,^[8] as was seen in our case. Bilateral visual loss without signs of orbital disease, normal ocular motility, normal fundus findings and normal CT scan of brain and orbits misled to the diagnosis of retro bulbar neuritis in our case.

Several distinct histological groups have prognostic significance, including embryonal rhabdomyosarcoma, which occurs in 55% of patients; the botryoid variant (5%); alveolar RMS (20%); undifferentiated sarcoma in 20% of patients^[4,5,6,9]. RMS in the head and neck is usually embryonal with a good prognosis. Sinonasal RMS is usually alveolar type with an aggressive tendency and a poor prognosis. Our patient had an aggressive type of embryonal sinonasal RMS with a metastasis to optic nerve and chiasma causing bilateral blindness. It is suggestive that early loss of vision is caused by optic atrophy due to direct pressure by the tumor.

Treatment of RMS varies depending on the pathologic and clinical stage. Radiotherapy and chemotherapy are preferred with a combination of surgery. Parameningeal RMS has more recurrence rates and has much more early metastasis because of the possibility of intracerebral spread.^[1,5] Callender et al. reported 75% regional recurrence rate among patients with RMS after surgery.^[7] Patients are allocated to low-risk/intermediate-risk/high-risk group based on age, primary site, TNM stage, IRSG clinical grouping, lymph node

status, and histology.^[4,6,10] Our patient was treated initially as intermediate risk group and was responding well to a combination of radio chemotherapy.

Conclusion

RMS is the most common sinonasal tumor in children. Patients with sinonasal tumors often have nasal symptoms but also insidious eye symptoms. So, any child with complains of progressive bilateral loss of vision should undergo nasal endoscopic evaluation in terms of differential and early diagnosis. It is one of the few life threatening diseases that may initially present to an ophthalmologist. An earlier diagnosis and prompt initiation of treatment have been associated with more favorable outcomes. Thus, it is crucial for ophthalmologists to promptly recognize and diagnosis this malignancy.

Conflicts of Interest: Authors disclose no sponsorship or funding arrangements or any possible conflicts of interest in this research.

References

1. Erkul E, Pinar D, Yilmaz I, Cincik H, Cekin E, Salihoglu M. Rare Adult Sinonasal Embryonal Rhabdomyosarcoma with Optic nerve involvement. *Otolaryngology*. 2012;2:118.
2. Ahmed AA, Tsokos M (2007) Sinonasal rhabdomyosarcoma in children and young adults. *Int J Surg Pathol* 15: 160-5.
3. Linabery AM, Charbonneau B, Ross JA. Trends in childhood rhabdomyosarcoma incidence and survival in the United States, 1975–2005. *Cancer*. 2009;115(18):4218–4226.
4. Chen SC, Bee YS, Lin MC, Sheu SJ. Extensive alveolar-type paranasal sinus and orbit rhabdomyosarcoma with intracranial invasion treated successfully. *Journal of the Chinese Medical Association* 2011;74:140-143.
5. Crist WM, Anderson JR, Meza JL, Fryer C, Raney RB, Ruymann FB, et al. Intergroup rhabdomyosarcoma study-IV: Results for patients with non-metastatic disease. *J Clin Oncol* 2001;19:3091-102.
6. Li Jun, Thompson TD, Miller JW, Pollack LA, Stewart SL. Cancer incidence among children and adolescents in the United States, 2001-2003. *Pediatrics* 2008;121:1470-7.
7. Callender TA, Weber RS, Janjan N, Benjamin R, Zaher M, Wolf P, et al. Rhabdomyosarcoma of the nose and paranasal sinuses in adults and children. *Otolaryngol Head Neck Surg* 1995;112:252-7.
8. Anderson GJ, Tom LW, Womer RB, Handler SD, Wetmore RE, Potsic WP. Rhabdomyosarcoma of the head and neck in children. *Arch Otolaryngol Head Neck Surg* 1990;116:428-31.
9. Shields CL, Shields JA, Honavar SG, and Demirci H. Clinical spectrum of primary ophthalmic rhabdomyosarcoma. *Ophthalmology* 2001;108:2284-2292.
10. Meza JL, Anderson J, Pappo AS, Meyer WH. Analysis of prognostic factors in patients with non-metastatic rhabdomyosarcoma treated on intergroup rhabdomyosarcoma studies III and IV: The children's oncology group. *J Clin Oncol* 2006;24:3844-51.