

Comparing effect of clear corneal incision and sclera tunnel incision in phacoemulsification on central corneal thickness

Vimlesh Sharma

Assistant Professor, Dept. of Ophthalmology, Govt. Medical College, Haldwani, UK
E-mail: drvimlesh@yahoo.com

Abstract

Aim: To compare the effect of clear corneal incision and sclera tunnel incision on central corneal thickness in eyes undergoing phacoemulsification.

Setting: Department of ophthalmology, Government Medical College Haldwani, Nainital, Uttarakhand.

Materials and Methods: This prospective study included 68 eyes with senile cataract from grade 1 to 3 which underwent phacoemulsification during May 2015 to October 2015 through clear corneal incision or through sclera tunnel incision. Patients were randomly assigned in group 1 with clear corneal incision and group 2 with sclera tunnel incision. All the surgeries were performed by single surgeon using same technique. Postoperatively central corneal thickness were measured with optical non-contact biometry in both the groups on 2nd post-op day, at 1-2 weeks, 6-8 weeks and at 3 months and compared.

Results: Mean increase in CCT on 2nd postoperative day was 82µm and 62 µm in Group I and Group II respectively. At 2 weeks it was 51 µm and 23 µm, at 6 weeks it was 30 µm and 5 µm, at 3 months 4 µm and 5 µm more than the baseline values.

Conclusion: This study revealed that increased CCT as caused by corneal oedema occurring in immediate postoperative period was more in Group I as compared to Group II. The values returned to normal range in 3 months and 2 months in Group I and Group II respectively.

Key words: Clear corneal incision, Central corneal thickness, Scleral tunnel incision.

Access this article online	
Quick Response Code:	Website: www.innovativepublication.com
	DOI: 10.5958/2395-1451.2016.00011.1

Introduction

Cataract surgery has evolved as one of the most technically advanced and safe surgical procedure with gratifying results. It has become more of a refractive procedure than simply removal of cataractous lens. Most of us now trying to adapt variation during cataract surgery like reducing incision size, choosing different sites of incision, shifting towards machines with better fluidics, using different techniques for phacoemulsifications with lesser phaco time and power. All these efforts are towards early visual rehabilitation and better safety profile. This study is carried out in order to view the post-operative changes in central corneal thickness if we use different site of incision i.e. clear corneal and sclera tunnel incision.

Materials and Method

This prospective study was done at department of ophthalmology, Government Medical College, Haldwani, Nainital, Uttarakhand to compare post-operative corneal thickness following cataract surgery by phacoemulsification with foldable intraocular lens implantation, using different site of surgical incisions. 68 patients were selected for study, with age ranging from 45 to 80 years. Patients were randomly divided

into two groups based on the types of surgical incision. Group I- Superior Clear Corneal Incision of 2.8mm, and Group II- Superior Scleral Tunnel Incision of 2.8mm. Only eyes having immature cataracts (Grade I, II and III) were taken into account.

Exclusion criteria: One eyed patients, patients with subluxated lens, corneal dystrophies, corneal opacities, shallow anterior chamber (i.e. <2.8mm), pre-existing ocular surgeries and eyes with Uveitis.

Complete ocular examination was performed using slit lamp, funduscopy and pre and post-operative clear corneal thickness was taken with optical non-contact bio meter. Considering exclusion criteria and checking out normotensive and normoglycaemic status, surgery was performed after written consent.

Technique of making Clear Corneal Incision: Site of incision was 1mm anterior to the superior limbus, just anterior to conjunctival vascular arcades in the clear cornea. A straight partial thickness vertical incision of 2.8mm in size is made in the corneal tissue on the above mentioned site. Next, a 2.8mm keratome is taken and the tip introduced into the exposed corneal stroma, just short of the full depth of the incision. The blade is then held parallel, relative to the corneal surface and advanced into the corneal stroma up to the desired length. Then the hilt of blade is lifted and tip pointed towards the anterior chamber. After making incision, the anterior chamber was filled with viscoelastic material.

Technique of making Scleral Tunnel Incision: First of all, the conjunctiva is reflected from limbus and mild

bipolar cautery applied for haemostasis. Then, a depth of preset knife (300 μ) is used to make the initial incision into the sclera, 1mm posterior to the superior limbus. Then, a crescent blade is taken and the dissection begins at the correct depth to maintain the same depth throughout the length and breadth of the incision. The dissection is carried forward across the limbus, 1mm into the clear cornea, maintaining the same depth of dissection. Finally, AC is entered using 2.8mm keratome. AC is filled with viscoelastic material.

Once the tunnel is made, paracentesis steps are made at 10 O'clock and 2 O'clock positions. After finishing all the routine steps, phacoemulsification is performed by direct chop-method.

Post-operative examination consisted of a detailed slit lamp examination of wound, corneal transparency,

keratitis and complete anterior segment examination. Fundoscopy was done for media clarity and CCT was taken with optical non-contact biometry at 2nd post-operative day, 1st, 2nd and 3rd month post-operatively.

Routine post-operative care was given in the form of antibiotic steroid drops, cycloplegic and lubricant eye drops. Effects on corneal thickness in 2 types of incisions were compared.

Observations: The present study shows the comparison of CCT in CCI Group I and STI Group II.

Patient data: 68 eyes with senile cataracts were included in this study. 39.5% were females and 60.5% were males. The average age of the patient was 60.4 years, ranging from 45 years to maximum 80 years.

Table 1: Patient Data

Age Groups (Years)	Number of Cases				
	Total	Male		Female	
Less than 46	3	1	1.5%	2	3.0%
46-55	14	10	15.0%	4	6.0%
56-65	34	22	32.0%	12	18.0%
66-75	15	7	10.5%	8	12.0%
76-85	2	1	1.5%	1	1.5%
Total	68	41	60.5%	27	39.5%

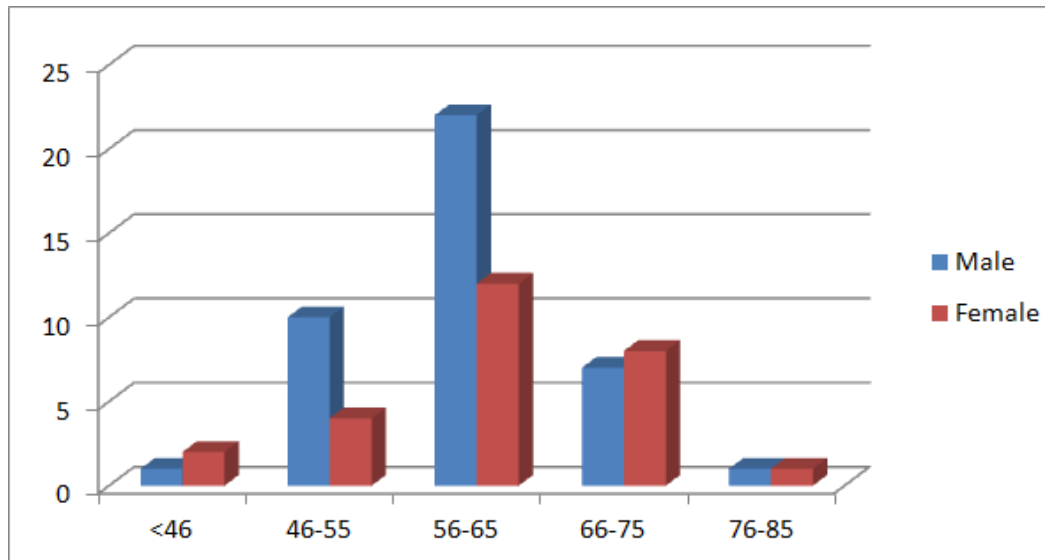
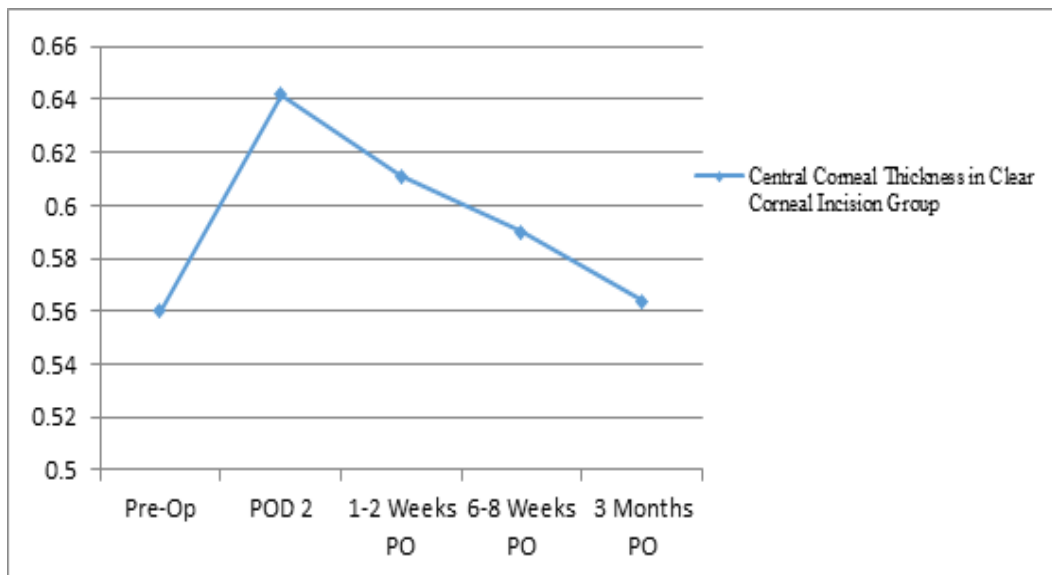


Fig. 1: Age Groups (Years)

Table 2: Central Corneal Thickness in Clear Corneal Incision Group

Range (in mm)	Pre-op	2 nd POD	1-2 Week	6-8 Weeks	3 Months
0.500-0.525	5				6
0.526-0.550	6			4	6
0.551-0.575	9		3	7	8
0.576-0.600	6	4	7	8	3
0.601-0.625	3	6	8	6	4
0.626-0.650		8	6	4	2
0.651-0.675		6	5		
0.676-0.700		5			
0.701-0.725					
0.726-0.750					
Mean	0.560	0.642	0.611	0.590	0.564

**Fig. 2: Central corneal thickness in clear corneal incision group**

Total 29 cases underwent clear corneal incision. Preoperative values of CCT ranged from 0.500-0.525 to 0.601-0.625 (in mm). This rose to 0.576-0.600 to 0.676-0.700 range on immediate 2nd POD. The values returned to preoperative levels in three months follow up except for three cases which showed persistent corneal oedema.

Table 3: Central Corneal Thickness in Scleral Tunnel Incision Group

Range (in mm)	Pre-op	2 nd POD	1-2 Week	6-8 Weeks	3 Months
0.500-0.525	8			5	5
0.526-0.550	14		8	14	14
0.551-0.575	11	6	15	12	13
0.576-0.600	6	8	12	8	7
0.601-0.625		14	4		
0.626-0.650		8			
0.651-0.675		3			
0.676-0.700					
0.701-0.725					
0.726-0.750					
Mean	0.548	0.610	0.571	0.553	0.553

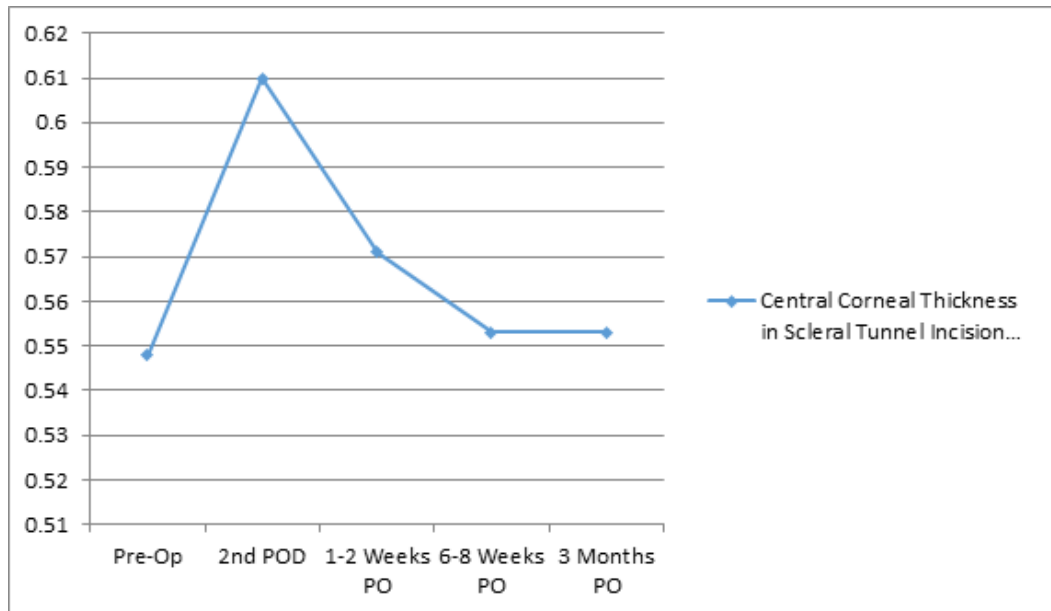


Fig. 3: Central corneal thickness in tunnel incision group

Total 39 cases underwent scleral tunnel incision. Preoperative values of CCT ranged from 0.500-0.525 to 0.576-0.600 (in mm). This rose to 0.651-0.675 range on immediate 2nd POD. The values returned to preoperative levels in two months follow up except for two cases which showed persistent corneal oedema.

Discussion

Central and peripheral corneal thickness was measured in patients undergoing phacoemulsification with IOL implantation. Results were compared between CCI group and STI group. Corneal thickness was measured preoperatively and postoperatively respectively on 2nd day, 1-2 weeks, 6-8 weeks, and 3 months. Corneal oedema was assessed using slit lamp examination and optical non-contact bio meter. Most of the cases even with persistent corneal oedema showed clear cornea and clear anterior segment but on non-contact biometry readings was found to having mild corneal oedema as seen by raised corneal thickness values. It was also noted that overall there were more corneal complications in clear corneal group than in sclera tunnel group, resulting in comparative more increase in CCT in group I than in group II but in both the cases values were reaching to preoperative values in more or less equal time i.e. 2-3 months. Almost similar results were noted in previous studies by other authors.

Conclusion

There was no significant difference in the corneal clarity starting from the immediate post-operative period, but there was increase in CCT of both the groups, which settled to preoperative levels in 2-3 months in both the groups. This suggest that site of incision is not major deciding factor in predicting corneal safety but there are other parameters which make differences like grade of cataract, total phaco power, total phaco time etc. In experienced hands safety

profile for cornea is same for both clear corneal incision and sclera tunnel incision groups.

Conflict of Interest: None

Source of Support: Nil

References

1. Davis DB. Scleral Incision with cataract surgery. Thorafore NJ, Slack 1990; 147-150. Arch Ophthal 1966;76:25-31.
2. J Cataract refractive Surgery 2007 Aug 33(8):1426-28, CCT changes after phacoemulsification cataract surgery Salil SM (1), Soong T.K, Kumar.
3. De Freitas Valvon et al. J ref and Cataract Surgery 2012 Mar 28(3);215-9. Central corneal thickness and biochemical changes after clear corneal phacoemulsification.
4. Tanveer Anjum Chaudhary et al. Central corneal thickness after phaco-emulsification, Pakistan J of Ophthalmology Vol -31. No-2 April to June 2015.
5. Artemios Kandarakis et al Acta Ophthalmologica 2012 response of corneal hysteresis and central corneal thickness following clear corneal cataract surgery.
6. Koch PS, Structural analysis of cataract incision construction cataract refractive surgery 1991;17 suppl:661-67.
7. Girard LJ, origin of Scleral Tunnel incision J cataract and ref surgery 1995;21(1):6.