

Ossified Pterygospinous Ligament-An anomaly in the infratemporal region of human Skulls and its applied importance

Rashmi Ghai^{1,*}, Shilpi Jain², Satyam Khare³, Chhitij Anand⁴, Alok Tripathi⁵, RK Kaushik⁶

Dept. of Anatomy, Subharti Medical College, Uttar Pradesh

***Corresponding Author:**

Rashmi Ghai

Dept. of Anatomy, Subharti Medical College, Uttar Pradesh

Email: rghai71@yahoo.com

Abstract

Pterygospinous ligament stretches from pterygospinous process of lateral pterygoid plate to the spinous process of sphenoid bone. Occasionally this ligament ossifies in elderly. We carried out a study in subharti medical college, Meerut on 50 adult dry skulls to observe ossification of pterygospinous ligament. In our study, bilateral completely ossified Pterygospinous ligament was found in only 2% of skulls and rest 98% showed no ossification of the ligament. This ligament lies in close relationship to foramen ovale thus may cause entrapment of various branches of mandibular nerve resulting in mandibular neuralgia. Knowledge of ossified pterygospinous ligament is of great importance to maxillofacial, dental surgeons and anesthetists.

Key words: Ossified Pterygospinous ligament, Foramen ovale, Skulls, Neuralgia.

Access this article online	
Quick Response Code:	Website: www.innovativepublication.com
	DOI: 10.5958/2394-2126.2016.00051.7

Introduction

Pterygospinous ligament stretches from the upper part of posterior border of lateral pterygoid plate to the spine of the sphenoid bone. It is present in the infratemporal region of skull, inferior to foramen ovale (Erdogmus, Pinar and Celik, 2009). It was first described by Italian anatomist F. Civinini as Civinini ligament (Von Ludinghausen, 2006).

Occasionally in cases where Pterygospinous ligament ossifies, a foramen known as Pterygospinous foramen is formed between its upper border and the skull base. The branches of the mandibular nerve on their passage to the muscles of mastication, then pass through the said foramen (William P L Gray 1995, Von Ludinghausen 2006).

Study of causes for Trigeminal nerve compression, causing neuralgia, showed that around 20% of cases have bony factors in the region of skull base as the reason for compression (Hai J, Li S & Pan QG 2006). Thus presence of an ossified Pterygospinous ligament in the infratemporal region in close proximity to foramen ovale can cause compression of mandibular nerve and its branches, causing Mandibular neuralgia. Compression of motor branches of the mandibular nerve cause paralysis or weakness of muscles supplied by them. Compression of the sensory branches can provoke neuralgia or paraesthesia (Piagkou et al, 2011). Entrapment of lingual nerve, a branch of the posterior

division of the mandibular nerve can lead to hypoaesthesia or anaesthesia of tongue and loss of sensation of taste in the anterior 2/3rd part (oral part) of tongue and anesthesia of gums (Piagkou et al, 2010).

Ossified pterygospinous ligaments are of great significance for block of mandibular nerve and for therapeutic treatment of trigeminal neuralgia (Das & Paul, 2007; Singh et al., 1993). These procedures are usually performed through foramen ovale, where these ossified pterygospinous ligaments can be found (Rosa et al, 2010). Ossified pterygospinous ligament can also be a hindrance for mandibular nerve block which is preferred method for relief of pain in case of mandible fracture or cancer patients (Peuker, 2001, Pinar, 2004 & Erdine 2005). Thermo-coagulation of the trigeminal ganglion also become difficult in the presence of ossified pterygospinous ligament (Lang, 1995)

Material & Method

A descriptive study based on observation of skulls was undertaken.

50 adult human dry skulls were collected from the department of Anatomy, Subharti Medical College, Meerut. The presence or absence of ossified pterygospinous ligament was recorded. If ossification was found it was noted whether it was complete or partial and if it was unilateral or bilateral.

Observation & Result

If the pterygospinous ligament is completely ossified, there is a bony bridge between the upper part of posterior border of lateral pterygoid plate and a bony process that comes from the anterolateral part of the base of the spine of sphenoid. In case of incompletely ossified pterygospinous ligament, a gap is present between Pterygospinous process and a process that

emerges from the anterolateral area of the base of spine of sphenoid.

In this study on 50 skulls, bilateral completely ossified pterygospinous ligament was present in one of them (2% of skulls). Thus bilateral pterygospinous foramen of Civinini was also present in this skull. This ossified pterygospinous ligament was observed stretching between the upper part of posterior border of lateral pterygoid plate to the spine of sphenoid, inferior to and crossing the foramen ovale (Fig. 1, 2 & 3).

In rest 49 skulls, no evidence of ossified pterygospinous ligament was observed.

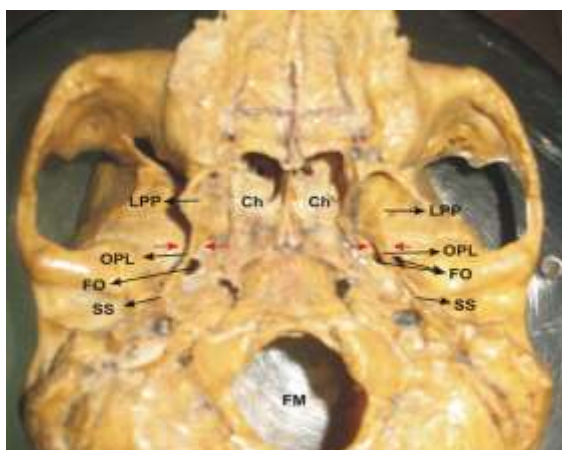


Fig. 1: Base of skull showing bilateral ossified pterygospinous ligament & pterygospinous foramen

LPP: Lateral Pterygoid Plate
 OPL: Ossified Pterygospinous Ligament
 FO: Foramen Ovale
 SS: Spine of Sphenoid
 Ch: Choana
 FM: Foramen Magnum Red Arrows in Pterygospinous Foramen

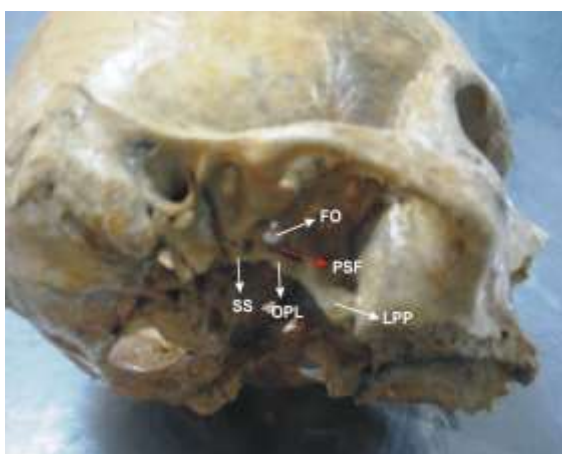

Fig. 2: Region of Infratemporal fossa of right side

Showing completely ossified pterygospinous ligament
 LPP: Lateral Pterygoid Plate, OPL: Ossified Pterygospinous Ligament, FO: Foramen Ovale, SS:

Spine of Sphenoid, PSF: Pterygospinous Foramen Red Arrow in Pterygospinous Foramen

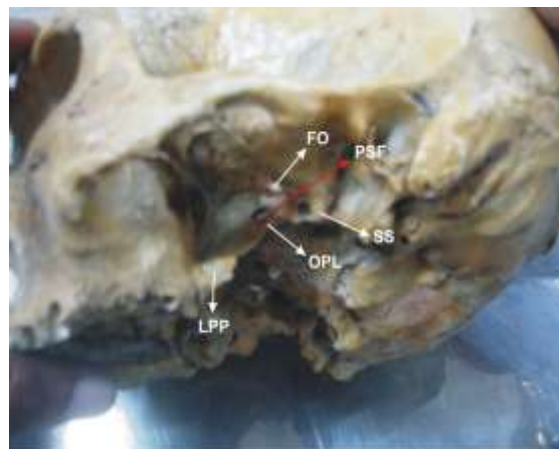


Fig. 3: Region of Infratemporal fossa of left side

Showing completely ossified pterygospinous ligament
 LPP: Lateral Pterygoid Plate, OPL: Ossified Pterygospinous Ligament, FO: Foramen Ovale, SS: Spine of Sphenoid, PSF: Pterygospinous Foramen Red Arrow in Pterygospinous Foramen

Discussion

Peuker et al (2001) are the first who found completely ossified pterygospinous ligament and compressed lingual nerve between this ligament and medial pterygoid muscle by cadaveric dissection.

Pterygospinous ligaments occupy deep positions in the infratemporal fossa and establish important relationship with the structures which lie in the infratemporal fossa like mandibular nerve and its branches, otic ganglion, middle meningeal artery and vein, pterygoid muscles. These structures are compressed by ossified pterygospinous ligament and are capable of generating symptoms. (Krmptic-Nemanic et al 1999, Peuker et al 2001, Von Ludinghausen et al 2006).

Vonludinghausen et al (2006) found completely ossified pterygospinous ligament in 1.85% on cadaver and 6% on dry human skulls. Woodjones (1931) reported in Hawaiian skulls 8% ossified pterygospinous ligament, Peker et al(2002) reported the presence of this bridge in 8.8% of skulls of Anatolian population. Nayak et al (2007) analyzed 416 Indian dried skulls and noticed that the pterygospinous bony bridges were present in 9.61% of the samples, out of these 5.76% were complete and 3.84% were incomplete.

Suazo (2010) evaluated a sample of 312 skulls (284 from a Brazilian population and remaining from other nations) for Pterygospinous ligament ossification and obtained incidence of only 1.6% of complete ossification of the pterygospinous ligament. Rosa et al (2010) radiographed 93 dried skulls and detected this ligament in 27.97% of radiographs, out of which

19.36% were partially ossified and 8.61% were completely ossified. Kapur et al (2000) reported only 1.31% of completely pterygospinous ligament from a sample of 305 croats 'skulls. Antonopoulou et al (2008) noticed that 25% of the skulls had incompletely ossified pterygospinous ligaments and bilateral completely ossified pterygospinous ligaments in 2% of the skulls.

Das and Paul, (2007) observed ossified pterygospinous ligament in only one bony specimen out of 100 cases (both sides of 50 sphenoid bones). This ossified ligament was present on right side of skull. Tubbs (2009) found ossified pterygospinous ligament & pterygoalar ligament after analyzing 154 adult human dried skulls. They found 2 ossifications each (2.6%) of ligaments. They stated that such bony anomalies could be an obstacle while placing transcutaneous needle into foramen ovale. Peker et al (2002) after studying 452 adult dry skulls and 9 cadavers, found complete ossification of pterygospinous ligament in 5.5% of skulls and bilateral completely ossified pterygospinous bridges in 3.1% of skulls.

In our study, bilateral completely ossified pterygospinous ligaments were found in only one skull, out of 50 skulls (2% of skulls). Rest of the 49 skulls did not have ossified pterygospinous ligament.

Conclusion

Presence of complete or incomplete ossified pterygospinous ligament have clinical significance as these ligament establish relationship with the foramen ovale. Difficulty in accessing the foramen ovale in therapeutic approach to skull base occurs in the presence of such ossified ligaments due to less accessible space into para and retropharyngeal space (Von ludinghausen, 2006). An ossified pterygospinous ligament can be a hindrance to anesthesia of mandibular nerve by lateral sub-zygomatic route (Kapur 2000).

Percutaneous procedure for the treatment of trigeminal neuralgia involve the foramen ovale penetration (Gerber et al, 1994). Injection of anesthetic agent in trigeminal ganglion becomes difficult when the ossified pterygospinous ligament covers the foramen ovale and obstruct the passage of the needle through the foramen ovale (Von Ludinghausen et al 2006, Erdine 2005). It has also been reported that thermo-coagulation of the trigeminal ganglion becomes difficult in the presence of such ossified ligaments(Lang 1995). Kapur et al (2000) stated that the radiological guidance is required to visualize the foramen ovale and its related structures which makes puncture easier and more precise. Thus anatomical knowledge of ossified pterygospinous ligament may be beneficial for anesthetists, dental and maxillo-facial surgeons in the treatment of trigeminal neuralgia.

References

1. Antonopoulou, M.; Piagou, M. & Anagnostopoulou, S. Anatomical study of the pterygospinous and

2. pterygoalar bars and foramina-their clinical relevance. J. Craniomaxillofac. Surg., 36(2):104-8,2008.
3. Das, S & Paul, S. Ossified Pterygospinous ligament and its clinical implications. Bratisl. Lek. Listy, 108(3):141-3,2007.
4. Kapur, E.; Dilberovic, F.; Redzepagic, S. & Berhamovic, E. Variation in the Lateral Plate of the pterygoid process and the lateral subzygomatic approach to the mandibular nerve. Med. Arh.,54(3):133-7, 2000.
5. Krmptotic_Nemanic, J.; Vinter, I.; Hat, J. & Jalsovec, D. Mandibular neuralgia due to anatomical variations. Eur. Arch. Otorhinolaryngol., 256(4):205-8,1999.
6. Nayak, S.R.; Saralaya, V.; Prabhu, L.V.; Pai, M.M.; V Adgaonkar, R. & D Costa, S. Pterygospinous bar and foramina in Indian skulls: incidence and phylogenetic significance, Surg. Radiol. Anat.,29(1):5-7,2007.
7. Peuker, E.T.; Fischer, G. & Filler, T.J. Entrapment of the lingual nerve due to an ossified pterygospinous ligament. Clin. Anat. 14(4):282-4,2001.
8. Singh, B.; Srivastava, S.K.; Dang, R.; Gombar, K.K. & Gombar, S. Anatomic considerations in relation to the mandibular nerve block. Reg. Anesth., 18(3):181-3,1993.
9. Von Ludinghausen, M.; Kageyama, I.; Miura, M. & Alkhatib, M. Morphological peculiarities of the deep infra temporal fossa in advanced age Morphological peculiarities of the deep infratemporal fossa in advanced age. Surg. Radiol. Anat.,28(3):284-92,2006.
10. Wood-Jones, F. The non-metrical Morphological characters of the Skull as Criteria for Racial Diagnosis: Part II: The non-metrical Morphological Characters of the Hawaiian Skull. J. Anat.,65(3):368-78,1931.
11. Pinar Y, Arsu G, Aktar Mriz ZA, Bilge O. Pterygospinous and Pterygoalar bridges. Sandram 2004;16:66-69.
12. Erdine S. Rejyonel Anestezi. Nobel Tip Kitabevieri Istanbul. 2005:67-70.
13. Piagkou M, Demesticha T, Piagos G, Georgious A, Panagiotis S. Lingual nerve entrapment in muscular and osseous structures. Int J Oral Sci.2010 Dec;2(4):181-9.
14. Tubbs, R. Shane MS, WILLIAM R., Apaydin, Nihal, Shoja, Mohammedali M, Shokouhi, Ghaffar, Loukas, Marios, Cohen-Gadol, Aaron A. Ossification of ligaments near the foramen ovale: An anatomic study with potential clinical significance regarding Transcutaneous approaches to the clinical base.2009,63(6):60-64.
15. Piagkou M, Demesticha T, Piagos G, Androutsos, Gand Skandalakis P. Mandibular nerve entrapment in the infratemporal fossa. Surgical & Radiological Anatomy.2011:May 33(4):291-9.
16. Peker T., Karakose, M., Anil, A., Turget, HB and Gulekon. The incidence of basal sphenoid bony bridges in dried crania and cadavers; their anthropological and clinical relevance. European Journal of Morphology,2002,vol.40 no.3,p.171-80.
17. Erdogmus, S., Pinar, Y. and Celik., SA. A cause of entrapment of the lingual nerve: ossified pterygospinous ligament.-a case report.Neuroanatomy,2009,vol.8,p.43-45.
18. Suazo Galdomus, I., Zavando Matamala, D and Smith RL. Anatomical study of the pterygospinous and pterygoalar bridges and foramen in dried crania and its Clinical relevance. International journal of Morphology,2010 vol 28,p.405-8.
19. Lang J. Skull base and related structures. Schattauer; Stuttgart, 1995:300-311.
20. Loughner BA, Larkin LH, Mahan PE. Nerve entrapment in the lateral pterygoid muscle. Oral Surj Oral med Oral pathol1990;69:299-306.

20. Rosa RR, Faig –Leite H, Faig –Leite FS, Moraes L C, Moraes ME, Filho EM. Radiographic study of ossification of the pterygospinous and pterygoalar ligaments by the Hirtz axial technique. *Acta Odontol Latinoam*,2010;3(1):63-7.
21. Gerber AM. Improved visualization of the foramen ovale for percutaneous approach to the Gasserian ganglion. Technical note. *J Neurosurj*, 1994;80:156-159.
22. Hai J, Li ST, Pan QG. Treatment of atypical trigeminal neuralgia with micro vascular decompression. *Neurol India* 2006;54:1-4.
23. Williams P L. *Gray's Anatomy*. 38thEd.USA, Churchill Livingstone.1995;588-801.
24. Loughner BA, Larkin LH, Mahan PE. Nerve entrapment in the lateral pterygoid muscle. *Oral Surg Med Oral Pathol* 1990;69:299-306.