

Evaluation of results of “short proximal femoral nailing” in unstable trochanteric fractures

Santosh Kumar Sahu^{1,*}, Khusbu Parichha²

¹Assistant Professor, ²Junior Resident, Dept. of Orthopaedics, KIMS Medical College & Hospital, Andhra Pradesh

***Corresponding Author:**

Email: dr.santosh369@gmail.com

Abstract

The incidence of the hip fracture has been rising with an aging population in many parts of the world. Growing number of population and the road traffic accidents have resulted in an enormous increase in these types of fractures. In younger patients the fractures usually result from high energy trauma like RTA and fall from height and accounts for only 10%. Older patients suffering from a minor fall can sustain fracture in this area because of weakened bone due to osteoporosis or pathological fracture and these accounts for 90%. Surgical management of trochanteric fractures aims at restoring the pre-fracture functional status of patients as far as ambulatory skills are concerned. A variety of implants of internal fixation have been employed to achieve this goal with variable success. The diversity of fixation devices available for treatment of trochanteric fractures illustrates the difficulties encountered for fixation, and the discussion about ideal implant for such cases continues. For the last 20-30 years a better understanding of the biomechanics of the fracture and the development of better implants have lead to radical changes in treatment modalities. With the thorough understanding of fracture geometry and biomechanics optimal treatment can be selected for individual cases. Unstable fracture patterns with postero-medial instability and a fracture with reverse obliquity poses specific challenges in their treatment as well as treatment outcome. Intramedullary devices, theoretically due to its position providing more efficient load transfer and shorter lever arm; can decrease tensile stress and thereby decreasing the risk of implant failure. We conducted a Prospective study, with a sample size of 60, with an aim to evaluate the functional outcome of treatment of unstable Inter-trochanteric Femoral fractures by Short Proximal Femoral Nail (PFN) in terms of maintaining of anatomy radiologically, to assess healing or union of fracture clinico-radiologically, Counteracting the per-operative and post-operative complications, to assessment of functional outcome by Harris Hip Score & Comparison of results with standard literature.

Introduction

“Life is movement, movement is life” – this should be the guiding principle behind each and every fracture care. As the ancient arts of bone setting, traction confinement to bed immobilization gave way to modern internal fixation, many principles of operative treatment of fractures became widely accepted. Conservative modality of management does not hold good in treating all types of fractures often leading to different untoward sequel.

The incidence of the hip fracture has been rising with an aging population in many parts of the world, and the number of hip fractures is expected to reach 512,000 in the year 2040¹. Growing number of population and the road traffic accidents have resulted in an enormous increase in these types of fractures. In younger patients the fractures usually result from high energy trauma like RTA and fall from height and accounts for only 10%⁽²⁾. Older patients suffering from a minor fall can sustain fracture in this area because of weakened bone due to osteoporosis or pathological fracture and these accounts for 90%⁽²⁾. Surgical management of trochanteric fractures aims at restoring the pre-fracture functional status of patients as far as ambulatory skills are concerned. A variety of implants of internal fixation have been employed to achieve this goal with variable success. The diversity of fixation devices available for treatment of trochanteric fractures illustrates the difficulties encountered for fixation, and the discussion about ideal implant for such cases

continues⁽³⁾. For the last 20-30 years a better understanding of the biomechanics of the fracture and the development of better implants have lead to radical changes in treatment modalities. With the thorough understanding of fracture geometry and biomechanics optimal treatment can be selected for individual cases. Unstable fracture patterns with postero-medial instability and a fracture with reverse obliquity poses specific challenges in their treatment as well as treatment outcome⁽⁴⁾. In unstable trochanteric fractures with loss of postero- medial cortex continuity and stability, when load is applied it increases the bending force on the DHS leading to implant breakage, screw cut-out or separation of plate from shaft. Mechanical failure including loss of purchase of the compression screw within the femoral head, pulling out of the side plate, and disengagement of the screw and barrel have been reported to occur in as many as in 28% of fractures^(5,6). Additionally, over-impaction of the fracture fragments with lag screw and side plates may lead to significant loss of limb length and delay in rehabilitation and ambulation⁽⁷⁾. This lead to the introduction of intramedullary devices, which theoretically, due to its position providing more efficient load transfer and shorter lever arm; can decrease tensile stress and thereby decreasing the risk of implant failure. The proximal femoral nail (PFN) introduced by the AO/ASIF group in 1998 has become prevalent in treating trochanteric fractures in recent years⁽⁸⁻¹¹⁾.

Aims

The study was undertaken in a Prospective manner to evaluate the functional outcome of treatment of unstable Inter-trochanteric Femoral fractures by Short Proximal Femoral Nail (PFN).

The objectives of this study were-

- To study the result of Short Proximal Femoral Nailing in unstable inter-trochanteric fractures in terms of maintaining of anatomy radiologically.
- To assess healing or union of fracture clinico-radiologically.
- Counteracting the per-operative and post-operative complications.
- Assessment of functional outcome by Harris Hip Score.
- Comparison of results with standard literature.

Short Proximal Femoral Nailing (PFN): P.F.N. is a third generation cephalomedullary nail, was introduced by AO, and marketed by Synthes initially; all parts of the PFN implant are made of a Titanium–Aluminium–Niobium alloy with a single proximal helical screw.⁽⁸⁾ We have used an Indian version of the nail; 240 mm in length is made of 316 LVM stainless steel. Detailed of its anatomy is discussed later on. A **meta-analysis** conducted by **C Zeng et al at 2012** comparing inter-trochanteric fractures treated with a DHS and intramedullary nail reported that the use of intramedullary nails for treatment of trochanteric fractures was found to be superior to DHS, in terms of duration of surgery, intra-operative blood loss, and rates of fixation failure and overall complications.⁽⁹⁾ A **retrospective** study by **Henrik Palm** et al showed 311 consecutive patients treated with either an IMN or an SHS mounted on a 4-hole side plate, for an AO/OTA type 31A1–2 pertrochanteric fracture with a detached greater trochanter shows; IMN had a lower reoperation rate than SHS in these pertrochanteric hip fractures with a detached greater trochanter and IMN leave lateral femoral walls more intact.⁽¹⁰⁾ A **prospective, randomized study** by **Christopher Sadowski** et al, support the use of an intramedullary nail rather than a 95° screw-plate for the fixation of reverse oblique and transverse intertrochanteric fractures in elderly patients.⁽¹¹⁾ A **retrospective review** of geriatric patients by **Edward Rodriguez** et al shows that management of geriatric unstable intertrochanteric femur fractures with a short 3rd generation cephalomedullary device is a reliable technique with an incidence of complications similar to or less than alternative plating fixation or long intramedullary nails.⁽¹²⁾ A **prospective study** by **Jensen L** et al showed TFN is an appropriate and acceptable treatment method for intertrochanteric hip fractures compared to sliding hip screws in terms of age, gender, fracture classification, operation time, blood loss, transfusions, complications, follow-up, length of stay, and hospital cost and can be used in

more complex fracture patterns.⁽¹³⁾ A **prospective study** by **Michael J. Gardner** et al stated that, for treatment of intertrochanteric hip fractures, particularly with comminuted fracture fragments, the trochanteric femoral nail has less cut-out rates, especially in osteoporotic bone and superiors to SHS from biomechanical and clinical parameters.⁽¹⁴⁾ A **prospective study** by **B. Fu** et al stated that, TFN is a safe and reliable technique. Compared with techniques like PFN and Gamma-nail, clinical results are excellent with fewer complications.⁽¹⁵⁾

Materials and Methods

The study was conducted on the patients at the Department of Orthopaedic surgery of Konaseema Institute Of Medical Science, Andhra Pradesh treated with short PFN, from June 2012 to June 2014.

Patient selection criteria:

- All the patients of with closed comminute unstable inter-trochanteric fracture femur attending the outdoor and emergency (AO A2.2 to A3.3).
- Skeletally mature patients.
- Ability to follow rehabilitation.
- Patients with associated fracture of upper limb were included.

Exclusion criteria were:

- Skeletally immature patients.
- Patients with pathological fractures.
- Patients with open fractures.
- Patients with associated neurovascular complications.

Sample size: 60 in number.

Study design: It is a prospective and without control study.

Study tools:

1. Radiograph
2. CT scan with 3-D-reconstruction
3. Image-intensifier
4. Radiolucent fracture table
5. Relevant surgical instruments and implants.

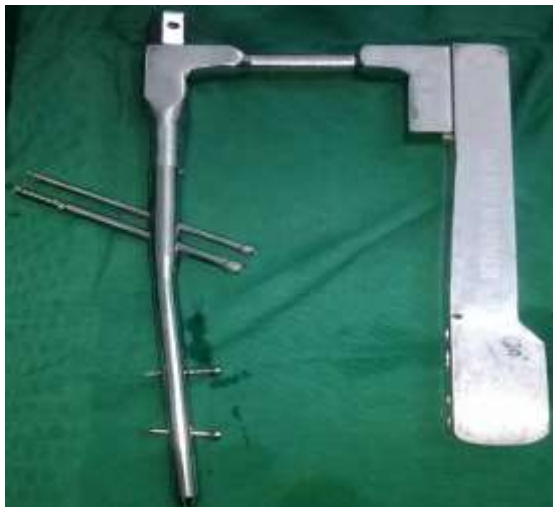Preoperative Evaluation: All the patients were preoperatively evaluated by X-rays, CT Scans with 3-D reconstruction (for better understanding of the fracture geometry in selected cases) and standard investigations for anaesthetic fitness.

Anatomy of the Short Proximal Femoral Nail (PFN):

- P.F.N. is a third generation cephalomedullary nail, made of ultra-high strength stainless steel alloy.
- The nail has a medio-lateral implant angle (6 degree) for easy insertion and longitudinal slots throughout the nail that accelerate regeneration of the endosteal blood supply.
- Nail sizes are 9, 10, 11 and 12 mm with a fixed length of 240 mm.
- Proximal cephalomedullary locking is achieved through one anti-rotation bolt or stabilization screw

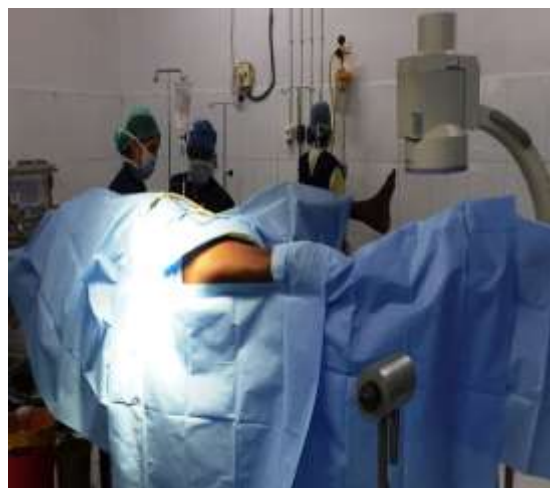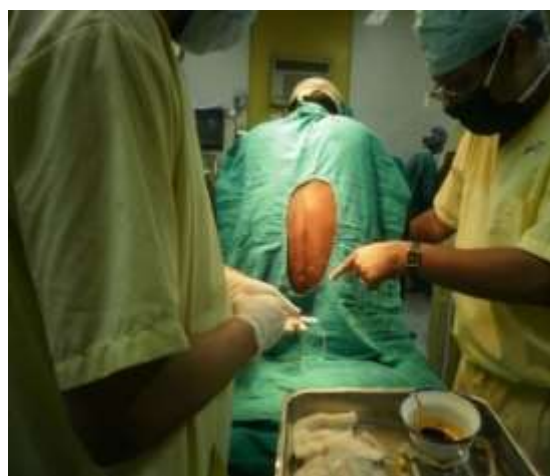and one femoral neck screw or cervical screw. Screws are parallel to each other. Cervical screw is 8 mm cannulated with length varying from 70 – 110 mm. Stabilization screw is 6.4 mm cannulated with length varying from 60 – 100 mm.

- Distal configuration allows static and dynamic locking. Distal locking screw is 4.9 mm in diameter.
- The angle between the nail and screw, we have used is 135 degree.



greater trochanter. A parallel incision in the fasciae of the gluteus medius and split the gluteus medius in line with the fibres is done.

Entry point(Fig. 2d): In AP view, the entry point is normally found on the tip or slightly lateral to the tip of greater trochanter in the curved extension of the medullary cavity and in lateral view at the junction of anterior one third and posterior two-thirds. Entry is made with curved awl over tip of greater trochanter. Enlarge the entry portal with cannulated reamer, which should be in mid plane of femur in both antero-posterior and lateral views.(Fig. 2a to 2j)



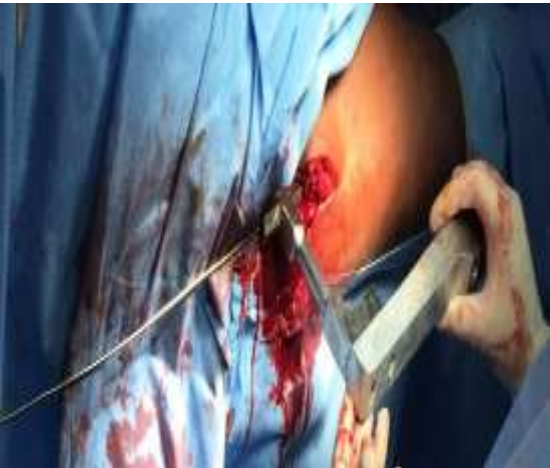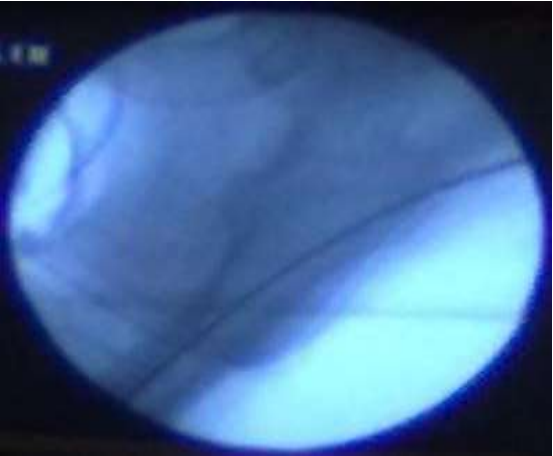
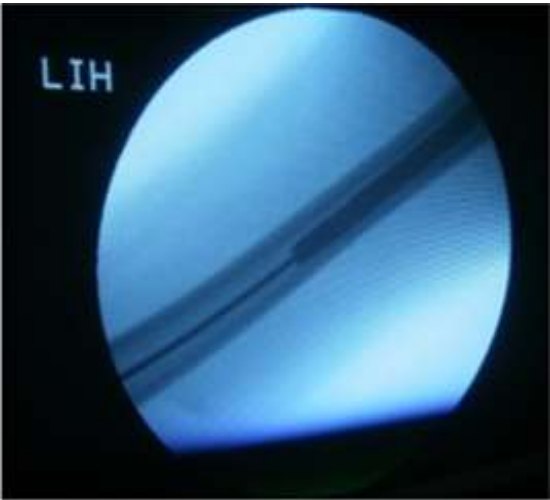
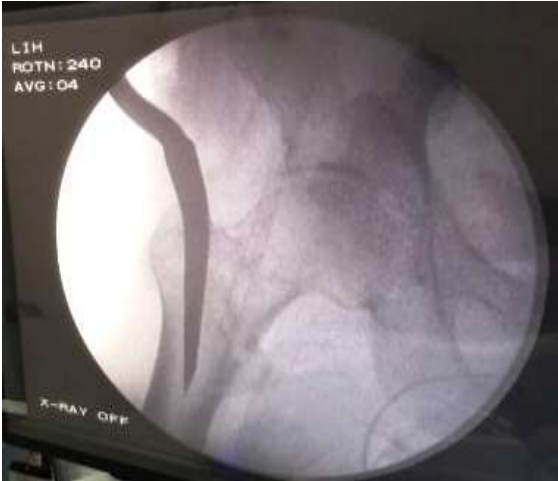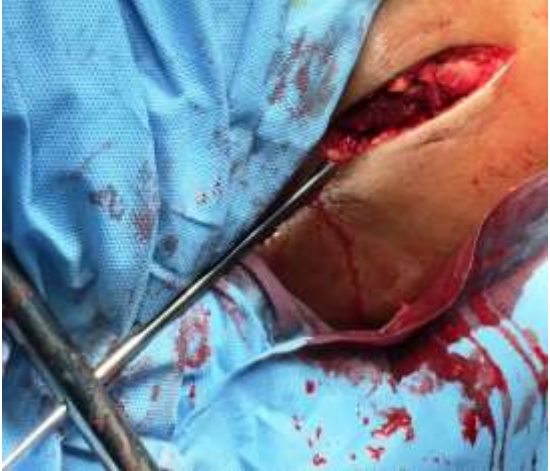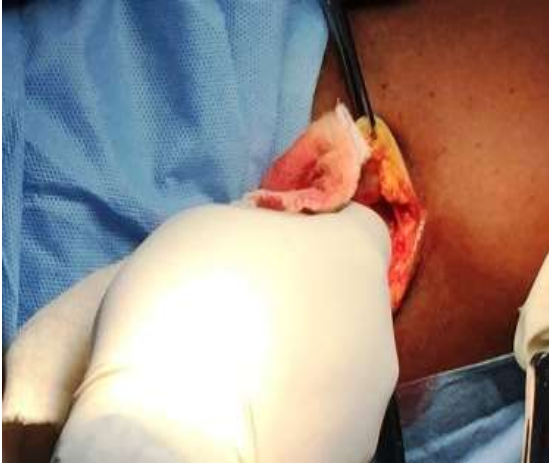Short PFN and associated instrumentation

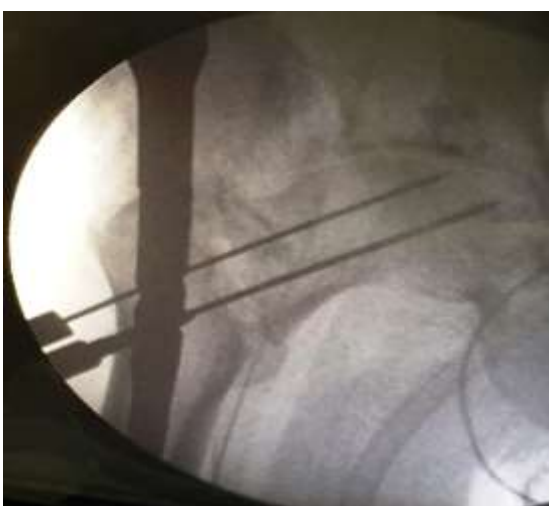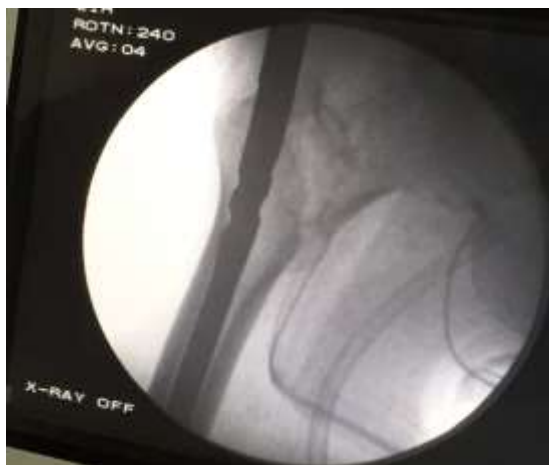Operative Steps

Anaesthesia(Fig. 2a): Regional (Spinal or Epidural) or General anaesthesia

Position(Fig. 2b): Supine on fracture table, position the C-arm of the image intensifier in such a way that it can visualize the proximal femur exactly in the AP and lateral planes. For unimpeded access to the medullary cavity, adduct the affected leg by 10–15°. If possible closed reduction of the fracture is done under image-intensifier; otherwise we opted for open reduction.

Incision(Fig. 2c): Greater trochanter is palpated. A 5cm incision is made just proximal from the tip of the





Nail insertion(Fig. 2h, 2i):Carefully insert the nail manually as far as possible into the femoral opening. Slight twisting hand movements help insertion. If the nail cannot be inserted, select a smaller size nail diameter. Insertion can be supported by light blows with the synthetic hammer on the mounted protection shield of the insertion handle.

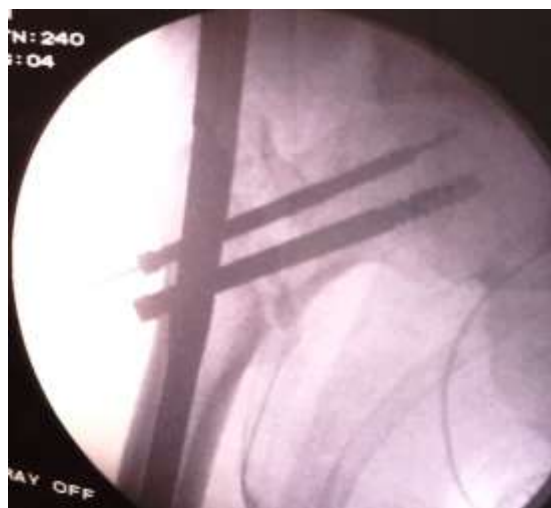

Fig. 3a: Proximal Locking

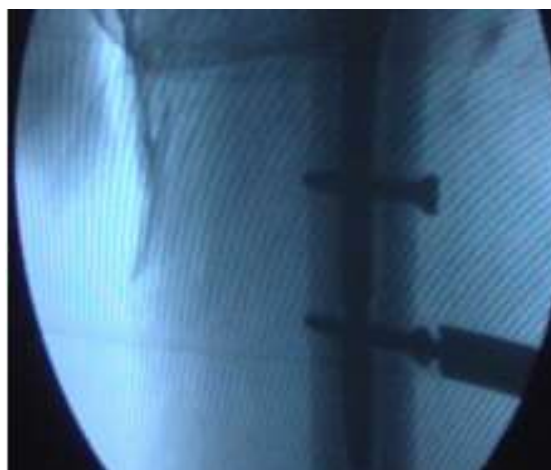

Fig. 3b: Distal Locking

Nail insertion proximal locking guide wire

Guide wire insertion(Fig. 2e): 2.00 mm-straight guide wire is inserted through protection sleeve laterally at an angle of 6 degrees to the shaft. Bent tip guide wire is used for severely displaced fractures. Fracture is reduced manually or with the help of Steinman pin and guide wire is passed in distal fragment. Guide wire position in distal fragment is confirmed on image intensifier on anteroposterior and lateral views.

Reaming(Fig. 2f, 2g): Using skin protector ream the femur with cannulated flexible reamer over guide wire in 0.5-mm increments until the desired diameter is reached. It is essential to over ream 1mm over the selected nail diameter for easy passage of the nail. At the end of the reaming proximal part of femur has been reamed with larger size hand reamer to adjust larger diameter of proximal part of nail. If guide wire is olive pointed, it should be exchanged with plain guide wire before nail insertion.

Assembling the nail: Nail is assembled to the jig with conical bolt so that the convexity of the nail (6 degrees medio lateral angle) faces medially and checked with drill guide and drill bit to see that, whether nail is matching with jig or not.

Caution

Avoid unnecessary use of force and only hit the protection plate. In smaller medullary canals, ream the distal part to at least 10mm. It is important that the nail is always tightly connected to the insertion Handle. Position of inferior screw should be checked under C-arm, it should be placed just superior to calcar in AP view and in central position in true lateral view of femoral head and neck so that proximal locking screws are inserted properly into the neck and head in both plane.

Proximal locking(Fig. 3a): Through a stab incision over the lateral thigh the drill sleeve is pushed up to the lateral cortex of femur with the help of a trocar. The

cervical guide pins for the load bearing cervical lag screw (8.0 mm) and for the derotation - hip screw (6.4mm) were passed into the head and neck using the guide pin sleeves under fluoroscopic control in the desired position. The guide pin is advanced upto 5 mm from the articular surface of the femoral head and reaming is done using corresponding cannulated drill bit with a guide wire in situ. The load bearing cervical lag screw of adequate length is inserted into the subchondral bone up to 5mm from the articular surface with the screw driver under image control, followed by the insertion of derotation - hip pin of adequate length into the upper half of neck.

Distal locking(Fig. 3b): Distal locking also is done with the aid of distal targeting guide and drill sleeves using 4.0 mm drill bit. Holes were made in the lateral and medial cortex of the femoral shaft through the distal holes of the nail and locking done by two 4.9 mm locking bolts and the position of the screws were confirmed with the C-arm.

Top screw application: Align the end cap with the nail axis using the hexagonal screwdriver in order to prevent tilting. Screw the end cap completely onto the nail until its collar touches the proximal end of the nail. Haemostasis secured, wound closed in layer and sterile dressing done.

Rehabilitation protocol

- Quadriceps strengthening exercises and active toe and ankle movements started from day-1.
- Patient is encouraged to sit by the side of bed with hip at 90 degree flexion and knee at 90 degree flexion and non-weight bearing active knee flexion started from day 3 or as soon as post-op pain subsides.
- Partial weight bearing is allowed as soon as possible as dictated by fracture geometry, post-operative reduction and stability of fixation approximately at 6 weeks.
- Full weight bearing given at 14-16 weeks on clinical and radiological evidence of union.

Follow-up

- Patients were evaluated clinically and radiologically at 3 weeks, 6 weeks, 10 weeks, 12 weeks, then bi-monthly for the next 9 months and yearly thereafter.
- Clinical union was observed as the absence of tenderness and pain with full weight bearing.
- During follow up the Harris hip score was evaluated at 10wks, and 14wks post operatively. Various parameters like pain, limp, use of support, distance walked sitting, stair climbing, absence of deformity, range of motion were evaluated using the Harris hip score.
- Based on the RADIOLOGY, the following indices were recorded: fracture union, extent of fracture

collapse, medial displacement, neck-shaft angle alteration and implant failure.

Observation

We have treated 60 inter-trochanteric fractures with short proximal femoral nail and the results are compiled, analysed and data is presented.

Table1: Age distribution

Age Group (yrs.)	No.	%
31-40	9	15
41-50	18	30
51-60	20	33.33
61-70	10	16.66
>70	3	5
Total	60	100
Mean	53.1 Yrs	

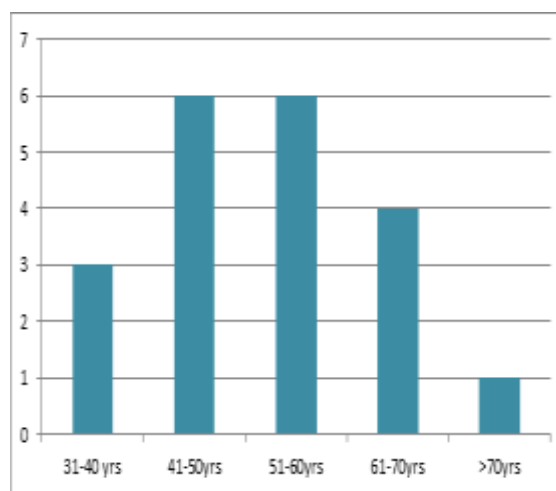


Fig. 4

The mean age was 53.1 years.
(Range: 31 to 73 years)

Table 2: Sex incidence

Sex	No of Cases	%
Male	45	75
Female	15	25
Total	60	100

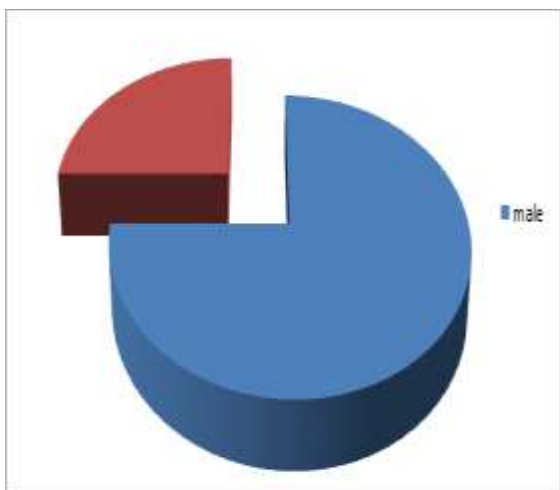


Fig. 5

In our series the sex incidence is M: F=3:1 (25 % were females and 75% were males).

Table 3: Mechanism of injury

Mechanism of Injury	No of Cases	Percentage
RTA	47	78.33
Accidental Fall	13	21.66
Total	60	100

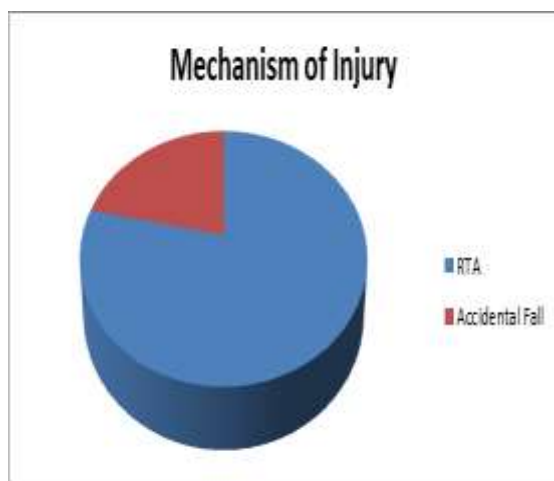


Fig. 6

In our series major trauma was due to road traffic accident (78.33%), whereas 21.66% fractures occurred due to accidental fall from height, especially in elderly population.

Table 4: Side of the affected femur

Side	No of cases	Percentage
Right	34	56.66
Left	26	43.33
Total	60	100

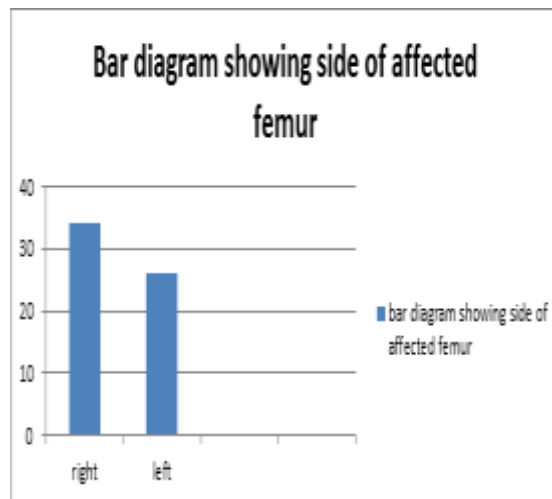


Fig. 7

In our study right sided femur is more commonly involved compared to left side.

Table 5: Time interval of operation from injury

Time Elapsed (days)	No. of Cases	Percentage
0-5	32	53.33
6-10	25	41.66
11-15	2	3.33
16-20	1	1.66
Total	60	100
Mean time of interval	6 days	

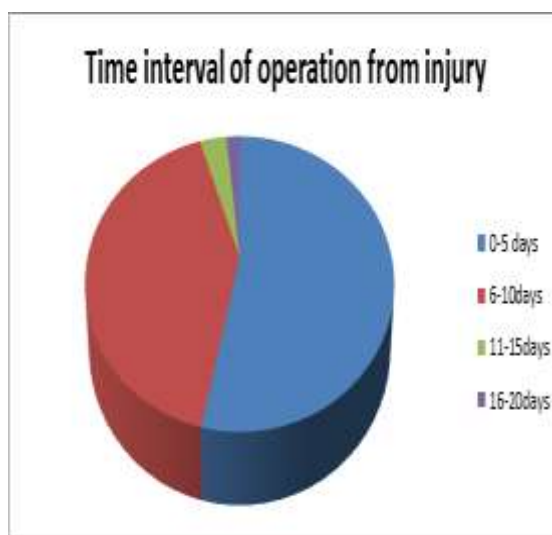


Fig. 8

In our study mean time of interval between and surgery was 6 days (range 2 to 19 days). 95% cases were operated within 10 days and 53.33% were operated between 0-5 days of admission. Cases which

are associated with other injuries and co morbid conditions were operated later on.

Table 6: Associated injury

Associated Injury	No. of Cases	Percentage
Ipsilateral Both bone FA #	3	5
Ipsilateral colle's	6	10
Ipsilateral Clavicle #	3	5
Contralateral trochanteric fracture	2	3.33
chest injury	1	1.66
Ipsilateral Radius #	1	1.66
Headinjury(concussion)	3	5
Total	19	31.66

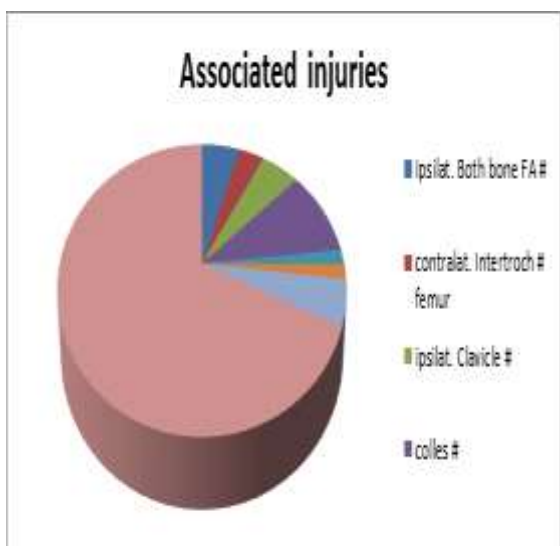


Fig. 9

In our series regarding associated fractures, colles # was most frequent, both pts were elderly. Others asso. fractures were ipsilateral Both bone FA #, contralateral Intertrochanteric # femur, ipsilateral Clavicle #, chest injury, ipsilateral Radius # and Head injury mostly in road traffic accident cases.

Table 7: Duration of surgery

Duration of Surgery (Minutes)	No. of Cases	%
<60	3	5
60-90	53	88.33
90-120	2	3.33
120-150	2	3.33
TOTAL	60	100
Mean time required	82 minutes	

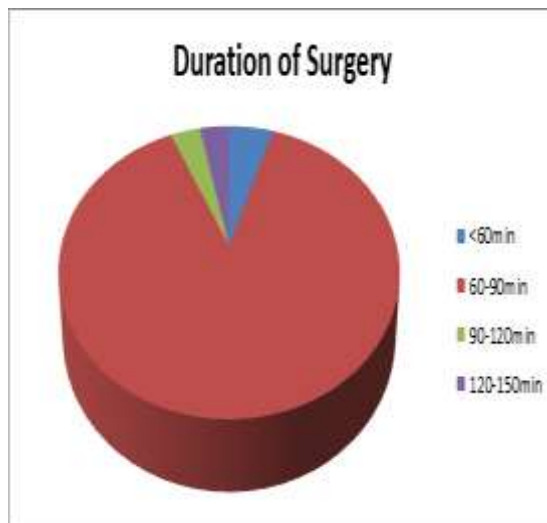


Fig. 10

Average duration of surgery in our series was 82 min. Minimum time required was 55 min and maximum time required is 140 min.

Table 8: Exposure of radiation from C-arm machine in seconds

Exposure of Radiation from C-Arm	No. of Cases	%
90-120	15	25
120-150	30	50
150-180	15	25
Total	20	100
Mean exposure of radiation	105.5 sec	

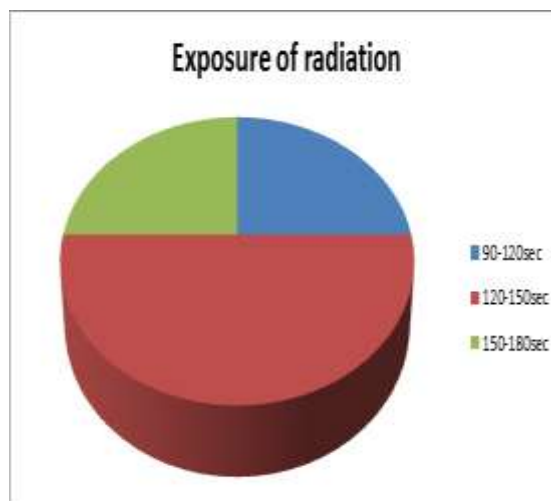


Fig. 11

The usage time for image intensifier was 105.5 seconds. Minimum exposure was 90 sec and maximum was 160 sec.

Table 9: Complications

Complications	No. of Cases	%
Surgical Site Infection (Superficial)	2	3.33
Surgical Site Infection (Deep)	1	1.66
Varus deformity with abductor lurch	3	5
Joint stiffness	3	5
Limb shortening	1	1.66

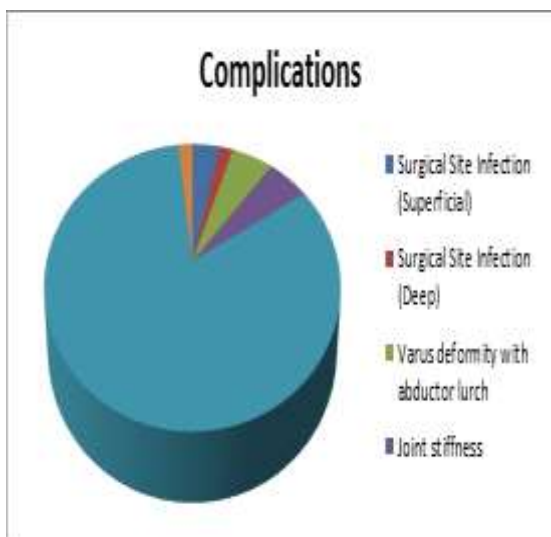


Fig. 12

Table 10: Blood transfusion

No. of Unit	No. of Cases	%
1	6	10
2	3	5
Total	9	15

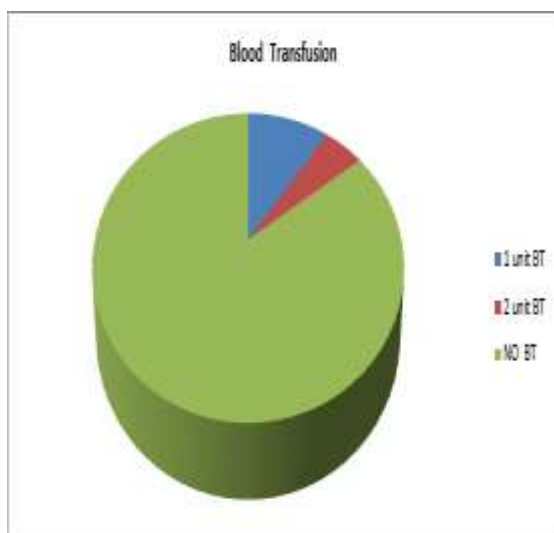


Fig. 13

In our series, 85% cases do not required blood transfusion. Rest 10% cases required single unit blood transfusion and 5% cases needed two units.

Table 11: Harris Hip score

	Excellent (≥90)	Good (80-89)	Fair (70-79)	Poor (<70)
At 10 wks	-	38	18	4
At 14 wks	16	34	7	3
At 18wks	40	11	6	3
At 24wks	42	10	5	3
At 36wks	49	7	1	3
At 1yr	51	5	1	3
At 2yrs	51	5	1	3

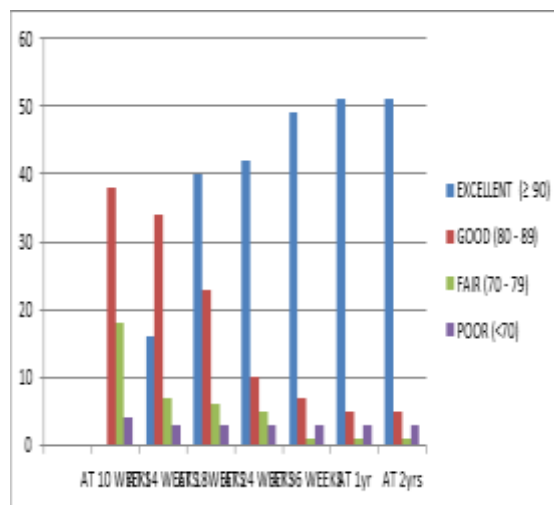


Fig. 14

At 10 weeks 93.33% of cases scored fair to Good results and at 14 weeks 95% cases scored more than 70 and most of them were in good to excellent category. Three cases (5%) showed poor result with joint stiffness and arthritic changes.

Table 12: Time taken for union

Union Time	No. of Patients	Percentage
By 10 weeks	9	15
By 14 weeks	31	51.66
By 18 weeks	20	33.33

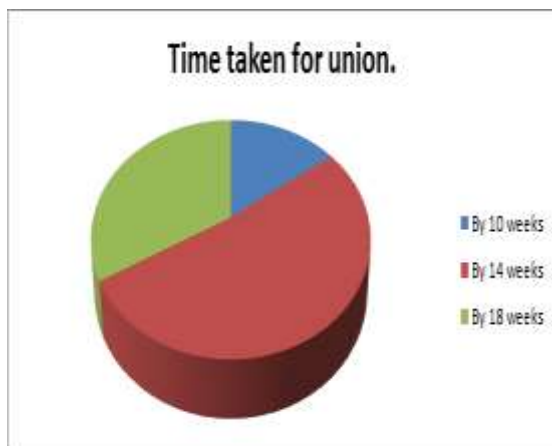


Fig. 15

In our series all cases shows union. 9 cases (15%) had united in around 10 weeks and 31 cases (51.66%) had united around 14 week and 20 cases (33.33%) were united within 18 weeks. No experience of delayed union and non-union in this study.

Discussions

In our study mean age of 60 patients was 53.1 years range (31-73) yrs. In Celebi et al⁽¹⁷⁾ series average age was 39.1 years. In our series, 75% were male and 25% were female patients; (M:F=3:1). In Celebi et al⁽¹⁷⁾ series 27.3% were females and 72.7% were males. In our study 56.66% of right and 43.33% left sided femur were involved (rt 34/ lf 26). Majority of these fractures were caused by road traffic accident (78.33%). Sadowski et al⁽¹⁸⁾ in his series had reported 95% cause of high velocity trauma. In our series major trauma was due to road traffic accident whereas 21.66% fractures occurred due to accidental fall from height especially in elder population. In our study mean time of interval between injury and surgery was 6 days (range 2 to 19 days). Comparable with the series of Sadowski et al⁽¹⁸⁾ and Boldin C et al⁽¹⁹⁾ which operated on 6th day 35% and 33% respectively. Cases which are associated with other injuries and co morbid conditions were operated later on. In our series regarding associated fractures, colles # was most frequent, mostly in elderly people. Other long bone fractures and head injury and chest injury are mostly related with road traffic accident. This study is comparable with series of Sadowski et al⁽¹⁸⁾. Average duration of surgery in our series was 82 min, range (55-140) min, comparable with Celebi et al⁽¹⁷⁾ series-110 min. As experience gained over time the duration gradually decreases. Cases operated after closed reductions were completed earlier. The mean usage time for image intensifier was 105.5 seconds, range (90-160). Results were higher than the series Kostal. R et al 2003⁽²⁰⁾ of 80 sec and Pavelka. T et al 2003 of 90 sec.⁽²¹⁾ Newer technique to start with initially and lack of expert C-arm technician is probably the cause for higher radiation exposure in comparison

with other studies. In our series, 85% cases do not required blood transfusion, which have been done after closed reduction. Three cases needed two units depending upon the OT duration and intra-operative blood loss. Among them two cases required open-reduction, those in which injury operation interval was longer due to medical co-morbidities. Results were corroborative with the study by Sadowski et al⁽¹⁸⁾. In our series all cases showed union. 9 cases (15%) had united in around 10 weeks and 31 cases (51.66%) had united around 14 week and 20 cases (33.33%) were united within 18 weeks. No experience of delayed union and non-union in this study. In the studies by A. Lenich et al⁽¹⁵⁾ and Ekstrom et al⁽²²⁾ reported no case of non-union in their series. Sadowski et al (2002)⁽¹⁸⁾ reported a 5.6% rate of non-union. Complications regarding union are related to fracture pattern, prolonged injury-operation interval, per-operative reduction and post-operative complications especially varus collapse.⁽¹⁸⁾ Regarding Harris Hip score in our study, at 10 weeks, as most of the patients were allowed partial wt bearing, 93.33% of cases scored fair to Good results and at 14 weeks 95% cases scored more than 70 and most of them were in good to excellent category. Three cases (5%) showed poor result. Both of them were had multiple co-morbidities and did not performed rehabilitation exercises post-operatively. Our results were corroborative with the study by Ruecker AH et al 2009, Harris hip score (75.1 +/- 13.4) at 16 weeks⁽²³⁾ and with the study by Loubignac F et al 2009, mean Harris Hip Score 80 at 16 weeks.⁽²⁴⁾

Regarding the complications we have encountered, most common **per-operative** problem was difficulty in nail-jig assembly. The entire procedure is highly technically demanding: so proper maintenance of the instrument assembly is vital. Another difficulty was locating the correct entry point over fractured trochanter. A good quality fracture table with adjustable perineal post is also necessary for sufficient adduction of the extremity so that, the awl can be guided in proper direction.

In **post-operative** period, superficial surgical site infection occurred in two cases; both were cured after proper intravenous antibiotics and sterile dressing. One case, which had history of uncontrolled diabetes, had deep surgical site infection which cured after repeated debridement and antibiotics under strict insulin coverage. Four patient developed varus deformity with abductor lurch due to collapse of the medial cortex. But fortunately all of them were united, and limb shortening of 1cm and 2cm occurred in two of them only. Knee joint stiffness was seen in five patients, all of them were elderly and habituated to sedentary lifestyles, and did not follow the rehabilitation protocol properly. Neck screw cut-out, Z effect and reverse Z effect has not been encountered. No major systemic complications has been dealt with.

The proximal femoral nail is an effective load bearing device that incorporates the principles and theoretical advantages of all the intra medullary devices⁽²⁷⁾. The larger proximal diameter of PFN imparts additional stiffness to the nail. It also combines the advantages of closed intramedullary nailing, a dynamic femoral neck screw, minimal blood loss, shorter operative time and early weight bearing than DHS^(26,27). The lateral entry point of PFN is convenient as many patients needing this procedure are elderly and therefore less active; resulting in them being overweight and for them PFN is the ideal implant^(28,29). Patients with narrow femoral canal and abnormal curvature of the proximal femur are the relative contra indications to intra medullary fixation with PFN^(30,31). The gamma nail and the long PFN are plagued with technical and mechanical failure rates of about 4-18%^(32,33,34,35,36). To eliminate these technical and biomechanical failures, the short Proximal Femoral Nail (PFN) has been devised. Multiple factors have been implicated like implant design, fracture stability, operative technique, surgeon skills & learning curve in the outcome of good results. Limitation of our study is lack of control group.

Summary

- Sixty patients with unstable trochanteric fracture (AO A2.2-A3.3) were treated by short Proximal Femoral Nail (PFN) between June 2012 to June 2014.
- It is a prospective study and without control.
- Most of the patients were male (75%), 78.33% of all patients were suffered from RTA, rest due to accidental fall.
- Regarding associated fractures, Colles # was most frequent, both were in elderly people. Other long bone fractures and head injury (concussion) and chest injury are mostly related with road traffic accident.
- 95% cases were operated within 10 days of injury, rest 53.33% within 5 days of injury.
- Average duration of surgery was 82 min, range (55-140) min. As experience gained over time the duration gradually decreases. Cases operated after closed reductions were completed earlier.
- The mean usage time for image intensifier was 105.5 seconds, range (90-160).
- 85% cases do not required blood transfusion, which have been done after closed reduction. 10% cases required single unit transfusion and rest 5% cases required two units of transfusion.
- All cases shows union. 9 cases (15%) had united in around 10 weeks and 31 cases (51.66%) had united around 14 week and 20 cases (33.33%) were united within 18 weeks. No experience of delayed union and non-union in this study.

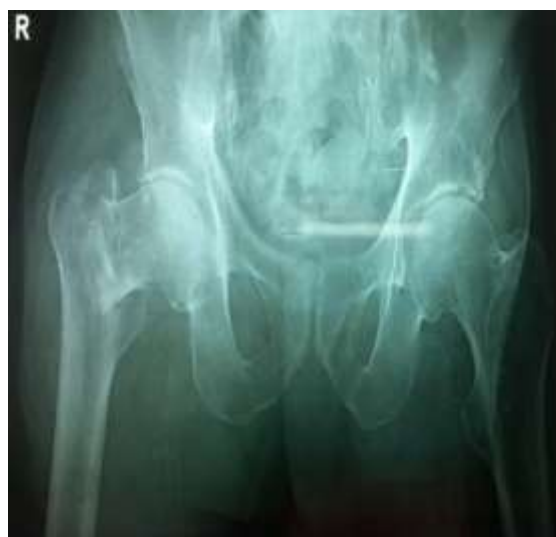- Regarding Harris Hip score, at 10 weeks, as most of the patients were allowed partial wt bearing, 93.33% of cases scored fair to Good results and at 14 weeks 95% cases scored more than 70 and most of them were in good to excellent category.
- Regarding per-operative problem, nail-jig mismatch, locating correct entry point especially in severely comminuted trochanter and obese patients are common.
- Regarding post-operative problems, three patients developed varus deformities with abductor lurch, limb shortening occurred in one of them. Surgical site infection had been tackled effectively. No systemic complications had been encountered.

Conclusions

Proximal femoral nail is more advantageous as it has:

- Greater resistance to cut out,
- Improved resistance to varus collapse,
- Improved resistance to femoral head rotation,
- Less surgical trauma,
- Less amount of blood loss and,
- Early active mobilisation compared to the plate-screw system⁽³⁷⁾.
- It also has advantage over Gamma nail in rotational stability of proximal fragment and over long PFN in reduction in the complication rate of femoral shaft fractures^(38,39).

Finally, we conclude that the Short Proximal femoral nail (PFN), is an acceptable minimally invasive implant and when used in unstable trochanteric fractures is more advantageous from biological & biomechanical point of view and has been emerged as a good therapeutic option with excellent outcome.



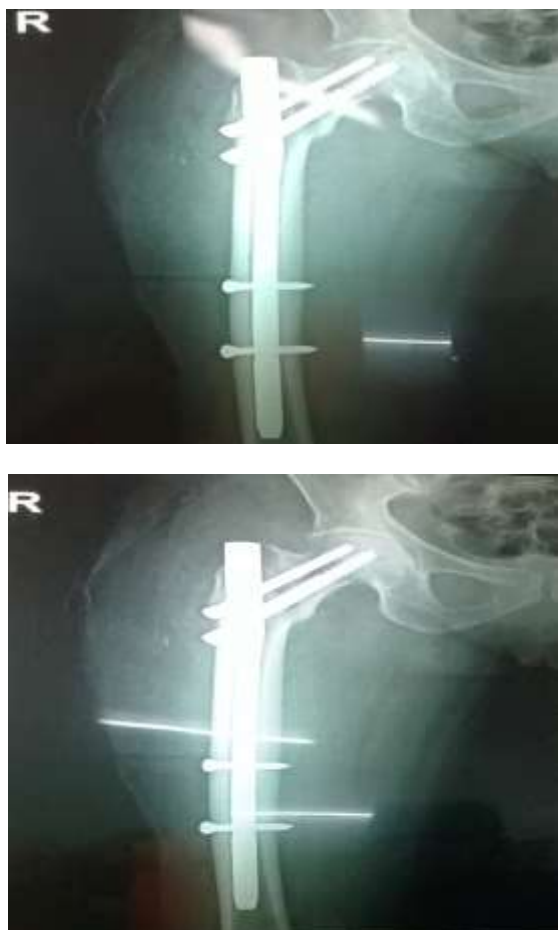

Fig. 16

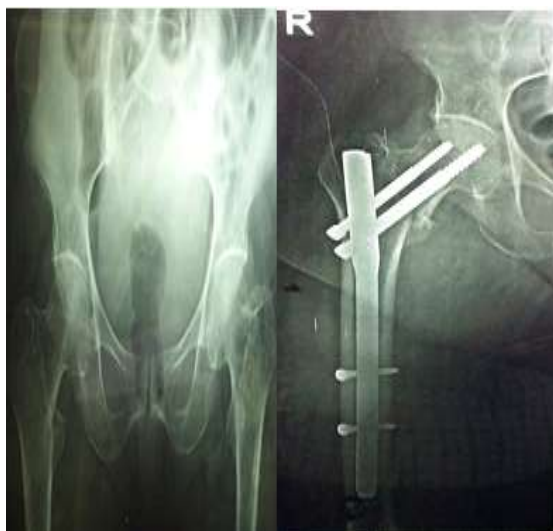
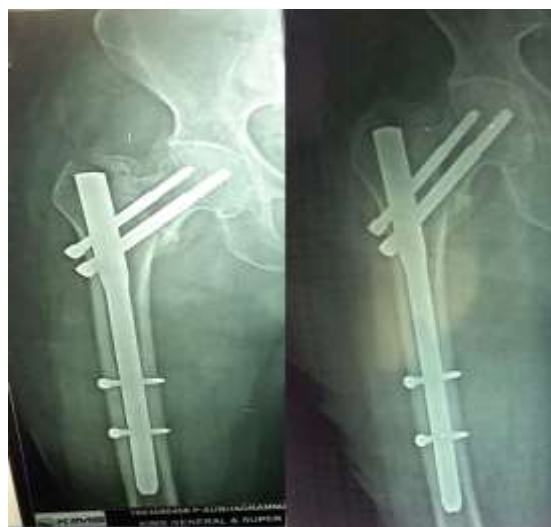
Fig. 17: (At presentation) immediate post-op



Post-op 3 months

Post-op 6 months

Bibliography

1. S. R. Cummings, S. M. Rubin, and D. Black, "The future of hip fractures in the United States. Numbers, costs, and potential effects of postmenopausal estrogen," *Clinical Orthopaedics and Related Research*, no. 252, pp. 163–166, 1990.
2. Adams CI, Robinson CM, Court-Brown CM, McQueen MM. Prospective randomized controlled trial of an intramedullary nail versus dynamic screw and plate for intertrochanteric fractures of the femur. *J Orthop Trauma*. 2001;15:394-400.
3. Gupta R.K., Sangwan K., et al: Unstable Trochanteric Fractures: the role of lateral wall reconstruction. *International Orthopaedics (SICOT)*,34:125-129,2010.
4. T Morihara, Y Arai, S Tokugawa, S Fujita, K Chatani, T Kubo *Journal of Orthopaedic Surgery* 2007;15(3):273-7
5. Bendo JA, Weiner LS, Strauss E, Yang E. Collapse of intertrochanteric hip fractures fixed with sliding screws. *Orthop Rev*. 1994;(Suppl):30-37.
6. Davis TR, Sher JL, Horsman A, Simpson M, Porter BB, Checketts RG. Intertrochanteric femoral fractures. Mechanical failure after internal fixation. *J Bone Joint Surg Br*. 1990;72:2631.
7. Bridle SH, Patel AD, Bircher M, Calvert PT. Fixation of intertrochanteric fractures of the femur. A randomised prospective comparison of the gamma nail and the dynamic hip screw. *J Bone Joint Surg Br*. 1991;73:330-334.
8. Simmermacher RK, Bosch AM, Van der Werken C (1999) The AO/ASIF-proximal femoral nail (PFN): a new device for the treatment of unstable proximal femoral fractures. *Injury* 30(5):327–332.
9. C Zeng, Y-R Wang et al Treatment of Trochanteric Fractures with Intramedullary nail antirotation or Dynamic Hip Screw system: A Meta-analysis. 2012 *JIMS* 40.839-851.
10. Henrik Palm, Charlotte Lysén et al Intramedullary nailing appears to be superior in pertrochanteric hip fractures with a detached greater trochanter. *Acta Orthopaedica* 2011;82(2):166–170.
11. Christophe Sadowski, Anne Lübbecke Treatment of Reverse Oblique and Transverse Intertrochanteric Fractures with Use of an Intramedullary Nail or a 95° Screw-Plate. 2002 BY THE JOURNAL OF BONE AND JOINT SURGERY 41.372.

12. Outcome of 3rd Generation Short Cephalomedullary Fixation of Unstable Intertrochanteric Femur Fractures in a Geriatric Population Aron Chacko, Edward Rodriguez et al J Orthop Trauma. 2005 Apr;19(4):229-33.
13. Intertrochanteric hip fractures treated with the trochanteric fixation nail and sliding hip screw. GILL JB, JENSEN L et al Journal of Surgical Orthopaedic Advances [2007, 16(2):62-66]
14. Treatment of intertrochanteric hip fractures with the AO Trochanteric Femoral Nail. Michael J. Gardner; Mohit Bhandari et al. Healio Orthopaedics February 2005 - Volume 28•Issue 2.
15. First results with the Trochanter Fixation Nail (TFN): a report on 120 cases. A. Lenich, E. Mayr et al. Springer-Verlag Aug 2006.
16. D. Haverkamp, H. Eijer, P. P. Besselaar, and R. K. Marti Awareness and use of intertrochanteric osteotomies in current clinical practice. An international survey Int Orthop. 2008 February;32(1):19–25.
17. Celebi L, Can M, Muratli HH, et al. Indirect reduction and biological internal fixation of comminuted intertrochanteric fractures of the femur. Injury. 2006;37:740-750.
18. Sadowski C, Dieter M. Lindskog and Michael R. Baumgaertner Unstable Intertrochanteric Hip Fractures in the Elderly J Am Acad Orthop Surg May/June 2004;12:179-190.
19. Boldin C, Seibert F, Fankhauser F et al. The trochanteric femoral nail (TFN)- a minimal invasive treatment of unstable proximal femoral fractures. A prospective study of 55 patients with a follow up of 15 months. Acta Orthop Scand 2003;74:53-58.
20. Kostal R, Dousa P, Bartonicek J. The proximal femoral nail (PFN)—another alternative for osteosynthesis of trochanteric fractures, Rozhl Chir 2003 Jan;82(1):28-31.
21. Pavelka T, Kortus J, Linhart M. Osteosynthesis of trochanteric fractures using proximal femoral nails, Acta Chir Orthop Traumatol Cech, 2003;70(1):31-8.
22. Ekstrom W, Karlsson-Thur C, Larsson S, et al. Functional outcome in treatment of unstable trochanteric and Subtrochanteric fractures with the Proximal femoral nail and Medoff sliding plate. J Orthop Trauma. 2007;21:18-25.
23. Ruecker AH et al The treatment of intertrochanteric fractures: results using an intramedullary nail with integrated cephalocervical screws and linear compression. J Orthop Trauma. 2009 Jan;23(1):22- 30.
24. Loubignac F et al A newly designed locked intramedullary nail for trochanteric hip fractures fixation: results of the first 100 Trochanteric implantations. Orthop Traumatol Surg Res. 2009 Apr;95(2):139-44.
25. Schipper IB, Bresina S, Wahl D, Linke B, Van Vugt AB, Schneider E. Biomechanical evaluation of the trochanteric femoral nail, Clin Orthop Relat Res, Dec;(405):277-86.
26. Dousa p, Bartonicek J, Jehlicka D, Skala-Rosenbaum J. Osteosynthesis of trochanteric fractures using trochanteric femoral nails, Acta Chir Orthop Traumatol Cech, 2002;69(1):22-30.
27. Leung KS, So WS, Shun WY, Hui PW. Gamma nails and dynamic hip screws for peritrochanteric fractures: a randomized prospective study in elderly patients, J Bone Joint Surg (Br) 1992;74-8:345-51.
28. <http://www.edoctor.co.in/#/dynamic-hip-screw/4529649829>.
29. Lin J (2007) Encouraging results of treating femoral trochanteric with specially designed double-screw nails. J Trauma 63:866–874.
30. Haidukewych GJ (2009) Intertrochanteric fractures: ten tips to improve results. J Bone Joint Surg Am 91:712–719.
31. Kaplan K, Miyamoto R, Levine BR et al (2008) surgical management of hip fractures: an evidence-based review of the literature. II: intertrochanteric fractures. J Am Acad Orthop Surg 16:665–673.
32. Friedl W, Colombo-Benkmann M, Colombo-Benkmann M, Machens HG, Mieck U (1994) Gamma nail osteosynthesis of per- and Subtrochanteric femoral fractures. 4 years experiences and their consequences for further implant development. Chirurg 65(11):953–963.
33. Fritz T, Hiersemann K, Kriegelstein C, Friedl W (1999) Prospective randomized comparison of gliding nail and gamma nail in the therapy of trochanteric fractures. Arch Orthop Trauma Surg 119(1–2):1–6.
34. Nuber S, Schonweiss T, Rueter A (2003) Stabilisation of unstable trochanteric femoral fractures. Dynamic hip screw (DHS) with trochanteric stabilisation plate vs. proximal femur nails (PFN). Unfallchirurg 106(1):39–47.
35. Cochrane library; Parker MJ, Handoll HH (2003) Gamma and other cephalocondylic intramedullary nails versus extramedullary implants for extracapsular hip fractures. Cochrane database syst. rev (1) CD000093.
36. Simmermacher RK, Bosch AM, and Van der Werken C (1999) The AO/ASIF-proximal femoral nail (PFN): a new device for the treatment of unstable proximal femoral fractures. Injury 30(5):327–332.
37. CHRISTOPHER SADOWSKI et al Surgical Management of Hip Fractures: An Evidence-based Review of the Literature. II: Intertrochanteric Fractures J Am Acad Orthop Surg 16:495–523.
38. Al-yassari G, Langstaff RJ, Jones JW, Al-Lami M LA (2002) The AO/ASIF proximal femoral nail (PFN) for the treatment of unstable trochanteric femoral fracture. Injury 33(5):395–399.
39. Werner-Tutschku W, Lajtai G, Schmiedhuber G, Lang T, Pirkl C, Orthner E (2002) Intra- and perioperative complications in the stabilization of per- and Subtrochanteric femoral fractures by means of PFN. Unfallchirurg 105(10):881–885.