

Management of fracture neck of femur in elderly by hemiarthroplasty: A study

Maruthi CV^{1,*}, Shivanna²

¹Associate Professor, ²Senior Resident, Dept. of Orthopaedics, CIMS, Chamarajanagar

*Corresponding Author:

Email: orthocvmaruthi@gmail.com

Abstract

Background and Objectives: This is a prospective study of fifty cases of intracapsular fracture neck of femur in elderly patients above the age of 60 years irrespective of sex which were treated by hemiarthroplasty using Austin moore's/ bipolar endoprosthesis, in the Department of Orthopedics at our institute. Patients were followed up and functional results were analyzed with the objectives to study the age and sex incidence of fracture neck of femur, quality of life after hemiarthroplasty, morbidity and mortality associated with the procedure, recovery of physical, social and occupational independence.

Methods: Fifty cases of fracture neck of femur in elderly patients above the age of 60 years were treated by hemiarthroplasty using either Austin Moore's, or bipolar prosthesis in the Department of Orthopedics from November 2008 to November 2013. The cases were followed up for 6 months and the short term functional results were analyzed by using modified Harris hip scoring system.

Results: The patients who had fracture neck of femur and who underwent hemiarthroplasty were in the age group of 60 to 98 years with mean average age of 69.82 years. Females were predominant. Majority of the fractures were sub-capital by radiological diagnosis. In 78 percent cases the mode of injury was trivial trauma. Hypertension, diabetes mellitus and chronic obstructive pulmonary disease were the common associated medical conditions. The post-operative complications observed were bedsores, periprosthetic fracture and posterior prosthetic dislocation. A six month follow up was done. One patient expired and four cases were lost for follow up. Thus the functional results were analyzed in the remaining 45 cases. There were 22.2% excellent results and 40% good results. Results of Austin Moore and bipolar prosthesis were not compared as the data and time period of the study was not enough to reach a statistical significance.

Interpretation and Conclusion: The success of hemiarthroplasty depends on preoperative planning and proper attention to surgical details to achieve the optimum biomechanical stability. The poor results (15.56%) were due to moderate to marked pain in the hip or thigh after hemiarthroplasty. We conclude that hemiarthroplasty for fracture neck of femur is a good option in elderly patients. The morbidity and mortality are minimal, complications are less disabling and early functional results are satisfactory.

Key Words: Hemiarthroplasty, Femoral neck fracture, Austin Moore's, Bipolar, Short term

Access this article online	
Quick Response Code:	Website: www.innovativepublication.com
	DOI: 10.5958/2395-1362.2016.00034.7

Introduction

The evolution from quadrupeds to anthropoid and anthropoid to human mode of progression, has involved a big strain on hip, for it has to carry double the weight and also has to provide for balancing of the erect body, thus making hip joint the most important joint in the body, and in regard to its ailments is certainly the most difficult for treatment. One of the most common ailments of the hip joint is fracture neck of femur. In recent years the incidence of fracture neck of femur is increasing in the elderly and is the commonest injury causing morbidity and mortality in patients of geriatric age group. With improvements in standards of health, longevity and age related osteoporosis, the fracture is being increasingly encountered. Fracture neck of femur has always been a challenge for orthopedic surgeons all over the world and in many ways still remains largely

unsolved as far as treatment and results are concerned. The healing, complications like non-union and avascular necrosis are a matter of concern. The prolonged immobilization in elderly will jeopardize the life span of patient and further complicates the problem. This forces one to totally abandon the complete immobilization to achieve a bony union, or to restore early ambulation by surgery. Among several other methods of treatment of fracture neck of femur, hemiarthroplasty has emerged as an effective modality in the management of intracapsular fracture neck of femur in elderly patients. The Austin-Moore's prosthesis and Thompson's prosthesis were designed for older individuals whose demand for activity was very low. In modern days the bipolar prosthesis with cement is the best option wherein they can be more active, especially the modular bipolar prosthesis with or without cement can give a very good active life to the patients treated. Further the modular stem can be retained in case the patient needs a total hip replacement at a later date. Further some surgeons would like to do total hip replacement in older patient, as a primary procedure. In spite of all the developments in field of replacement surgery most surgeons still prefer to do hemiarthroplasty as primary procedure as it is always possible to do total hip replacement at a later date. This study is aimed at evaluating the outcome of hemiarthroplasty, by assessing the quality of life and

degree of function in the operated limb.

Methodology

We studied 50 cases of intracapsular fracture neck of femur in elderly patients above the age of 60 years irrespective of sex treated by hemiarthroplasty using Austin Moore's or bipolar endoprosthesis, in the Department of Orthopedics at our institute from November 2008 to November 2013. The study was carried out to evaluate the immediate and early results of hemiarthroplasty for intracapsular fracture neck of femur in elderly. The inclusion criteria were the patients aged above 60 years irrespective of sex, fracture's which were intracapsular (either sub-capital or transcervical), non-impacted, varus impacted, type-II, III and IV of Garden's classification. Exclusion criteria were the patients aged less than 60 years, intracapsular-valgus impacted (Type-I Garden) fractures and pathological fractures due to malignancies. The patients with impaired cognition, limited activity and less life expectancy were treated with Austin Moore's prosthesis and patients who were with good cognitive function and activity with higher life expectancy were treated with cemented bipolar prosthesis^{1,2,3,4}. We operated twenty two patients with uncemented Austin Moore's prosthesis and twenty eight patients with cemented bipolar prosthesis. If cement is used for Austin Moore's prosthesis, there will be high incidence of technical errors in placing the implant subsequently loosening and revision surgery^{1,5,6}. The holes present within the implant helps in natural bone growth which aids in stability. Bipolar prosthesis has got smoother surface which favours in bridging the implant cement interface. All our fifty cases treated by hemiarthroplasty were followed up for 6 months. At the end of 6 months following surgery, 1 patient died and 4 patients lost for follow up. The functional results after hemiarthroplasty were therefore analyzed for the remaining 45 patients. Once the patient was admitted to the hospital, all the essential information was recorded in the proforma prepared for the study. They were observed regularly during their hospital stay till they get discharged. They were asked to come for follow up regularly to the outpatient department. The follow up summary was recorded in the follow up chart of the proforma.

Preoperative Management

Patients were admitted to the ward. Detailed history was taken with particular emphasize on mode of injury and associated medical illness. Clinical assessment was carried out in each case. In all patients, preoperative Buck's traction with appropriate weight was applied to the fractured lower limb, with the aim of relieving pain, to prevent shortening and to immobilize the involved lower limb. Oral or parental non-steroidal anti-inflammatory drugs were given to relieve the pain. Anteroposterior radiographs of pelvis with both hip joints were taken for all the patients, keeping the

fractured limb in 15° internal rotation to bring the neck parallel to X-ray film. Routine blood investigations, blood grouping and typing, urine routine, random blood sugar, serum urea, creatinine, hepatitis B antigen, human immune deficiency virus, chest X-ray, electrocardiogram were done in all cases. Necessary and adequate treatment was given for those associated with medical problems such as diabetes, hypertension, ischemic heart disease, chronic obstructive pulmonary disease were evaluated and treated before taking them to surgery. Certain therapeutic exercises were taught preoperatively on the normal side which was asked to perform postoperatively on the affected side, such as static quadriceps exercises and ankle movements⁷. Patients as well as the attenders were explained about the surgery and its risk factors and written consent for the surgery was taken for all patients. Intravenous antibiotics and tetanus immunization were given an hour before the surgery. The limb was prepared from nipple to knee including perineum and back.

Surgical Procedure (Fig. 1)

All surgeries were performed on an elective basis using standard aseptic precautions. Surgery was performed under spinal or epidural anaesthesia. The patient was put in the lateral position over the unaffected side. The skin over the hip was scrubbed with povidone-iodine. The lower extremity from the groin to the toes was draped in sterile towels separately to enable easy manipulation of the limb during surgery. For all patients, posterior approach⁸ (Moore's Approach) was used in our series. From a point 10 centimeters distal to posterior superior iliac spine and extended distally and laterally parallel to the fibers of gluteus maximus to the posterior margin of the greater trochanter and then directed about 10 cm parallel to the femoral shaft. Deep fascia was exposed and divided in the line with the skin incision as also was the fascia over gluteus maximus, which was then split in the direction of its fibers using blunt dissection. By retracting the proximal fibers of the muscle proximally, the greater trochanter was exposed. Distal fibers were retracted distally and partly divided at their insertion into the linea-aspera in line with the distal part of the incision. The sciatic nerve was usually not exposed. It is protected with finger in the medial part of the wound and was gently retracted out of the way. The gemelli, obturatorinternus and the piriform is tendon were divided at their insertions after tagging them for easier identification and reattachment. The posterior part of the capsule thus exposed was incised from distal to proximal along the line of neck of femur and at right angle to it, thus making a T shaped opening in the capsule. The fractured head and neck of the femur was levered out of the acetabulum and size measured using femoral head gauge. The size was confirmed using trial prosthesis by its suction fit in the acetabulum. The acetabulum was prepared by excising remnants of

ligament umnteres and soft tissue. The femoral shaft was rasped using a broach (rasp) and prepared for the insertion of the prosthesis. Femoral neck if long was nibbled keeping 2 to 2.5 cms of calcar above the lesser trochanter. The prosthesis was then inserted into the femoral shaft in about 5^0 - 10^0 of anteversion and impacted into the femur. The reduction of the prosthesis was then done using gentle traction of the thigh. In case of cemented procedure, the stem was cemented in place using standard cementing techniques - lavage, cleaning, drying and plugging of the canal. Absolute haemostasis was obtained. After suturing the capsule, the external rotators were sutured. The wound was closed in layers over a suction drain, which was removed at the first change of dressing after 48 hours. All the patients were given short term thromboprophylaxis in the form of

Injection Enoxaparin 40milligramsubcutaneously 12 hours after surgery and once a day for seven days⁹. All the patients were started with quadriceps strengthening exercises from day two and high sitting from day three. The patients treated with cemented bipolar prosthesis were allowed for full weight bearing from fifth post-operative day. This early weight bearing was allowed because of the stability of the implant achieved by the cement. The patients treated with Austin Moore's prosthesis were allowed for non-weight bearing ambulation with the help of walker for first three weeks, partial weight bearing till six weeks and followed by full weight bearing. This delayed weight bearing allows bone growth on the surface and holes of prosthesis which helps in stability¹⁰.

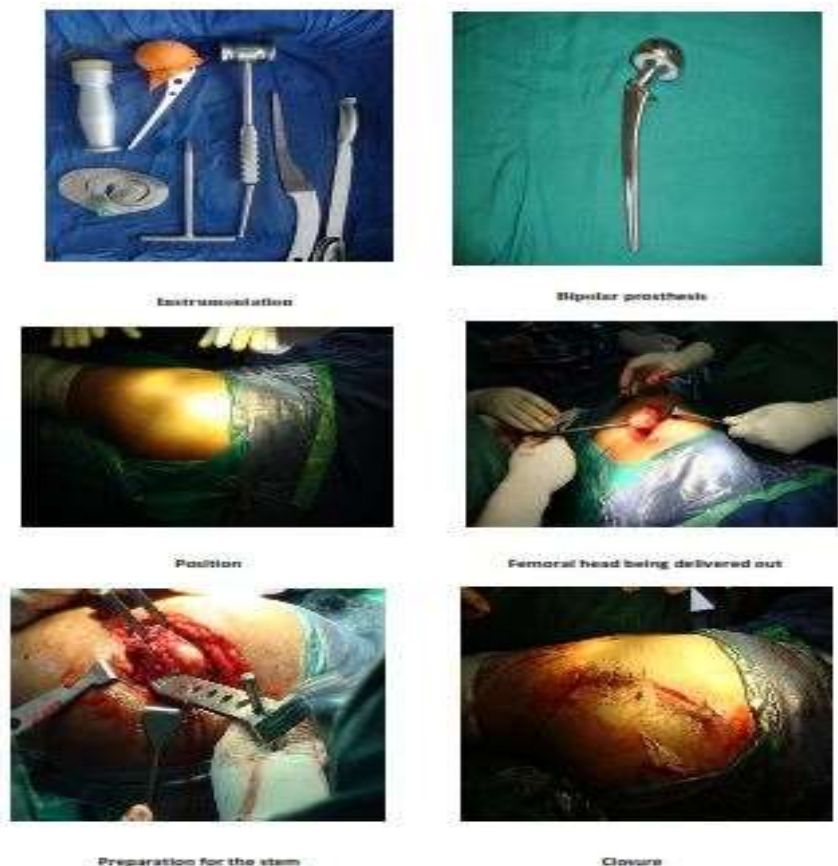

Fig. 1: Intraoperative Pictures

Observations and Results

After 6 month follow up of patients who had undergone hemiarthroplasty using AMP or bipolar prosthesis, following observations were made.

Age and sex distribution: The study involved patients above 60 years of age. The eldest patient to undergo hemiarthroplasty was 98 years. Mean age of male patient was 68.86 years and mean age of female patient was 69.5 years. Our study showed female preponderance with females being 28 in number and males being 22 in number.

Side of fracture: Left sided fractures were more compared to the right sided fractures. There were 29 patients with left sided fracture and 21 patients with right sided fracture.

Type of fracture: On radiological examination, there were 34 patients(68%) with sub capital fracture and 16 patients(32%) had transcervical fractures.

Mode of injury: Seventy eight percent (39) of patients suffered fracture following household fall. 8 percent(4) of patients had a fall from moderate height while fourteen percent (7) of patients had fracture following road traffic accident.

Associated injuries: One patient had anterior wedge compression fracture of L-3 vertebrae following a fall from moderate height. Twelve percent (6) patients had superficial abrasions, 86 percent (43) of patients had no associated injuries.

Associated diseases: A total of 46% of patients were suffering from various medical conditions like hypertension, diabetes mellitus, chronic obstructive pulmonary disease and ischemic heart disease. These patients were given necessary treatment before surgery and taken up for the procedure after they were medically fit.

Total stay in hospital: Duration of stay in hospital ranged from 13 to 35 days. Ninety-eight % of patients had a stay of less than 30 days in hospital. 31-39 days in remaining 2 percent(1).

Complications: Various complications were noted during follow up. One patient (2%) had periprosthetic fracture along with posterior dislocation of prosthesis in postoperative period, who was re-operated and fracture stabilized with stainless steel wire and prosthesis reduced into acetabulum. The patient came after 3 months with re-dislocation along with fracture. He was advised girdle-stone procedure for which he refused for the intervention. This patient died during the 4th month of follow-up.

Superficial infection was noted in one patient during the first week of operation who was treated with antibiotics and dressings. There were no cases of deep infection.

Dislocation of the Prosthesis: In our series there was one case of posterior dislocation of the prosthesis which was found on the 8th post-operative day. The dislocation was reduced under general anaesthesia.

Prosthesis loosening and protrusion acetabuli: In our study, among the patients treated with Austin Moore's prosthesis 3 showed radiographical changes at six months of follow up. Two patient's X-ray showed radiolucent zone of more than 2mm at the stem of prosthesis and another patient's X-ray showed sclerosis at tip of prosthesis which was signs of aseptic loosening. The reason is probable technical errors during the procedure. These patients were managed by revision surgery using cemented bipolar prosthesis. No cases of protrusion seen in our study.

Pain: We observed that 37.78% in our series had no pain and 32% of patient had slight pain. 22.22% had moderate and in remaining 8% patients with marked pain.

Limp: 77.77% had none to slight limp. Moderate limp was seen in 20% of the subjects whereas only 2.22% of the patients had severe limp.

Use of support: 20 patients did not use any kind of support for walking. 12 patients used cane only for long walks and 13 patients used cane most of the time.

Walking distance: The details of score and number of patients graded according to distance walked are given in the Table 1.

Table 1: Distribution of the sample by Criteria of walking distance

Criteria	Score	Frequency	Percent
Unlimited	11	23	51.11
6 blocks	8	16	35.55
2-3 blocks	5	0	0
Indoors only	2	6	13.33
Bed and Chair	0	0	0
Total		45	100.0

Ability to Put on Shoes and Socks: In case of patients from rural areas who were not using shoes were asked to do similar activities like cleaning their own foot or cut nail (Table 2).

Table 2: Distribution of the sample by Criteria of putting on shoes

Criteria	Score	Frequency	Percent
with ease	4	31	68.9
with difficulty	2	11	24.4
Unable	0	3	6.7
Total		45	100.0

Stair climbing: Majority (75.55 %) of patients were able to climb stairs without any difficulty (Table 3).

Table 3: Distribution of the sample by criteria of stair climbing

Criteria	Score	Frequency	Percent
Without using railing	4	16	35.55
Using a railing	2	18	40.0
Any manner	1	8	17.77
Unable	0	3	6.67
Total		45	100.0

Sitting: Majority of patients (75.55%) could sit on ordinary chair without any discomfort. 20% of patients could sit on high chair comfortably.

Enter public transport: 84.45% of patients in our study were able to use public transportation.

Deformity at the hip: The deformities seen in our series at end of six months (Table 4).

Table 4: Distribution of the sample by deformity classification

Deformity	Frequency	Percent
Nil	35	77.77
Fixed flexion deformity 5°	3	6.66
Internal rotation 5°	2	4.44
External rotation 5°	5	11.1
Total	45	100.0

Leg-length discrepancy: Leg length discrepancy was ranging from 0.5–1.5 cms which was compensated by pelvic tilt.

Range of movements: Majority (88.89%) of patients in our study had good range of movements following hemiarthroplasty.

Total functional result: The functional outcome after hemiarthroplasty for intracapsular fracture neck of femur was graded as excellent, good, fair and poor after adding the scores given for each criteria of assessment of hip. In our study, Harris hip score ranged from 35 to 94.6 at end of six months. 22% had hip score of 91-100 (excellent), 40% of had scores of 81-90 (good), and 22% had satisfactory/fair results whereas only 15.55% of hemiarthroplasties fell in poor category with scores below 70 (Table 5). Thus 84.44% of the patients were classified as having a satisfactory to excellent results (Fig. 2 and 3).

Table 5: Distribution of cases by functional results & prosthesis at the end of 6 months

Prosthesis		Results				Total
		Excellent	Good	Fair	Poor	
		Total Harris		Hip Score		
		91-100	81-90	71-80	Below 70	
AMP	Frequency	2	6	9	3	20
	%	4.44%	13.33%	20%	6.66%	44.44%
Bipolar	Frequency	8	12	1	4	25
	%	17.78%	26.67%	2.22%	8.88%	55.55%
Total	Frequency	10	18	10	7	45
	%	22.22%	40%	22.22%	15.56%	100%

Radiographic result: In our study, 3 patients had positive radiographic findings at end of six months of follow up. Among them, two patients x-rays showed radiolucent zone of more than 2mm at the stem of prosthesis. One patient's x-ray showed sclerosis at tip of prosthesis. In our study protrusion acetabuli was not seen.

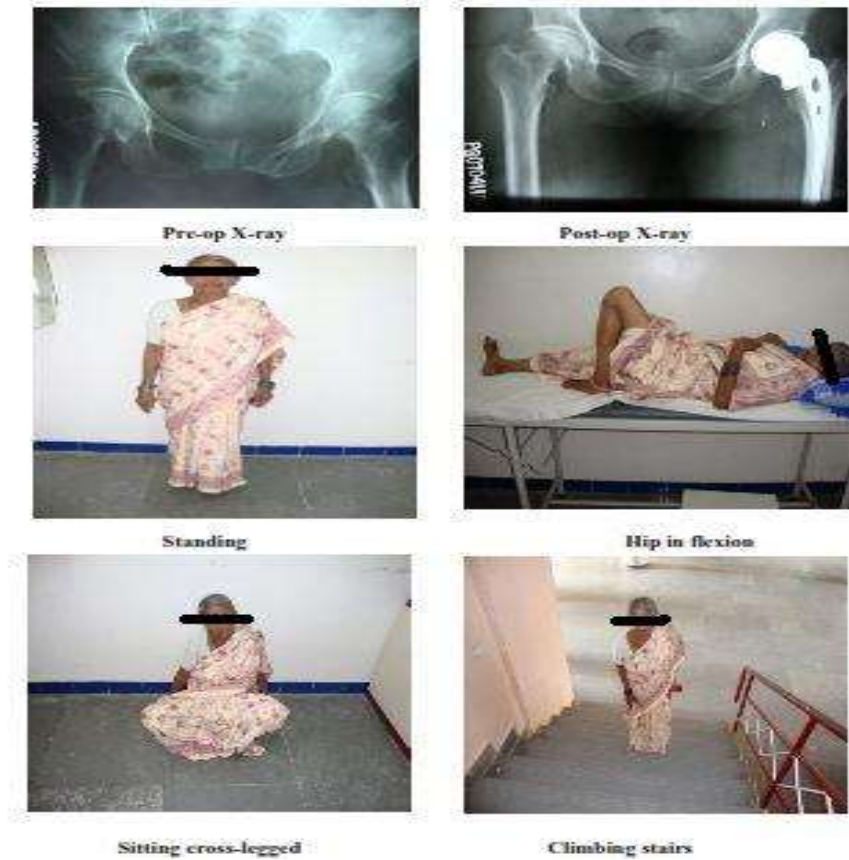


Fig. 2: Radiological and functional assessment using Austin Moore's prosthesis

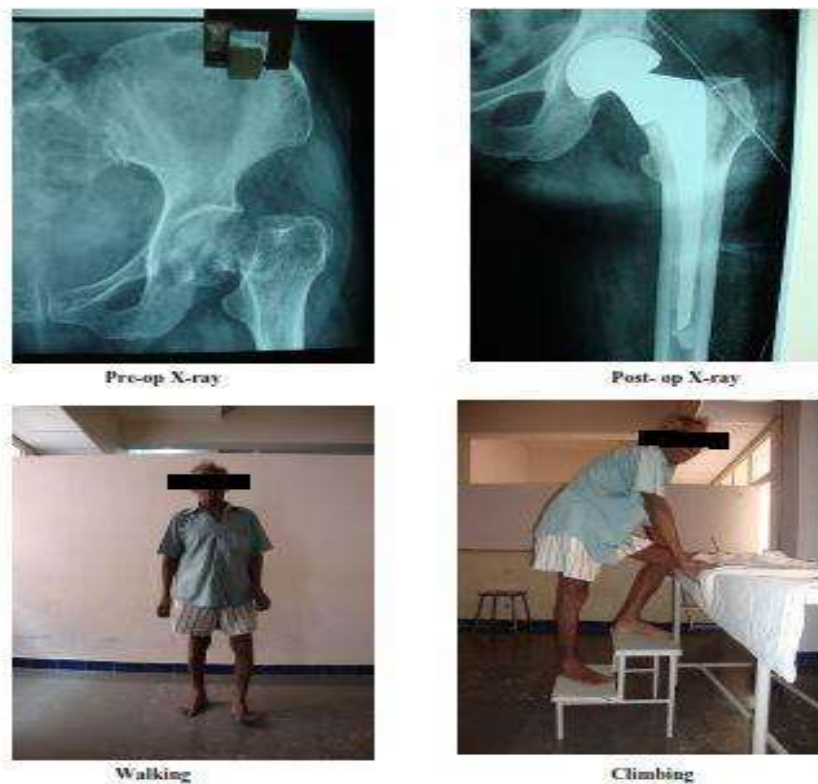


Fig. 3: Radiological and functional assessment for Bipolar prosthesis

Discussion

Fracture neck of femur is still an unsolved enigma for an orthopedic surgeon. Results have been variable with various modalities of treatment which includes osteosynthesis, hemireplacement and total hip replacement. Since osteosynthesis may require two procedures on its failure and elderly patients may not be able to tolerate the effect of repeat surgery, prosthetic replacement has become a popular choice among surgeons. Total hip arthroplasty is not preferred as primary procedure in a developing country like ours as it is technically more demanding and expensive. Hence hemireplacement procedure continues to be a favored option. With this idea we undertook the present study to evaluate the immediate results of hemiarthroplasty in fracture neck of femur using either Austin Moore's prosthesis or bipolar prosthesis keeping in view the living condition of an average Indian.

Age distribution: The average age of our patients was 68.86 years in case of males and 69.5 years in case of females. Majority of the patients were between 60-70 years. Similar age distribution has been reported by other authors. Saxena and Saraf¹¹ (1978) had age distribution 45-90 years (Mean 66 years); Mukherjee and Puri¹² (1986) 65 years, Arwade¹³ (1987) 54-86 years with incidence between 70-80 years (Average 72 years). Bavadekar and Manelkar¹⁴ (1987) had mean age group of 75 years in fresh fractures where as in old cases it was 62 years.

Sex Incidence: In our study the intracapsular fracture of femoral neck were found to be more common in females. The elderly females are more prone to fracture neck of femur due to osteoporosis (Choudhari and Mohite¹⁵ 1987). Female preponderance has been reported in several series like Moore¹⁶ (1957): 62.5%. In our series 56% of the patients were females.

Side of Fracture: The left sided hip was fractured in 29 patients (58%) of our series. Boyd and Salvatore¹⁷ (1964) reported 55% fractures on left side. D'Acry and Devas¹⁸ (1976) similarly found 55.4% fracture in left hip of their patients.

Type of Fracture: According to anatomical classification by Sir Astley Cooper in 1823, fracture neck of femur was classified into extracapsular and intracapsular fractures. Intracapsular is again divided into subcapital (fracture line is immediately beneath the head), transcervical (fracture line passing across the neck between the femoral head and greater trochanter). Depending on the impaction at the fracture site, Waldenstrom has classified as valgus impacted, varus impacted and non-impacted fractures. Depending upon degree of displacement, Garden classified fractures as type-I incomplete, type-II complete undisplaced, type-III complete partially displaced and type-IV complete fully displaced. In our study, depending on the anteroposterior radiographic view, they were grouped into subcapital and transcervical type. In our series, 68% patients had

subcapital fracture and 32% had transcervical type of fractures. Klenerman and Marcuson¹⁹ (1970) defined sub capital fracture as the one that occurs immediately beneath the articular surface of the femoral head along the old epiphyseal plate and a transcervical fracture was referred to the fracture passing across the femoral neck between the femoral head and greater trochanter. Garden²⁰ (1974) suggested that this differentiation cannot be made distinctly in radiographs. Klenerman and Marcuson could not find transcervical fractures in their series and all were sub capital type on operation. Our operative findings are similar to that of Klenerman and Marcuson. 38 patients in our study had sub capital fracture. Our operative findings also revealed comminution of the posterior surface of the neck in 38 patients (63.3%). These findings are in accordance with that of Banks²¹ (1962) who reported it in about half of their patients. All the fractures in our series belonged to displaced fractures of Garden Type III and IV. Depending on the anteroposterior radiographs, we could group 32 patients (64%) into type III and 18 patients (36%) into Garden type IV. G.S. Kulkarni²² (1987) had grouped type III and type IV into one group of 'displaced fractures' and reported it in 82.5% of his patients. Mukherjee and Puri¹² (1986) had 85% patients of Garden type III and IV fractures.

The type (subcapital or transcervical) or the displacement (Gardens III and IV) is not taken as criteria to choose the procedure for the management of fracture neck of the femur. The age of the patient [Saraf and Saxena¹¹ (1978), Mukherjee and Puri¹² (1986)] and time since fracture [G.S. Kulkarni²² (1987)] are taken into consideration while selecting hemiarthroplasty for the management of fracture neck of femur. Bavadekar and Manelkar¹⁴ (1987), emphasized not to choose hemiarthroplasty in Garden type I and II fractures even in old individuals. We have followed the same criteria while selecting the patients for hemiarthroplasty.

Nature of Injury: Seventy four percent of our patients had trivial trauma and rest of them were due to severe trauma like fall from height or vehicular accidents. This is in accordance with majority of the series reported – Ingalhalikar²³ (1987), Seth²⁴ (1987). Stevens et al.²⁵ (1962) and several other authorities who believe that the intracapsular fracture are stress fractures due to pathological bone secondary to osteoporosis or osteomalacia.

Associated Injuries: There were no significant associated injuries in patients from our study. One patient had anterior wedge compression fracture of less than twenty-five percent of L-3 vertebrae. This patient was given bed rest for 6 weeks to allow for the fracture to heal and was mobilized once fracture healing was noted radiologically. Six other patients had minor abrasions. No other major injuries were noted.

Associated Medical Problems: The common problem in our series was hypertension, diabetes mellitus, chronic obstructive pulmonary disease and ischemic heart disease which accounted for forty six percent of our patients. Hinchey and Day²⁶ (1964) reported similar problems in 84.6% of their patients. Ischemic heart disease is common in western series, which are not found so common in our series. We had only one patient with ischemic heart disease with hypertension. Hypertension, diabetes mellitus were commonly detected after the patient got admitted with fracture neck of femur.

Type of Prosthesis: Twenty eight patients received bipolar prosthesis while twenty two patients received Austin Moore's prosthesis. All twenty eight of bipolar were cemented prosthesis.

Hospital Stay: In our series hospital stay ranged from 13 days to 39 days with a mean average of 19.86 days. Stinchfield and Cooperman²⁷(1957) reported 31.5 days hospital stay, A.A. Savastano et al²⁸. (1958): 38 days, Johnson and Crothers²⁹ (1975): 30 days. All the cases were operated electively. Forty six percent of our patients who had various medical problems were treated for their respective condition and then taken up for surgery. One patient who had superficial wound infection in the post-operative period had to longer stay in the hospital.

Complications

Mortality: We had no immediate post-operative deaths in our series. One patient with periprosthetic fracture and posterior dislocation of prosthesis died during the fourth month of follow up. The exact cause of death was not known. Wai-Hee Lo et al³⁰ in 1994 noted 4% of mortality in their series due to bed sore with sepsis.

In the Indian series available, death rate is not very high. The mortality rate in our series is 2% which is comparable to that of others. Low mortality is probably due to proper selection of cases. When majority of the deaths in western series were due to cardiac problems, we had only one case with established ischemic heart disease that underwent hemiarthroplasty. Low death rate may be also due to proper management of the associated medical problems preoperatively, use of antibiotics routinely and early mobilization.

Sepsis: In our series, only 1 patient (2%) had superficial wound infection. The patient was non-diabetic and non-hypertensive. She developed signs of infection in the first week of operation which led to the prolongation of hospital stay. She was treated with proper antibiotics and dressings. There were no cases of deep infection in our series.

The organism isolated in the above case was *Staphylococcus aureus*. Gingras³¹ et al (1980) stated that infection was the devastating complication of hemiarthroplasty. Superficial infection could be successfully treated with antibiotics, local measures and drainage. Deep infections most of the time need removal

of the prosthesis. Early deep infections may present as mild low grade pain in the thigh or groin to an acute, potentially fatal clinical course with septic shock. Salvatti et al (1974)³² and Whittaker (1974)³³ have reported extremely high mortality following infection of the prosthesis.

Dislocation of the Prosthesis: In our series there was one case of posterior dislocation of the prosthesis which was found on the 8th post-operative day. The dislocation was reduced under general anaesthesia. Salvatti et al³²(1974) believed that excessive postoperative flexion or rotation with hip adducted is the main cause for dislocation of the prosthesis and they also observed that dislocation was commonly caused while shifting the patients from the operation theatre to the ward. In 1998 John E. Kenzora et al³⁴ noted that all six dislocations in their series followed after posterior approach. Dislocation is a well-known complication of posterior approach. However in our series we noted only one dislocation(2%) which was not statistically significant.

Periprosthetic Fractures: Only one patient in our study had periprosthetic fracture. Fracture was noted on first post-operative day on X-ray(type A-Vancouver classification). Since prosthesis appeared unstable, patient was taken up for surgery the next day where fracture was stabilized using stainless steel wire. Later after 3 months, the patient came back with posterior dislocation of the prosthesis along with fracture. He was advised girdle-stone procedure for which here fused for the intervention. This patient died during the 4th month of follow-up. Hinchey and Day²⁶ (1964) emphasize that all fractures occur when the surgeon attempts to reduce the prosthesis.

Prosthesis loosening and protrusion acetabuli: By maintaining the adequate neck length (more than 12 millimeters- measured from the superior margin of the lesser trochanter to the resection margin at the calcar femorale) and adequate calcar seating (medial prosthetic collar to calcar should be zero millimeters) in our study reduced the incidence of the prosthetic loosening. By maintaining the prosthetic head size of less than two millimeters difference with the contralateral normal femoral head using circular overlays, the erosion of the articular cartilage and protrusion acetabula were prevented^{1,35,36}. In our study, among the patients treated with Austin Moore's prosthesis 3 showed radiographical changes at six months of follow up. Two patient's X-ray showed radiolucent zone of more than 2mm at the stem of prosthesis and another patient's X-ray showed sclerosis at tip of prosthesis which was signs of aseptic loosening. The reason is probable technical errors during the procedure. These patients were managed by revision surgery using cemented bipolar prosthesis.

Painful prosthesis: We observed that 37.78% in our series had no pain and 32% of patient had slight pain, 22.22% had moderate and remaining 8% patients had marked pain. Pain following hemiarthroplasty is a major concern. Hinchey and Day²⁶ (1964) in their series of 294 patients found pain in 22 patients in the early post-operative period following hemiarthroplasty. They could not find any definitive cause in them. They suspected poor muscle control as the probable cause of pain. The pain was mild to moderate and required treatment. Lanceford³⁷ (1965) felt that the pain following hemiarthroplasty should not be the cause for condemning the procedure. He listed following causes for pain: Infection, improper prosthetic seating, metallic corrosion and tissue reaction, improper sized femoral head, contractures, periarticular ossification, toggle or acetabular wandering and redundant ligamentum teres. Pain was the main criteria for assessing the functional results in majority of the series (Saraf and Saxena¹¹ 1978, Mukherjee and Puri¹² 1986, D'Acry and Devas 1976¹⁸, Hinchey and Day²⁶ 1964, Lanceford 37, 1965). D'Acry and Devas¹⁸ (1976) cautioned that the presence of pain with or without loosening or migration may be associated with sepsis. Hinchey and Day (1964)²⁶ reported the use of radiotherapy and intraarticular steroids. Radiotherapy relieved pain in 15 patients and failed to do so in 7. Intraarticular steroids gave relief in one patient. Revision arthroplasty was also reported in one patient. Active exercises of gluteal and quadriceps muscles relieved pain in 7 patients after a period of 8 to 20 months. Coventry (1964)³⁸ recommended physiotherapy, local intraarticular steroids, revision, replacement, girdle stones arthroplasty and Milch Bachelor arthroplasty for painful prosthesis. Now total hip arthroplasty is the procedure of choice. In our patients with marked pain analgesics, hot water fomentation and physiotherapy was advised.

Limping and use of cane: 77.77% had none to slight limp. Moderate limp was seen in 20 % of the subjects whereas only 2.22 % of the subjects had severe limp. Limping is a common consequence of hemiarthroplasty in adults which is due the alteration in the abductor mechanism [Saraf and Saxena, (1978)¹¹; Hinchey and Day(1964)²⁶]. All the patients were asked to use a cane on the sound side regularly. This decreases load on the prosthetic head. Once the patient got enough endurance they were advised to discard the cane. 20 patients did not use any kind of support for walking. 12 patients used cane only for long walks and 13 patients used cane most of the time. Stinchfield and Cooperman (1957)²⁷ reported 14% of their patients using cane regularly. 16% of Barr and Donovan³⁹(1964) series were using the caneal ways, 34% were using occasionally and 20% discarded it. Saraf and Saxena¹¹ (1978) reported 52.7% patients using cane regularly, 23.1% occasionally and 21.8% were not using it. Our patients are comparable to this study.

Results

Total functional results(Table 6): Various criteria were used to assess the functional results following hemiarthroplasty. The assessment was based on the extent to which the patients attained the pre –fracture state. Indian population need more range of motions at hip when compared to western population as there is need for squatting or sitting cross legged for various purposes. The final results at 6 months after hemiarthroplasty in our series were analyzed by modified Harris hip scoring system⁴⁰. The results were compared with the available western and Indian series where hemiarthroplasty was done for the treatment of fracture neck of femur in elderly patients.

Table 6: Percentage of functional results following hemiarthroplasty for Fracture neck of the femur

Investigator	No. of Patients	Excellent	Good	Fair	Poor
Salvatti et al (1964)	251	31	26	25	8
Saxena & Saraf (1978)	82	46.1	44.8	6.5	2.6
Mukherjee & Puri (1986)	55	29	49	18	4
Our Series	45	22.22	40	22.22	15.56

The functional difference between excellent and good results are minimal and therefore they can be grouped together as good results which accounts for 62.22% in our study which are comparable to the above series: Saxena and Saraf¹¹: 90.9%, Mukherjee¹²: 78%, Salvattiet al³²57%.

Radiographic result: In our study, among the patients treated with Austin Moore's prosthesis 3 showed radiographical changes at six months of follow up. Two patient's X-ray showed radiolucent zone of more than 2mm at the stem of prosthesis and another patient's X-ray showed sclerosis at tip of prosthesis which was signs of aseptic loosening. The reason is probable technical errors during the procedure. These patients were managed by revision surgery using cemented bipolar prosthesis. Gingras (1980)³¹ and Whittaker³³ (1974) reported and compared prosthetic loosening and proximal migration of the prosthesis with pain. Distal migration is best detected by comparing recent and earlier radiographs. Calcarresorption (Gingras)³¹ or change in distance, from the collar of the prosthesis to lesser trochanter(Whittaker)³³ are suggestive of distal migration. Incidence of prosthetic loosening in hemiarthroplasty is 2.3% out of 44 patients according to Amite pankaj³⁶ et al which is comparable to our study.

Conclusion

Fifty cases of fracture neck of femur in elderly patients above the age of 60 years treated by hemiarthroplasty using either Austin Moore's, or bipolar prosthesis in the Department of Orthopedics at our institute from November 2008 to November 2013 were studied. The cases were followed up for 6 months and the short term functional results were analyzed by using modified Harris hip scoring system⁴⁰. At the end of 6 months after surgery one patient expired and four cases were lost for follow up. Thus the functional results were analyzed in the remaining 45 cases. The patients were in the age group of 60 to 98 years with mean average age of 69.82 years. Females were predominant. Majority of the fractures were sub capital radiologically. The results were excellent in 22.2%, good in 40% and satisfactory in 22.22%. Poor results were seen in 15.56% of cases. The poor results (15.56%) were due to moderate to marked pain in the hip or thigh after hemiarthroplasty. The success of hemiarthroplasty depends on preoperative planning and proper attention to surgical details to achieve the optimum biomechanical stability. Since the morbidity and mortality are minimal, weight bearing is early, complications are less disabling and early functional results are good to excellent, we conclude that hemiarthroplasty for fracture neck of femur is a good option in elderly patients.

References

1. P Weinrauch. Intra-operative error during Austin Moore Hemiarthroplasty. *Journal of Orthopaedic Surgery* 2006;14(3):249-52.
2. Davison JN, Calder SJ, Anderson GH, Ward G, Jagger C, Harper WM, et al. Treatment for displaced intracapsular fracture of the proximal femur: A prospective, randomized trial in patients aged 65 to 79 years. *J Bone Joint Surgery Br*. 2001;83:206-12.
3. Soreide O, Molster A, Raugstad TS. Internal fixation versus primary prosthetic replacement in acute femoral neck fractures: A prospective, randomized clinical study. *British J Surgery*. 1979;66:56-60.
4. Sikorski JM, Barrington R. Internal fixation versus hemiarthroplasty for the displaced subcapital fracture of the femur: A prospective randomized study. *J Bone Joint Surgery Br*. 1981;63:357-61.
5. Weinrauch P. Intraoperative Error During Implantation of the Austin Moore Hemiarthroplasty. *Journal of Orthopaedic Surgery*. 2006;14(3):249-252.
6. Shekhar A, Murgod G. Two years outcome of cemented Austin Moore Hemiarthroplasty for Fracture neck Femur. *Journal of Dental and Medical Sciences*. 2013;11(6):10-15.
7. Nepomuceno C, Baker G, Shaddeau S, Urso J, Bautista E. Rehabilitation of geriatric patients with Austin-Moore prostheses. *Ala Med*. 1986 Dec;56(6):28-30
8. Terry Canale.S.MD. Campbell's operative orthopaedics.10th ed. Mosby:2003:315-316.
9. Hull RD, Pineo GF. Prophylaxis of deep venous thrombosis and pulmonary embolism. Current recommendations. *Med Clin North Am*. 1998 May;82(3):477-93.
10. Sharif KM, Parker MJ. Austin Moore hemiarthroplasty: technical aspects and their effects on outcome, in patients with fractures of the neck of femur. *Injury* 2002;33:419-22.
11. Saxena P.S. and Saraf J.K. Moore Prosthesis in fracture neck of femur. *Indian Journal of Orthopaedics*1978; Vol 12:138-145.
12. Mukherjee D.L.(Col), Maj. Gen. H.C. Puri. Early hemiarthroplasty for fresh fractures of the neck of the femur in geriatric patients. *Indian Journal of Surgery* 1986;Vol.48:77-80.
13. Arwade D.J. A review of internal fixation and prosthetic replacement for fresh fractures of the femoral neck.*Clini Orthop India*1987;Vol 1:77-82.
14. Bavadekar A.V., Manelkar K.R. Hemiarthroplasty of the hip in the treatment of intracapsular fracture neck of the femur state of the art and an appraisal. *Clinical Orthopaedics of India*1987;Vol 1:43-52.
15. Choudhary and Mohite. Pathology of fracture neck of femur. *Clinical Orthopaedics India*1987;Vol 1:45-48
16. Austin T. Moore: The self-locking metallic hip prosthesis. *JBJS* 1957;39A:811-27.
17. Boyd H.B. and Salvatore J.E. Acute fractures of the femoral neck: Internal fixation or Prosthesis? *JBJS* 1964;46A:1066-1068.
18. D'Acry J., Devas M. Treatment of fractures of the femoral neck by replacement with the Thompson prosthesis. *JBJS*1976;58B:279-286.
19. Klenerman L. and Marcuson R.W. Intracapsular fractures of the neck of the femur. *JBJS* 1970;52B:514-517.
20. Garden R.S. The structure and function of the proximal end of the femur, *JBJS*1961;43B:576-589
21. Banks H.H. Factors influencing the results in fractures of the femoral neck *JBJS*1962;44A:931-964.
22. Kulkarni G.S. Pathology of fracture neck of the femur. *Clinical Orthopaedics of India*1987;Vol 1:92-96.
23. Ingalthalika V.T., Shekar Kumta. Fracture neck femur anatomical and biomechanical aspects. *Clin. Orthop. India* 1987.
24. Seth M.K. (Col). Stress fractures of the neck of femur. *Clinical Orthopaedics India*1987;Vol 1:105-109.
25. Stevens J., Freeman P.A., Nordin B.E.C. and Barnett E. The incidence of osteoporosis in patients with femoral neck fractures *JBJS* 1962;44B:520-527.
26. Hinchey and Day. Primary prosthetic replacement in fresh femoral neck Fractures. *JBJS*1960;42B:633-640.
27. Stinchfield F.E., Cooperman B. and Shea C.E. Replacement of the femoral head by Judet or Austin Moore Prosthesis. *JBJS* 1957;39A:1043-1058.
28. Savastano A.A. Treatment of fractures of the neck femur with intramedullary stem prosthesis. *Archives of surgery*1957;75:156-159.
29. Johanson J.T.H and Crothers O. Nailing versus prosthesis of femoral neck fractures. *JBJS* 1972;57A:686-692.
30. Wai-Hee Lo. Bateman bipolar hemiarthroplasty for displaced intracapsular femoral neck fractures. *Clin. Orthop*.1994;302:75-82.
31. Gingras MB. Prosthetic replacement in femoral neck fractures. *Clinorthop* 1980;152:147-157.
32. Salvatti E.A., Artz T., Algeitti P., Asins S.E. Endoprosthesis in the treatment of femoral neck fractures. *Orthop. clinic. North America*1974;5:757-777.
33. Whittaker R.P., Sotos L.N., and Raston E.L. Fractures of the femur about femoral endoprosthesis. *J. Trauma*1974;14:675-694
34. John E. Kenzora. Outcome after hemiarthroplasty for fracture neck of femur in elderly. *Clini Orthop*.1998;348:51-58.
35. Yau WP, Chiu KY. Critical radiological analysis after Austin Moore hemiarthroplasty. *Injury* 2004;35:1020-4.

36. Amite Pankaj, Rajesh Malhotra, and Surya Bhan. Conversion of failed hemiarthroplasty to total hip arthroplasty: A short to mid-term follow-up study. *Indian J Orthop.* 2008 Jul-Sep;42(3):294–300.
37. Lance Ford E.M. Use of Moore self-locking Vitallium prosthesis in acute fractures of the femoral neck. *JBJS*1965; 47A:832-841.
38. Coventry M.B. Salvage of the painful hip prosthesis *JBJS*1964;46A:200-217.
39. Barr J.S., Donovan J.F and Florence D.W. Arthroplasty of the hip. *JBJS*1964;46A:249-266.
40. Harris W.H. Traumatic arthritis of the hip after dislocation and acetabular fractures treated by mould arthroplasty. *JBJS*1969;51A:737- 55.