

## Cervical PAP Smear Examination in Women Living with HIV-A study of 60 cases

Vijayashree Shivappa Neeravari<sup>1\*</sup>, Anirudha Vasantacharya Kushtagi<sup>2</sup>, Doddappa Mallappa Bannigidad<sup>3</sup><sup>1</sup>Assistant Professor, <sup>2</sup>Associate Professor, Koppal Institute of Medical Sciences, Koppal

\*Corresponding Author:

Email: drvijayashreen@gmail.com

**Abstract**

Cervical cancer in women living with Human Immunodeficiency Virus (HIV) is a major health problem accounting for 26.1-43.8% of all cancers in Indian Women. Women infected with HIV have a higher risk of developing cervical intraepithelial neoplasms. Dysplasia has been reported in 15 to 64.6% of HIV infected women & these rates are 10-12 times higher than those observed among HIV negative women 13%.

**Materials and Methods:** The aim of this study is to estimate the frequency of abnormal Papanicolau (Pap) smears and mainly to detect precancerous & cancerous lesions as well as inflammatory lesions in HIV-infected women.

**Results:** Total 68 samples were collected. Pap smear abnormalities included LSIL(10.2%), HSIL(4.4%), ASCUS(8.8%), ASC-H(2.9%), Carcinoma(1.4%), Specific Infections 33.8% (Bacterial Vaginosis-19.1%, Trichomonas Vaginalis-5.8%, Candidiasis-5.8%, Herpes Simplex-2.9% Cytolytic smear-1.4%), Non-specific Inflammatory smear (36.7%).

**Conclusion:** In view of high percentage of inflammatory Pap smears, infections and cervical intraepithelial lesions among HIV positives women. Among the various intraepithelial lesions LSIL was the commonest, stressing the need for routine pap smear testing annually in women living with HIV.

**Keywords:** HIV, Pap smear, patient living with HIV, Cervical intraepithelial neoplasia

Access this article online	
Quick Response Code:	Website: www.innovativepublication.com
	DOI: 10.5958/2394-6792.2016.00051.X

Pap smear was performed. Smears were reported by 2 pathologists separately.

**Results**

Total 68 samples were collected. Pap smear abnormalities included LSIL(10.2%), HSIL(4.4%), ASCUS(8.8%), ASC-H(2.9%), Carcinoma(1.4%), Specific Infections 33.8%(Bacterial Vaginosis-19.1%, Trichomonas Vaginalis-5.8%, Candidiasis-5.8%, Herpes Simplex-2.9% Cytolytic smear-1.4%), Non-specific Inflammatory smear (36.7%). (Table 1)

**Introduction**

Cervical cancer in women living with Human Immunodeficiency Virus (HIV) is a major health problem accounting for 26.1-43.8% of all cancers in Indian Women<sup>1</sup>. In immune competent subjects, HPV infections normally clear in 6-24 months in 70% of females. However, women infected with HIV have a higher prevalence of HPV infection and are more likely to develop persistent HPV infection with multiple HPV types & thus are at greater risk of developing cervical intraepithelial neoplasms. Dysplasia has been reported in 15 to 64.6%<sup>2</sup> of HIV infected women & these rates are 10-12 times higher than those observed among HIV negative women 13%.<sup>2,3,4</sup>.

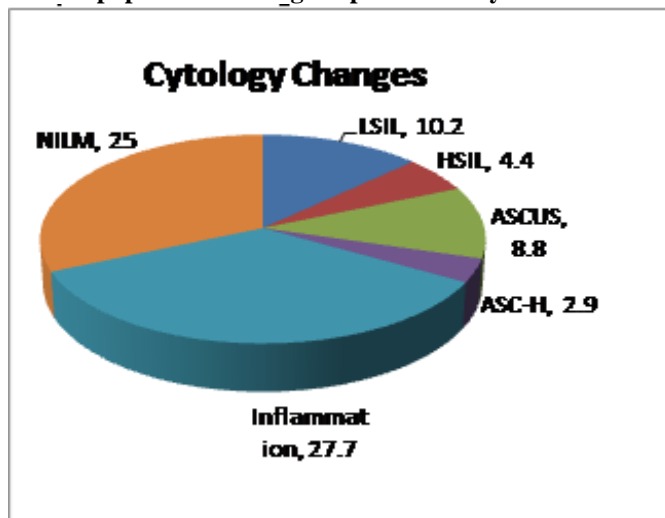
**Materials & Methods**

The aim of this study is to estimate the frequency of abnormal Papanicolau (Pap) smears and mainly to detect precancerous & cancerous lesions as well as inflammatory lesions in HIV-infected women. All HIV infected women (20-50 years of age), attending routine health checkup at Govt. Hospital, Koppal between May-July. 2015 were included, consent was taken and

**Table 1: Cervical pap smear findings in present study in women living with HIV**

Sl No	Cervical Lesions	Number
1	LSIL	07(10.2)
2	HSIL	03(4.4)
3	ASCUS	06(8.8)
4	ASC-H	02(2.9)
5	Bacterial Vaginosis	13(19.1)
6	Trichomonas Vaginalis	04(5.8)
7	Candidiasis	04(5.8)
8	Herpes Simplex	02(2.9)
9	Cytolytic smear	01(1.4)
9	Carcinoma	01(1.4)
10	Non specific infections	25(36.7)
	Total	68

**Graph 1: Cervical pap smear findings in present study in women living with HIV**



**Discussion**

Human papillomavirus (HPV) infection, is a sexually transmitted disease, and has been etiologically linked to both pre-invasive lesions and invasive cervical carcinoma.<sup>5</sup> Previous studies have shown that HIV-infected women present higher prevalence of CIN and cervical cancer when compared to uninfected women.<sup>6</sup>

In the present study incidence of epithelial cell abnormalities was 27.7 % that was high compared to other studies like 8.34% in B M Jha et al<sup>7</sup>, 5.4% in Sandrie et al<sup>8</sup>, 4.8% in N.R. Agrawal et al<sup>9</sup>, 17.8% in M Carlucci et al<sup>16</sup>, 16.45 % in Amphan et al<sup>10</sup>, 20.29 % in

Leibenson et al<sup>11</sup>, 50.2% in Jennifer et al<sup>12</sup>, 8% in Pooja et al<sup>13</sup>. But the incidence was much lower compared to 100% in F Kabir et al<sup>2</sup>, 66.5 % in Jennifer et al<sup>14</sup>, 41.5% in P Leece et al<sup>4</sup>, 39% in Ali-Risasi et al<sup>15</sup> & 89.5% in Bateman et al<sup>6</sup>.

In the present study Specific and non-specific inflammation was 33.6% and 25% respectively. Specific inflammation was on par with the other studies but Non-specific inflammation was less compared with other studies. Incidences of various epithelial abnormalities in the present study are shown in detail & are compared with other studies in Table 2.

**Table 2: Cervical pap smear findings in various studies in women living with HIV**

	Prese nt study	F Kab ir et al <sup>2</sup>	P Leec e et al <sup>4</sup>	Bate man et al <sup>6</sup>	B M Jha et al <sup>7</sup>	S and rie et al <sup>8</sup>	N.R. Agra wal et al <sup>9</sup>	Am pha n et al <sup>10</sup>	Leib enso n et at <sup>11</sup>	Jenn ifer et al <sup>12</sup>	Pooj a et al <sup>13</sup>	Jenn ifer et al <sup>14</sup>	Ali- Risa si et al <sup>15</sup>	M Carl ucci et al <sup>16</sup>
LSIL	10.2	11	21.4	24.4	2.7	5.4	1.6	8.5	19.1	40	4	26.4	1.5	8
HSIL	4.4	81.1	4.8	38.0	1.47	-	0	3.5	1.19	10.2	2	18	22.9	6.2
ASCUS	8.8	1.58	14.3	16.2	3.19	-	1.6	2.8	0	15.3	2	15.5	6.9	1.8
ASC-H	2.9	4.55	0	3.3	0.73	-	0	0.6	0	1.0	0	0	0.8	0
AGUS	0	0.18	0	0	0.25	-	1.6	0	0	0	0	0	0	0
Specific Inflammati on	33.6	-	33.3	-	32.4	-	50	-	-		25	-	-	8.6
Cytolytic smear	1.4	-	-	-	-	-	-	-	-	-	-	-	-	-
Carcinoma	1.4	1.0	0	7.6	0	0	0	1.05	0	0	0	0	6.9	1.8
Non- specific inflammati on	25	-	66.7	10.6	49.6	-	45.8	84.6	79.8	34.5	28	30	61.1	66.6

## Conclusion

The level of knowledge and awareness needs to increase among the vast majority of illiterate females in our society. Because of their inherent biological vulnerability, cytological screening is effective in preventing cervical cancer is that majority of cancer cases are preceded by a long standing latent period. Pap smear is the standard screening tool to detect the presence of abnormal cells that could become cancerous. Our study shows a high percentage of inflammatory Pap smears, infections and cervical intraepithelial lesions among HIV positives women. Among the various intraepithelial lesions LSIL was the commonest, stressing the need for routine pap smear testing annually in women living with HIV.

## References

1. Seethalakshmi GV, Shoba D, Mohan KR, Sourabh C, Manoharan G, Chandrasekar C et al. A comparative study of Pap smear findings among HIV positive and negative women at Government Hospital of Thoracic Medicine(GHTM), Tambaram. *BMC Infectious Diseases* 2012;12:P35.
2. Firdousi K, Gelderen CV, McIntyre J, Michelow P, Turton D, Adam Y. Cervical intra-epithelial neoplasia in HIV-positive women after excision of the transformation zone – does the grade change?. *S Afr Med J* 2012;102(9):757-760.
3. Bagga R, Wanchu A, Rajwanshi A, Gupta KR, Prasad GRV, Gopalan S et al. Pap smear abnormalities in HIV infected women in north India. *Asia pacific journal of clinical oncology* 2005;1-2-3:77-80.
4. Leece P, Kendall C, Touchie C, Pottie K, Angel JB, Jaffey J. Cervical cancer screening among HIV-positive women. Retrospective cohort study from a tertiary care HIV clinic. *Can Fam Physician* 2010;56:e 425-31.
5. Lizano M, Berumen J, Carranca A. HPV-related carcinogenesis: Basic Concepts, Viral Types and Variants. *Arch Med Res.* 2009;40(6):428-34.
6. Bateman AC, Katundu K, Mulindi HM, Sharon K, Vikrant VS, Michael LH, Benjamin HC, Jeffrey SA, Stringer, Groesbeck P, Parham, Carla JC. The burden of cervical pre-cancer and cancer in HIV positive women in Zambia: a modeling study. *BMC Cancer* 2015;15:541.
7. Jha BM, Patel M, Patel K, Pate J. A study on cervical pap smear examination in patient living with HIV. *National Journal of Medical Research* 2012 March;2(1):81-84.
8. Andrei S, Chiriac C, Bacirea, V, Puscasiu L. Cervical cancer screening in HIV positive patients. A new face for an old tragedy? *Vol 8.Nr 30(4/2012).*
9. Agrawal NR, Anupam, Singh SP. Clinico-epidemiological study of HIV positive female patients. *Indian J. Prev. Soc. Med* 2009 July-December;40(3 & 4):117-119.
10. Amphan C, Chenchit C, Manopchai T, Chulaluk K. Prevalence and cumulative incidence of abnormal cervical cytology among HIV-infected Thai women: a 5.5-year retrospective cohort study. *BMC Infectious Diseases* 2011;11:8.
11. Leibenson L, Shirly B, Avraham B, Mihai M, Yonat SA, Doron S. The prevalence of Human Papillomavirus and cervical cytology abnormalities in women infected with Human Immunodeficiency Virus in Southern Israel. *IMAJ* 2011;13:34-38.
12. Jennifer RM, Deborah C, Margaret H, Anna S, Bruce A, Ed Rybicki et al. Human Papillomavirus prevalence, viral load and pre-cancerous lesions of the cervix in women initiating highly active antiretroviral therapy in South Africa: a cross-sectional study. *BMC Cancer* 2009;9:275.
13. Pooja P, Mala YM, Tripathi R, Das BC, Bhambani S. Human papillomavirus (HPV) infection and abnormal cervical cytopathology among human immuno-deficiency virus (HIV) positive women in Northern India. *J. AIDS HIV* Jan 2014;6(1):1-6.
14. Jennifer RM, Margaret H, Henri C, Bruce RA, Diane DC, Lynn R et al. HIV and pre-neoplastic and neoplastic lesions of the cervix in South Africa: a case-control study. *BMC Cancer* 2006;6:135.
15. Ali-Risasi C, Kristien V, Elizaveta P, Davy VB, Marleen P. Prevalence and risk factors for cancer of the uterine cervix among women living in Kinshasa, the Democratic Republic of the Congo: a cross-sectional study. *Infectious Agents and Cancer* 2015;10:20.
16. Carlucci M, Cimmino A, Fiore MG, Lepera A, Tantimonaco L, Ricco R. The Pap test in HIV-positive women. *Pathologica* 2001 Dec;93(6):651-3.