

Cone beam computed tomography in sialography – report of two cases

Himani Tyagi,¹ Ujjwala Rastogi Awasthi,² Priyanka Katyal,³ Akshay Rathore.⁴

^{1,2,3}Postgraduate student,

⁴Senior Lecturer,

Department of Oral Medicine & Radiology, I.T.S Centre for Dental Studies and Research, Muradnagar, Uttar Pradesh, INDIA.

Address for correspondence:

Priyanka Katyal,
Department of Oral Medicine and Radiology, I.T.S Centre for Dental Studies and Research, Uttar Pradesh, INDIA
E-mail:
priyanka.katyal23@gmail.com

Received: 21/11/2015

Accepted: 19/03/2016

ABSTRACT

Sialolithiasis is the most common obstructive conditions of the major salivary glands, among which submandibular salivary gland calculi are more prevalent. Various imaging modalities are routinely practiced these days for diagnosing sialolithiasis. Today, the fast acquisition of a 3D image using cone beam CT (CBCT) has enabled us to overcome the temporal limitations of medical CT and MRI image acquisition. An initial and precise diagnosis will aid in an effective treatment. We present a series of 2 case reports wherein CBCT sialography was performed to demonstrate the obstructive salivary gland diseases for better interpretation of the ductal system of the gland. CBCT promises to modernize the practice of oral and maxillofacial stomatologist by offering foremost advantages like high resolution, less scan time dose to and the patient.

Keywords: Cone Beam, Computed Tomography, Sialography.

INTRODUCTION

Obstructive conditions of the major salivary glands are the most common abnormalities affecting nearly 1% of the population.¹ Sialolithiasis is the most common among them. The formation of the salivary gland calculi results from deposition of calcium salts around a central part made of desquamated epithelial cells, foreign bodies, bacteria, or mucus. The common site for calculi formation is the submandibular salivary gland because it produces added viscous, mucous and alkaline saliva, with a comparatively high concentration of hydroxyapatites and phosphates. This predisposes to the precipitation of salts. Also, the opening of the main salivary duct of the submandibular (Wharton's duct) is narrower and ascends towards its opening, which also contributes to saliva retention.¹

Symptoms consist of transient, painful, postprandial oedema of the salivary gland, progressively diminishing in 2–3 hours and pain during meals. A decreased production of the saliva may be observed. Fundamental imaging methods of sialolithiasis are: conventional radiographs like panoramic and occlusal radiograph, x-ray sialography, ultrasonography (USG), computed

tomography (CT), magnetic resonance imaging (MRI) and sialoendoscopy which are more regularly practiced these days. Sialography was first performed in 1902 and depicts the ductal structures of glands after injecting a contrast agent into the orifice of a salivary gland duct.^{2,3} Sialography is largely dependent on the imaging modality to which it is coupled. Traditionally, sialography has been collectively used with plain radiographs and this has since become the gold standard with which all other imaging techniques are compared. More recently, three-dimensional (3D) depictions of gland ductal anatomy have been possible by combining sialography with CT or MRI, but these investigative modalities have several restrictions including cost and accessibility. Today, the fast acquisition of a 3D image using cone beam CT (CBCT) has enabled us to overcome the temporal limitations of medical CT and MRI image acquisition. The added advantage of CBCT sialography over conventional sialography is that 3D reconstruction can be performed and then can be analysed from all planes i.e. axial, coronal, sagittal and in any slice thickness from which further cross sectional slices may be obtained in any direction.¹

CBCT promises to modernize the practice of oral and maxillofacial stomatology and radiology by offering added advantages like high resolution, less scan time and dose to the patient. CBCT depicts the glandular structures with enhanced diagnostic capabilities than the conventional imaging because of its isotropic voxels resolution which is not possible with CT. Here, we report two cases where we performed CBCT guided sialography.

Access this article online	
Quick Response Code:	Website: www.innovativepublication.com
	DOI: 10.5958/2393-9834.2016.00013.9

CASE REPORT - 1

A male patient aged 51 years reported to the Department of Oral Medicine and Radiology with a chief complaint of pain in neck on left side since 1 month. There was associated difficulty in neck movements and deglutition on same side. The past dental and medical histories were not contributory. Extra oral examination was non-contributory. On Intraoral clinical examination, bimanual palpation of floor of the mouth revealed a raised nodule on right side. It was non tender on palpation. Relatively there was relatively less of flow of saliva from the Wharton's duct. On radiographic examination (Panoramic and cross-sectional mandibular occlusal radiograph), a solitary, round, well defined radiopacity of size approximately 1.5 x 2cm was found on right submandibular region suggesting a sialolith on right submandibular gland. Based on the clinical and radiographic examination a provisional diagnosis of sialolith in right side submandibular gland/duct was made.

A sialogram was performed to check for further obstructions in the duct. Urograffin 76% (Bayer's India) was used as contrast medium and was injected into the Wharton's duct and post-operative CBCT scan was done. Scan was made using New Tom Giano Machine with FOV of 8x8 at 90 kVp and exposure time of 3.6 seconds.

Data was examined using NNT software. Axial, coronal and sagittal sections in CBCT revealed well defined ovoid radiopacity seen in floor of the mouth measuring 11.3 x 7.8 x 10.4mm in its maximum dimension antero-posteriorly, mesio-distally and supero-inferiorly respectively (**Fig. 1**). Distance from lingual cortical plate to radiopaque structure in axial section measures 3.3mm. The density of was heterogenous with areas of more density interspersed with hypodense areas. These findings were suggestive of sialolith of submandibular duct.

The sialolith was removed via intraoral approach under general anaesthesia and patency of the duct was

maintained. Follow up of the patient showed favourable response.

CASE REPORT - 2

A 49-year-old male patient reported with a chief complaint of pus discharge and intermittent swelling on the lower right side of the jaw since 2 months. The patient's past dental and medical history were unremarkable. Intraoral examination revealed a small non tender nodule on bi-digital palpation in the anterior right floor of the mouth. On radiographic examination (Panoramic, lateral cephalogram and cross-sectional mandibular occlusal radiograph) confirmed a round 2 mm radiopacity in the right submandibular region floor. Based on the clinical and radiographic examination a provisional diagnosis of sialolith in right submandibular gland/ duct was made.

A sialogram was carried out to identify any further obstructions within the duct. A hand injection technique was employed using Urograffin 76% (Bayer India) as the contrast medium and was injected into the warthin's duct. Once the gland was full, the patient was positioned in the New Tom Giano CBCT machine and scan of submandibular region was performed with similar parameters as described in case report 1.

The data were examined using the NNT software. Axial, coronal and sagittal sections in CBCT revealed a solitary well defined radiopacity of dimensions 7.9 x 5.3mm at the level of the right ascending ramus lying obliquely and lingually below the lower border of the mandible at a distance of 9.0mm. There is comparative radiolucency within the radiopacity. Radiopaque dye was seen extending along the right Wharton's duct till the anterior extent of the radiopacity. The findings were suggestive of right Wharton's duct sialolith seen in close proximity to the right submandibular gland as depicted in (**Fig. 2, 3**).

Patient was referred for sialoendoscopy for a conservative treatment approach, but was however lost to follow up.

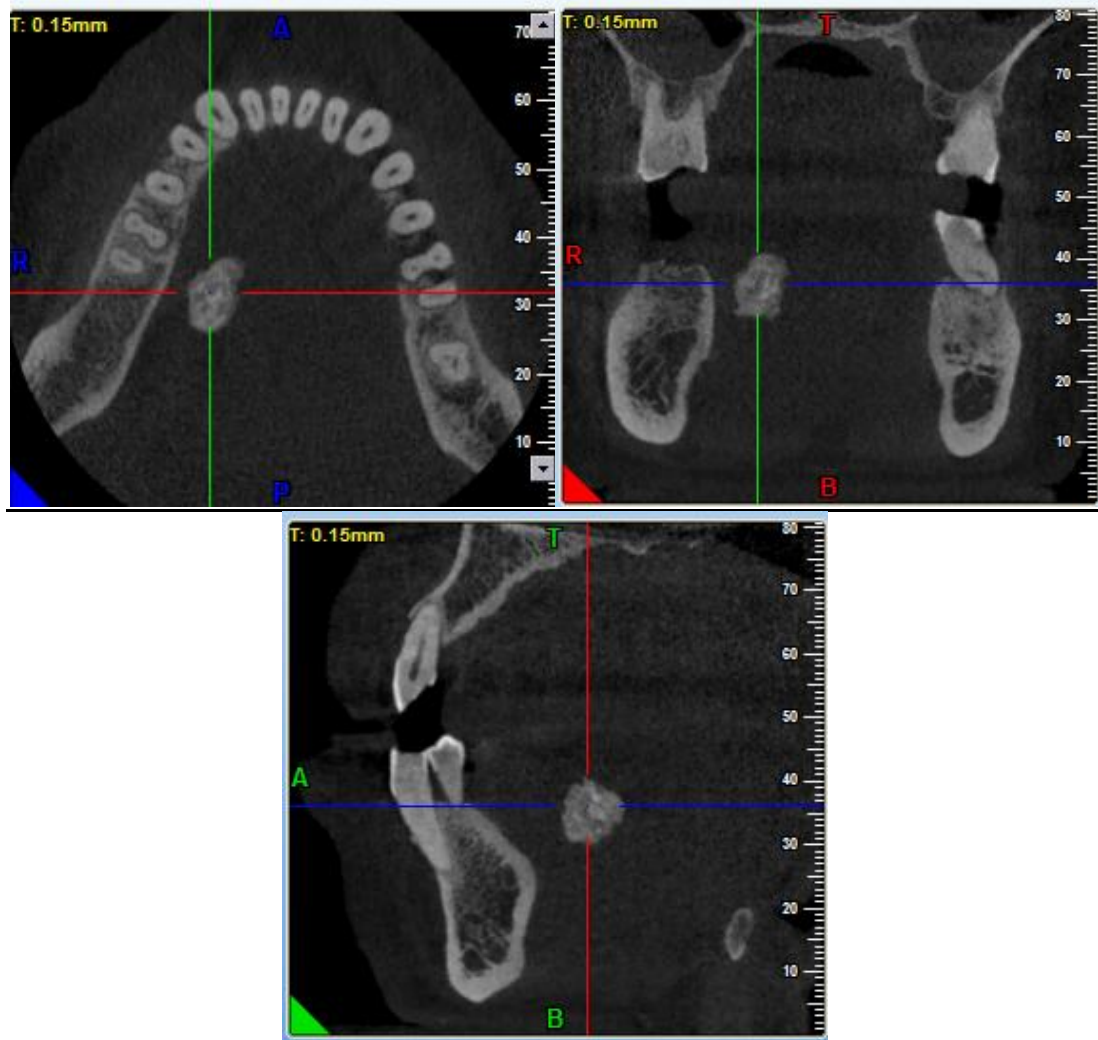


Fig. 1: Pre-operative image of sialolith in CBCT scan seen in (a) Axial section (b) Coronal section (c) Sagittal section

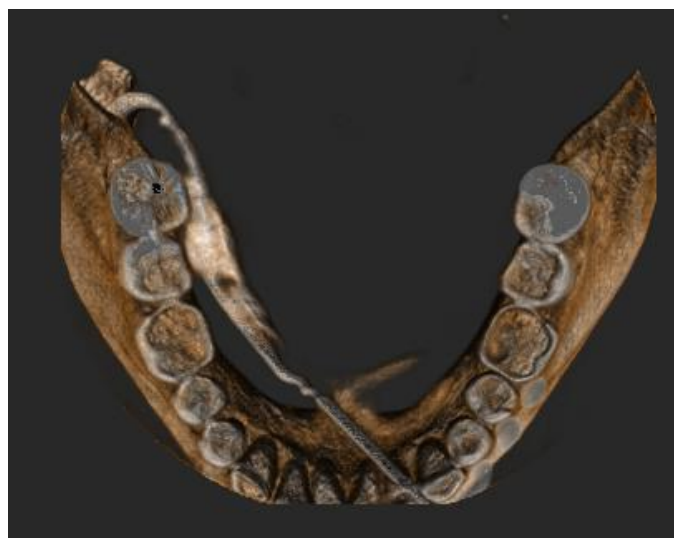

Fig. 2: 3D image of the CBCT guided sialography of right submandibular gland. The needle of the cannula and the Wharton's duct are clearly visualized in the floor of the mouth. The sialolith can be appreciated in the posteromedial aspect of the mandible

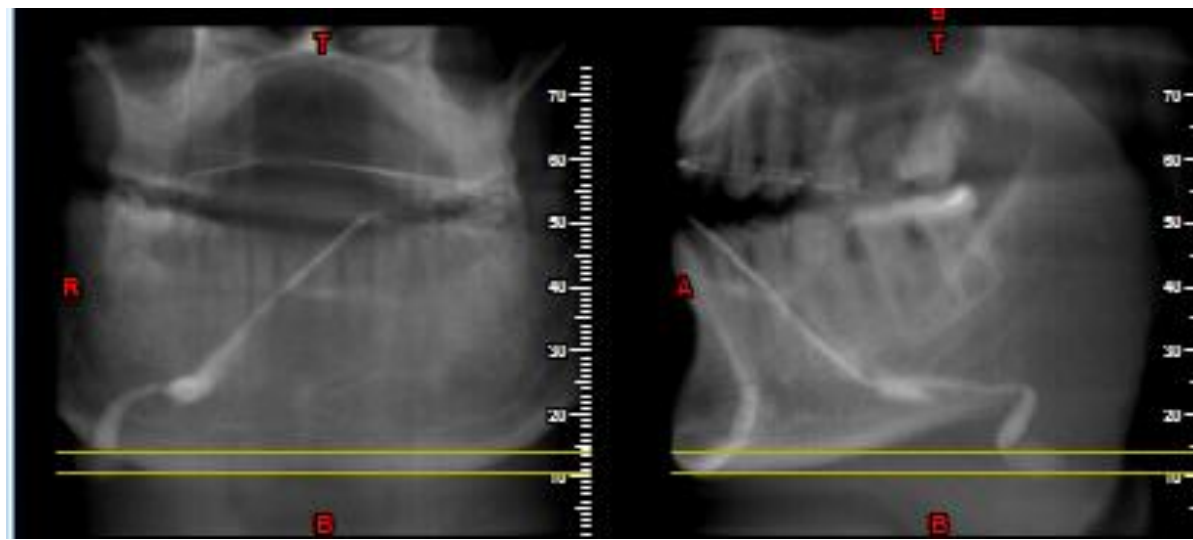


Fig. 3: Scout images of CBCT scan taken during the sialography

DISCUSSION

Sialography is an outstanding imaging modality for representing duct anatomy and the presence of stones and strictures in gland or the course of duct. The added benefit is that the interventional sialographic procedures can be performed and radiopaque structures can be identified. Imaging plays a very crucial role in the diagnosis of cause, extent and effects of obstruction.⁴ Various specialized modalities have emerged so far including contrast CT, ultrasonography, sialoendoscopy and CBCT. MRI is superior of all modalities to visualize the soft tissue structures. The sensitivity and specificity for CBCT are superior and are comparable to the most favourable results for 3D imaging modalities such as medical CT and MRI sialography.

In both of our cases the CBCT scan identified the main duct, the primary intraglandular ducts and the obstruction. A scan parameter using the FOV 8x8 was chosen. Decreasing the voxel size will enable smaller filling defects, but dose will be amplified proportionately. In the first case 11.3mmx7.8 mm and in the second case 7.9mmx5.3mm calculus respectively were easily identified in the scan. Prior to the patient being scanned for scout image, contrast containing 300mg Iodine is introduced to the sialography catheter. When CBCT is undertaken the patient's position has to be secured in the unit using chin cup. However, this does not stabilize the soft tissues and so it is important that the patient be instructed not to move and swallow during rotation because this could lead to marked artefact that lead the scan being undiagnostic.

CBCT sialography was described first by Drage and Brown in 2009, in a case report of 2 patients with salivary gland obstruction. Drage and Brown believed that CBCT sialography was indicated and beneficial when conventional sialography was assumed to be insufficient in complex cases of salivary duct obstruction. They also stated that selection criteria were

requisite, that the CBCT sialography would expose the patients to higher x-ray radiation and for that reason must be performed for more complicated cases. They estimated the radiation doses that were delivered to the patients with CBCT sialography and interpreted that the radiation dose exposure in CBCT was comparable to conventional fluoroscopic procedures.⁵ Literature research shows that when CBCT aided sialography is indicated a smaller FOV in combination with lower kVp and mA setting (15 cm FOV, 80 kVp and 10 mA) is recommended because the effective doses is comparable to plain radiography sialography.³ The effective dose (*E*) change in relationship to changes in CBCT field of view (FOV), peak kilovoltage (kVp) and milliamperage (mA). Specifically, *E* decrease from a maximum of 932 μ Sv (30 cm FOV, 120 kVp, 15 mA) to 60 μ Sv (15 cm FOV, 80 kVp, 10 mA) for a parotid gland study and to 148 μ Sv (15 cm FOV, 80 kVp, 10 mA) for a submandibular study. The collective series of plain radiographs made during sialography of the parotid and submandibular glands yield effective doses of 65 μ Sv and 156 μ Sv, respectively. However there is no established optimal exposure parameter for CBCT sialography till date.

Besides applications in other research studies, Li et al in 2011 reported for the first time a case of atypical Stafne bone cavity using CBCT. It showed comprehensive information of the content of the cavity and could help in its definitive diagnosis.⁶ Wahed et al. in their case series of salivary gland lesions concluded that it would be advisable to perform CBCT sialography in case of obstructive salivary gland diseases for better demonstration of the ductal system of the gland.⁷ Jadu et al. conducted a series of studies that led to the development of a new technique for imaging the parotid and submandibular salivary glands using sialography combined with CBCT. In their research, they reported that delicate secondary branches of the ducts and the

parenchyma of the salivary glands were more detectable on CBCT images than plain film sialography.³

CONCLUSIONS

Since the introduction of 3D cone beam CT to dentistry in 1998, its application has become routine for pre-surgical, dental implant and third molar assessment. Potential CBCT applications, such as in salivary gland calculus and lesions are receiving attention due to diagnostic performance with 3D CBCT due to its high spatial resolution. Also the radiation exposure associated with CBCT has to be considered carefully before intervention. Well-designed studies to establish optimal exposure parameters must be endeavoured.

REFERENCES

1. Jadu FM, Lam EW. A comparative study of the diagnostic capabilities of 2D plain radiograph and 3D cone beam CT sialography. *Dentomaxillofac Radiol.* 2013;42:1-8.
2. Jadu FM, Hill ML, Yaffe MJ, Lam EW. Optimization of exposure parameters for cone beam computed tomography sialography. *Dentomaxillofac Radiol.* 2011;40:362–68.
3. Jadu FM, Yaffe MJ, Lam EW. A comparative study of the effective radiation doses from cone beam computed tomography and plain radiography for sialography. *Dentomaxillofac Radiol.* 2010;39:257–63.
4. Elenjickal TJ, Krishna I, Perumal RL, Verma S. Resourcefulness of cone beam computed sialography in detection of multiple radiolucent sialoliths: A case report. *J Indian Acad Oral Med Radiol.* 2014;26:425-27
5. Drage NA, Brown JE. Cone beam computed sialography of sialoliths. *Dentomaxillofac Radiol.* 2009;38(5):301-05.
6. Li B, Long X, Cheng Y, Wang S. Cone beam CT sialography of Stafne bone cavity. *Dentomaxillofac Radiol.* 2011;40:519–23.
7. Abdel-Wahed N, Amer ME, Abo-Taleb NS. Assessment of the role of cone beam computed sialography in diagnosing salivary gland lesions. *Imaging Sci Dent.* 2013;43:17-23.

How to cite this article: Tyagi H, Awasthi UR, Katyal P, Rathore A. Cone beam computed tomography in sialography - report of two cases. *J Dent Specialities* 2016;4(1):65-69.

Source of Support: NIL

Conflict of Interest: All authors report no conflict of interest related to this study.