

# The pliancy of pedicled buccal fat pad used in reconstruction of oral submucous fibrosis - a case report

Gurjap Singh,<sup>1</sup> Neelima Gehlot,<sup>2</sup> Sriram Krishnan,<sup>3</sup> Abhishek Kapoor.<sup>4</sup>

<sup>1,3</sup>Reader,

<sup>2</sup>Professor and Head,

<sup>4</sup>Senior Lecturer,

Department of Oral and Maxillofacial Surgery, I.T.S Dental College and Research Centre, Greater NOIDA, Uttar Pradesh, INDIA

## Address for Correspondence:

Gurjap Singh,

Reader, Department of Oral and Maxillofacial Surgery, I.T.S Dental College and Research Centre, Greater NOIDA, Uttar Pradesh, INDIA

E-mail: Drgurjap79@gmail.com

Received: 08/12/2015

Accepted: 19/03/2016

## ABSTRACT

Oral submucous fibrosis (OSF) has multifactorial aetiology which is considered to include betel quid chewing, excessive use of chillies and spices, poor nutrition and deficiency of vitamin and iron. Various treatment modalities such as nutritional supplement, intralesional steroid and placental extract injections, antioxidants, and physiotherapy have been used for conservative management of OSF. Surgical treatment includes fibrotomy (release of fibrotic bands), coronoidectomy, third molar extractions and/ or reconstruction of buccal mucosa with various autografts and allografts. A 30-year old male patient reported to the Out Patient Department of Oral and Maxillofacial Surgery with the chief complaint of inability to open the mouth and difficulty in eating. Based on peculiar clinical findings, provisional diagnosis of OSF was established. Under general anesthesia, horizontal mucosal incision was placed along the occlusal plane with the surgical knife on the buccal mucosa 1cm below Stenson's duct orifice bilaterally. The fibrous bands were palpated and using fingers dissection was carried out to release fibrous bands which were followed by bilateral coronoidectomy. Pedicled buccal fat pad (BFP) was used as a graft material to cover the areas on both sides. Healing was satisfactory with no breakdown or liquefaction necrosis post operatively. Approximately 30 mm of interincisal distance was achieved and maintained postoperatively with vigorous mouth opening exercises. BFP can be used effectively as a grafting material in the surgical management of OAF with good functional and esthetic outcome.


**Key words:** Fibrosis, Fat Pad, Oral Submucous, Oral Mucosa

## INTRODUCTION

Oral potentially malignant disorders include leukoplakia, erythroplakia, submucous fibrosis and lichen planus, which were earlier termed as premalignant lesions and premalignant conditions. In modern literature, oral submucous fibrosis (OSF) was first described by Schwartz in 1952 and is more commonly found in the Asian subcontinent and the Far East population but, an increasing number of cases are being seen in other countries with transmigrated populations.<sup>1</sup> OSF has multifactorial aetiology which is considered to include betel quid chewing, excessive use of chillies and spices, poor nutrition and deficiency of vitamins and iron.<sup>2</sup>

Various treatment modalities such as nutritional supplement, intralesional steroid, placental extract injections, antioxidants, and physiotherapy have been

used for conservative management (Table 1) of OSF.<sup>3</sup> Surgical treatment includes fibrotomy (release of fibrotic bands), coronoidectomy, third molar extractions and/ or reconstruction of buccal mucosa (Table 2) with various autografts and allografts.<sup>3</sup> Autografts can be either a local or distant flaps. Local flaps have much advantage over distant flaps like ease of procurement, lesser morbidity and functional impairment. The type and size of intraoral defect determines the flap/ techniques to be used. The use of BFP as a grafting source in the closure of intraoral defect has gained popularity.

Access this article online	
Quick Response Code:	Website: www.innovativepublication.com
	DOI: 10.5958/2393-9834.2016.00018.8

**Table 1: Conservative management of oral submucous fibrosis**

Modulators of inflammation	Steroids
	Placental extracts
	Interferon $\gamma$
	Immunized milk
Modulators of vascularity/ relieve ischemia	Pentoxifylline
	Tea pigments
	Nylidrin
	Buflomedial hydrochloride
Nutritional support and to combat reactive oxygen species	$\beta$ -carotene
	Lycopene
	Vitamins
	Micronutrients
Fibrinolysis	Collagenase
	Hyaluridase
	Chymotrypsin

**Table 2: Flaps used for covering surgical defects after release of fibrous bands**

Extraoral flaps	Split thickness skin graft
	Nasolabial flap
	Temporalis pedicled flap
	Superficial temporal fascia pedicled flap
Intraoral flaps	Buccal pad of fat
	Palatal island flap
	Tongue flap
Microvascular-free flaps	Anterolateral thigh flap
	Radial forearm free flap
Alloplasts	Artificial dermis
	Collagen membrane

### CASE REPORT

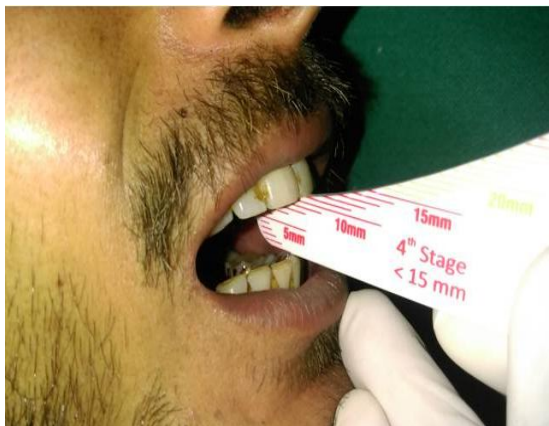A 30-year-old male patient reported to the Out Patient Department of Oral and Maxillofacial Surgery with the chief complaint of inability to open the mouth and difficulty in eating. The patient started developing aforesaid problems for the last 1 year, which worsened gradually. The medical history of the patient was non-significant. The patient did reveal a habit of gutka chewing (2-4 packets/day) for last 10 years and bidi smoking since last 5 years. Patient had undergone conservative therapy (intralesional injections) at his native place for period of 1 month, which resulted in mild reduction in symptoms. Extraoral examination of the patient revealed reduced jaw movements. An intraoral examination evidenced reduced interincisal mouth opening approximately 10 mm (Fig. 1) and presence of blanching in buccal and retromolar regions with dense fibrotic bands. Based on peculiar clinical

findings, provisional diagnosis of OSF was established. Orthopantomogram (Fig. 2) showed maxillary and mandibular third molars to be impacted bilaterally; elongated coronoid process. Patient was motivated for cessation of tobacco chewing and smoking habits.

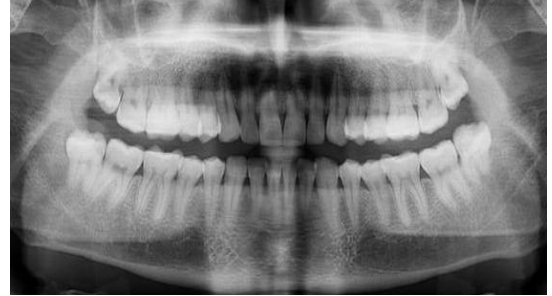The surgery was performed under general anesthesia with light band nasal intubation. The horizontal mucosal incision was placed along the occlusal plane with the surgical knife on the buccal mucosa 1 cm below Stenson's duct orifice bilaterally. The incision was extended from the corner of the mouth anteriorly to the pterygomandibular raphe posteriorly. The fibrous bands were palpated and using fingers blunt dissection was carried out to release fibrous bands bilaterally. The coronoid process was approached from the same surgical site; which was facilitated by extending incision along the external oblique ridge of the mandible.

The coronoid processes were exposed by subperiosteal dissection and osteotomy were carried out using bur at the base of coronoid process and was finished using chisel and mallet i.e. bilateral coronoidectomy. Impacted third molars both maxillary and mandibular were removed bilaterally (Fig. 3). The mouth was then forced to open with the Heister mouth gag to a satisfactory range of 38 mm interincisal opening (Fig. 4). Pedicled BFP was used as a graft material to cover the areas on both sides. To cover raw mucosal defect BFP was approached posterior to the zygomatic buttress. Blunt dissection was carried through the submucosa to reach the BFP. Popped out yellowish buccal fat pad was mobilized gently along its thin capsule/covering until a significant amount was obtained to cover the defect without tension. This was done by using small artery forceps and gently letting out the buccal fat pad to the raw area. The BFP was teased into the mouth gently by applying external pressure over the cheek until a sufficient amount was obtained to cover the defect without tension. The BFP was held in place by multiple simple interrupted sutures using 3/0 polyglactin 910 (Fig. 5, 6).

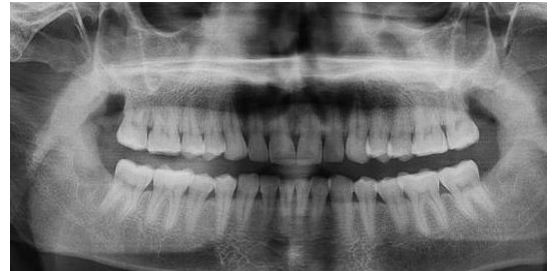Patient was kept on intravenous antibiotics which include Amoxicillin plus clavulanic acid 1.2 gm twice daily and intravenous Metronidazole 500 mg thrice daily for three days postoperatively. Pain control was achieved using intramuscular injections of Diclofenac sodium twice daily for first 48 hours postoperatively; followed by oral route. The patient was advised liquid diet postoperatively for at least 1-2 week. Vigorous mouth opening exercises were started from 5<sup>th</sup> day postoperatively using Heister mouth gag.



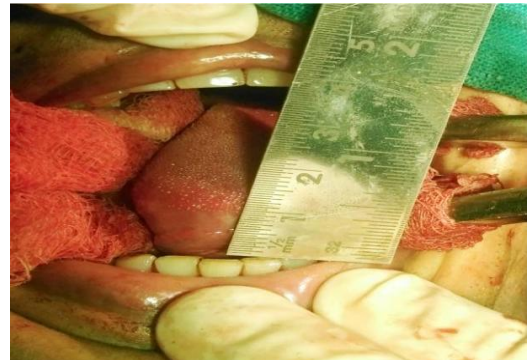**Fig. 1: Restricted mouth opening (10mm)**



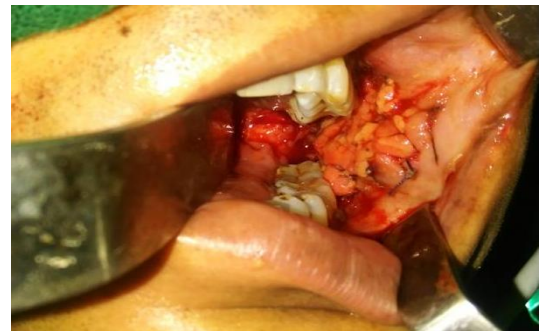**Fig. 2: Orthopantomogram showing maxillary and mandibular third molars to be impacted bilaterally**



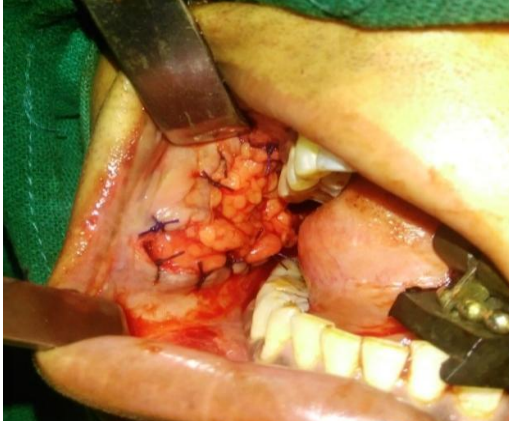**Fig. 3: Postoperative Orthopantomogram showing bilateral coronoidectomy and missing maxillary and mandibular third molars**



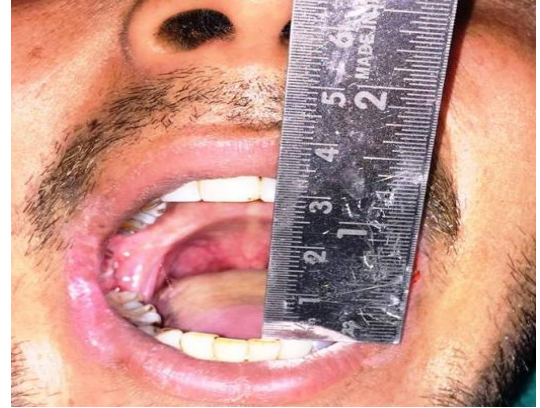**Fig. 4: Intraoperative interincisal opening of 38 mm**



**Fig. 5: Intraoperatively left side buccal mucosa reconstructed with buccal fat pad graft and stabilized with sutures**



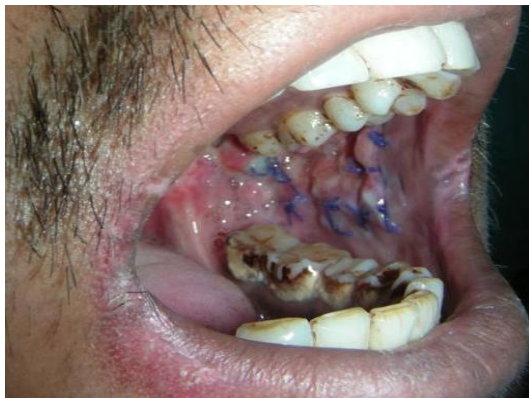**Fig. 6: Intraoperatively right side buccal mucosa reconstructed with buccal fat pad graft and stabilized with sutures**



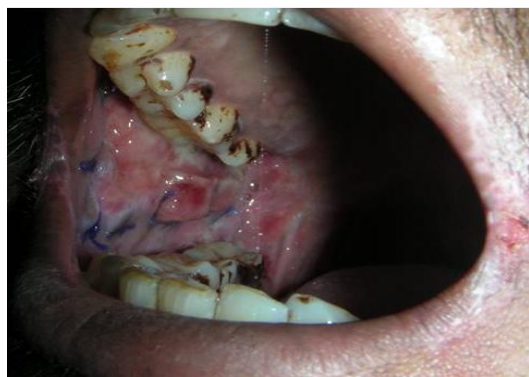**Fig. 9: Interincisal opening after 1 month**

### RESULT

The procedure was successful in achieving desired goal of adequate mouth opening. Healing was uneventful with no breakdown or liquefaction necrosis post operatively (Figure- 7, 8). Approximately 30 mm of interincisal distance was achieved and maintained postoperatively with vigorous mouth opening exercises (Figure-9).



**Fig. 7: Left side buccal mucosa healing after 1 month**



**Fig. 8: Right side buccal mucosa healing after 1 month**

### DISCUSSION

The clinical picture of OSF is characterized by remission and relapses of vesicle formation, ulceration/stomatitis, blanching, intolerance to spices, alteration in salivation, burning sensation in the mouth, depapillation of the tongue, pigmentation of the oral mucosa, referred pain in the temporomandibular region, stiffness of the oral mucosa, progressive difficulty in opening the mouth and difficulty in phonation.

Whilst the precise mode of action of the various chemical constituents of areca nut on mucosal tissue is still unclear, it has been suggested that these constituents interfere with the processes of deposition or of breakdown of collagen or both.<sup>4</sup> The effect of cumulative betel quid exposure on collagen related genes in the pathogenesis of OSF has generated much interest.<sup>5</sup> The rate of transformation (< 7%) of oral submucous fibrosis cases into oral cancer has been reported in various studies.<sup>3,6</sup> In a recent retrospective study malignant transformation of OSF was reported to be 4.2% and it was also observed that incidence of oral cancer concomitant with OSF to be 25.77%.<sup>6</sup> Such coexistence of potentially malignant disorder and oral cancer emphasize importance of proper screening and long term follow-up.

A classification system for OSF based on mean interincisal opening (MIO) was proposed by Khanna and Andrade: stage I, early OSF without trismus (MIO >35 mm); stage II, mild to moderate disease (MIO 26–35 mm); stage III, moderate to severe disease (MIO 15–25 mm); stage IVa, severe disease (MIO <15 mm); and stage IVb, extremely severe–malignant/ premalignant lesions noted intraorally.<sup>7</sup> Various treatment modalities such as intralesional steroid and placental extract injections, antioxidants, nutritional supplement, and physiotherapy have been used with inconsistent results.<sup>8</sup> Surgical management is considered as the authoritative treatment modality in advanced stage of the disease.<sup>7</sup> Surgical option not only provides access for the intraoral observations for malignant transformation but also provides symptomatic relief. Simple excision of the fibrous bands and propping the

mouth open to allow secondary epithelialization causes rebound fibrosis and disability during healing.

The buccal fat pad is an encapsulated, mass of specialized fatty tissue which acts as gliding pads when masticatory and mimetic muscles contract, and cushions important structures from forces generated by muscle contraction. The buccal fat pad has a body and four processes. The body is located behind the zygomatic arch and is divided into 3 lobes – anterior, intermediate and posterior, in accordance with the structure of the lobar envelopes, the ligaments and the feeding vessels. Four processes (buccal, pterygoid, superficial and deep temporal) extend from the body into surrounding spaces such as the pterygomandibular and infratemporal fossae. The buccal fat pad flap is an axial flap. The facial, transverse facial and internal maxillary arteries and their anastomosing branches enter the fat to form a sub-capsular vascular plexus.

BFP was used for closure of oroantral communications by Egyedi and for reconstruction of oral defects after tumor resection by Neder. Application of BFP for oral submucous fibrosis was described by Yen in 1986 that can cover oral defects up to 60 mm X 60 mm and 6 mm in thickness. He found no obliteration of the oral vestibule and very little morbidity at the donor site as compared to other local flaps.<sup>9</sup>

The use of buccal fat pad is contraindicated in patients with prior local radiotherapy, malar hypoplasia, thin cheeks, Down's syndrome. Three approaches for harvesting buccal fat pad had been described, which are Matarasso's method where incision is placed 1cm below the opening of parotid duct; where incision is placed behind the opening of parotid duct and third technique include incision high in superior gingivobuccal sulcus.

Histological examination of pedicled buccal fat pad graft healing in oral submucous fibrosis has been microscopically studied and documented by weekly observation.<sup>10</sup> They observed buccal fat pad graft get fully covered by stratified squamous epithelium by 5<sup>th</sup> week postoperatively.

## CONCLUSION

Buccal fat pad can be used effectively and easily grafting material in the surgical management of OSF with good functional and esthetic outcome. The vigorous postoperative physiotherapy is necessary to maintain adequate postoperative mouth opening. Considering various treatment modalities available for OSF, use of buccal fat pad graft is worthy of consideration.

## REFERENCES

1. Reichart PA, Philipsen HP. Oral submucous fibrosis in 31-year-old Indian women: first case report from Germany]. *Mund Kiefer Gesichtschir.* 2006 May;10(3):192-96.
2. Ahmad MS, Ali SA, Ali AS, Chaubey KK. Epidemiological and etiological study of oral submucous fibrosis among gutkha chewers of Patna, Bihar, India. *J Indian Soc Pedod Prev Dent.* 2006 Jun;24(2):84-89.
3. Angadi PV, Rao S. Management of oral submucous fibrosis: an overview. *Oral Maxillofac Surg.* 2010 Sep;14(3):133-42.
4. Lin HJ, Lin JC. Treatment of oral submucous fibrosis by collagenase: effects on oral opening and eating function. *Oral Dis.* 2007 Jul;13(4):407-13.
5. Tilakaratne WM, Klinikowski MF, Saku T, Peters TJ, Warnakulasuriya S. Oral submucous fibrosis: review on aetiology and pathogenesis. *Oral Oncol.* 2006 Jul;42(6):561-68.
6. Chourasia NR, Borle RM, Vastani A. Concomitant Association of Oral Submucous Fibrosis and Oral Squamous Cell Carcinoma and Incidence of Malignant Transformation of Oral Submucous Fibrosis in a Population of Central India: A Retrospective Study. *J Maxillofac Oral Surg.* 2015 Dec;14(4):902-96.
7. Khanna JN, Andrade NN. Oral submucous fibrosis: a new concept in surgical management. Report of 100 cases. *Int J Oral Maxillofac Surg.* 1995 Dec;24(6):433-39.
8. Borle RM, Borle SR. Management of oral submucous fibrosis: a conservative approach. *J Oral Maxillofac Surg.* 1991 Aug;49(8):788-91.
9. Yen DJ. Surgical treatment of submucous fibrosis. *Oral Surg Oral Med Oral Pathol.* 1982 Sep;54(3):269-72.
10. Chao CK, Chang LC, Liu SY, Wang JJ. Histologic examination of pedicled buccal fat pad graft in oral submucous fibrosis. *J Oral Maxillofac Surg.* 2002 Oct;60(10):1131-34.

**How to cite this article:** Singh G, Gehlot N, Krishnan S, Kapoor A. The pliancy of pedicled of oral submucosis fibrosis – a case report. *J Dent Specialities* 2016;4(1):90-94.

**Source of Support:** NIL

**Conflict of Interest:** All authors report no conflict of interest related to this study.