

# Immediate implant placement in the esthetic zone - a clinical report

Shaily Tyagi,<sup>1</sup> Divya Ratan Dahiya,<sup>2</sup> Praful Mehra,<sup>3</sup> Gaurav Issar.<sup>4</sup>

<sup>1,2</sup>Postgraduate student,

<sup>3</sup>Reader,

<sup>4</sup>Senior Lecturer,

Department of Prosthodontics,  
I.T.S- Centre of Dental Studies and  
Research, Delhi – Meerut Road,  
Ghaziabad, Uttar Pradesh, INDIA.

## Address for Correspondence

Shaily Tyagi,

Department of Prosthodontics,  
I.T.S- Centre of Dental Studies and  
Research, Delhi – Meerut Road,  
Ghaziabad, Uttar Pradesh, INDIA.  
E-mail: shailydoc@gmail.com

Received: 24/12/2015

Accepted: 20/03/2016

## ABSTRACT

Implant placement in esthetic zone is a challenge in implant dentistry because of the interplay of multiple factors like adjacent restoration, bone, mucosa, and lip line that result in a serviceable prosthesis complementing the natural dentition. The philosophy behind implant/restorative protocols is preservation. If bone loss occurs gingival architecture will collapse, which will lead to aesthetic compromise and inadequate bone for implant placement. This case report aims to describe important aspects of implant placed immediately into fresh extraction sockets, by evaluating the changes that takes place in hard and soft tissues occurring upto 2 years following the implant placement.

**Keywords:** Atraumatic, Extraction, Fresh Extraction Sockets

## INTRODUCTION

Implant success has been one of the important topics and many researchers have laid down the guidelines for evaluating the same.

There are four surgical approaches for the placement of implants.

1. Two stage placement of the implant with a cover screw in which a fixture is placed after a post-extraction healing phase. This is followed by an integration period prior to restoration.
2. One stage placement of the implant with healing abutment.
3. Immediate implant placement at the time of extraction.
4. Immediate provisionalization or “load”

The success of these different approaches is well documented in the literature.<sup>1</sup>

Loss of a tooth and its replacement with an implant-supported restoration in the esthetic zone pose various challenges when the goals are optimal function and esthetics.<sup>2,3,4</sup> The greatest reduction of the alveolar bone occurs in the first 6 months to 2 years post extraction.<sup>5</sup>

## CLINICAL REPORT

A 27 year old male patient presented to the Department of Prosthodontics, I.T.S- CDSR, Delhi - Meerut Road, Ghaziabad with chief complaint of fractured tooth in upper left front region [Fig. 1]. Radiographic examination revealed horizontal root fracture of left maxillary central incisor below the cervical to the middle third with unfavourable prognosis [Fig. 2]. All the available treatment options were told to the patient and the definitive procedure which included immediate implant placement and early loading was finalized. The patient was very concerned about the esthetics and was very interested for the restoration of his teeth and so he opted for the proposed procedure.

Pre-surgical radiographic evaluation was carried out for appropriate treatment planning. After proper treatment planning endo-osseous implant (Adin Touareg Internal hex square thread, Israel) measuring 4.2 × 11.5 mm in dimension was selected. The fractured tooth was atraumatically removed with the help of periostomes. After extraction, the site was thoroughly degranulated using curettes. The socket irrigation was done with Povidine Iodine and carefully examine the intact socket walls. The socket was evaluated for osseous defects.

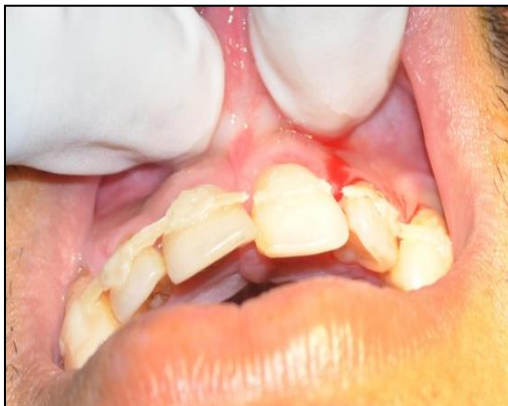A sequential drilling was carried out with 2.2, 2.8, 3.2, 3.65mm. Implant placement was done in the extraction socket with the insertion torque of 45 Ncm [Fig. 4]. The first thread of implant was placed 1.5 mm apical to crestal bone of the socket to gain primary stability. Post-operative periapical radiograph was taken [Fig. 5]. Transmucosal healing was initiated with 4×4 gingival former.

The patient was administered an analgesic (Ibuprofen 800 mg, every 4 to 6 hours) for 7 days and an antibiotic (Augmentin 625 mg, 2 times daily) for 7 days.

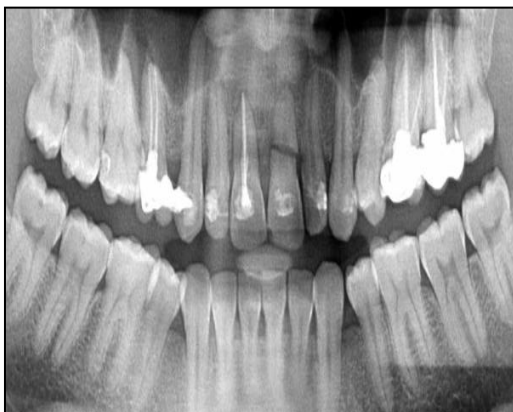Access this article online	
Quick Response Code:	Website: www.innovativepublication.com
	DOI: 10.5958/2393-9834.2016.00019.X

Furthermore, he was advised Chlorhexidine digluconate (0.1%) solution 4 times a day for 5 weeks for rinsing. Final impression was made by open tray technique using polyether impression material (Impregum™ Penta™ Soft, 3M ESPE, St Paul, MN). It was poured with Type-IV dental stone (Ultrarock, Kalabhai Karson Pvt. Ltd., Mumbai) and master cast was obtained. Cast was mounted on a semi adjustable articulator. The mounted cast was then sent to laboratory for fabrication of cement retained milled crown (Zirconia with veneered emax).

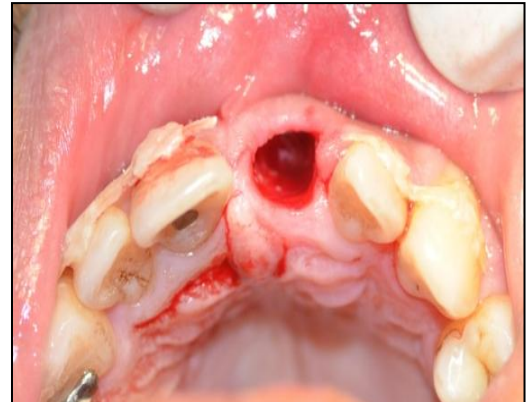After 2 weeks of healing period, the implant was loaded with cement retained milled crown [Figure 6]. Final cementation was performed with adhesive resin (RelyXUnicem transparent, 3M ESPE, St Paul, MN).



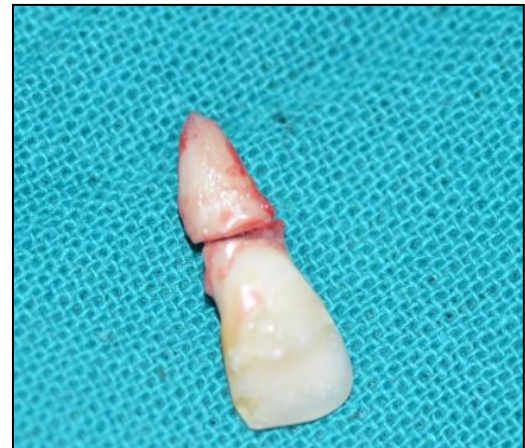**Fig. 1:** Pre-operative intraoral frontal view of fractured left maxillary central incisor



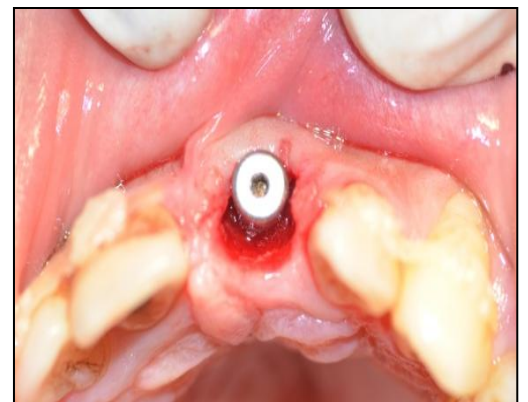
**Fig. 2:** Pre-operative OPG of fractured left maxillary central incisor



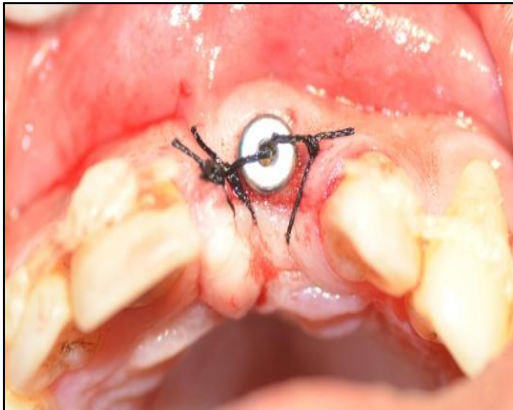
**Fig. 3(a):** Atraumatic extraction of without flap reflection resulted in well preserved bone and soft tissue architecture



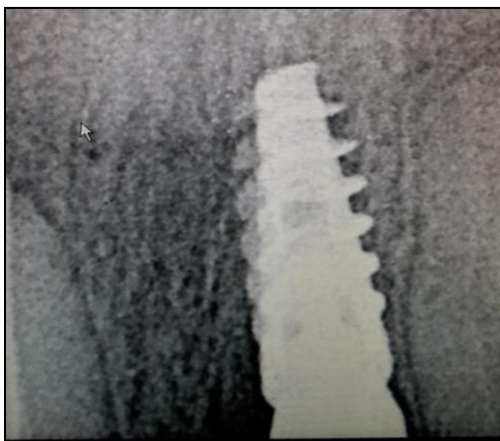
**Fig. 3(b):** Extracted fractured maxillary left central incisor



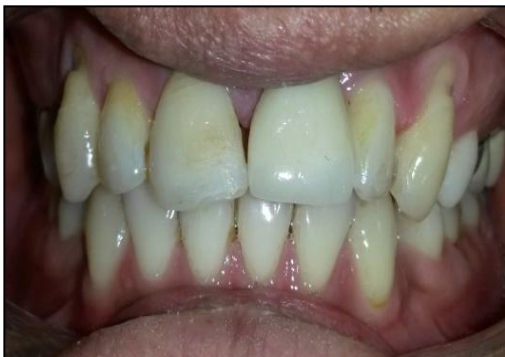**Fig. 4(a):** A 4.2 × 11.5 mm tapered self-threaded implant was inserted to desired depth after sequential osteotomy



**Fig. 4 (b): Tissues sutured**



**Fig. 5: IOPA showing implant placement**



**Fig. 6: Final prosthesis**

**DISCUSSION**

The problem in immediate implants is the difficulty of maintaining or reforming a papilla between the implant and the tooth. The reason behind this difficulty is that the biologic width around an implant is apical to the implant abutment connection.<sup>6</sup> In the esthetic zone, the implant is mostly placed approximately 4mm apical to the height of the buccal tissue of the adjacent teeth.<sup>7</sup> Because all implants presently available in the market have flat platforms, which result in the implant almost positioned below the interimplant bone crest. The interdental location of the implant causes the placement

of the biologic width subcrestally. This differs from a natural tooth, because in a healthy tooth, the biologic width always forms supracrestally. Therefore, the interdental tissue lacks the crestal support that exists between an implant and a tooth.<sup>8</sup>

Cohen first described the col in 1959 as buccal and lingual peaks of keratinized tissue having a non-keratinized or parakeratinized interproximal area<sup>9</sup>, very little has been done to determine when the interproximal papilla with its col is present.

In 1961 Kohl and Zander stripped the interproximal tissue on monkeys to determine if the papilla and col would reform<sup>10</sup>. They found that the papilla reformed by the end of the eighth postsurgical week. In 1963 Matherson and Zander<sup>11</sup> also studied the interproximal papilla and the shape of the col. Their study showed that the shape of the contact area was taken up by the col of the adjacent teeth and not the underlying bone. In addition, Stahl showed that use of interproximal stimulation can modify the degree of keratinisation of the col area.

In 1992 Tarnow, Magner and Fletcher<sup>12</sup> did a study to evaluate whether the vertical distance between the contact point and the crest of bone in determining the presence of the interproximal papilla was significant. When the distance was 5 mm or less the papilla was almost always present and when the distance was 7 mm or more the papilla was usually missing.

Other variables, such as extent of inflammation, pocket probing depth of the adjacent teeth, fibrous or oedematous nature of the tissue, anterior or posterior teeth, previous history of non-surgical and surgical therapy, and the presence of proximal restorations, may all contribute to the presence or absence of the papilla; however, this paper has examined one significant factor; i.e., the distance from the base of the contact area to the crest of bone in 288 sites<sup>12</sup>.

A history of previous periodontal surgery plays a part in the presence or absence of the papilla reforming. Examination of the sites that had undergone previous surgery did not seem to show any definitive trend.

It is interesting to note that at 5 mm, the papilla was present 98% of the time, at 6 mm, only 1 mm more, it was present 56% of the time, and at 7 mm it was only present 27% of the time. While the answer as to why such a significant difference existed between these 3 measurements is unknown; future research is indicated to examine other variables such as the mesio-distal distance between the two teeth and total volume of the embrasure space to determine their contribution to the formation of the interproximal papilla<sup>12</sup>.

**CONCLUSION**

Immediate implant placement following tooth extraction has been found to be a feasible and predictable solution to tooth loss. This case report demonstrates minimally invasive surgical technique to

achieve greater efficiency, ease of procedure and shorter time involved with minimum postextraction complications. This procedure is more difficult to execute than the conventional procedure. Therefore, we should be able to enhance the definitive treatment offered to the patient in regard to the treatment time, patient comfort, cost and esthetics.

## REFERENCES

1. Shrub JR, Jurkzik BA, Tuna T. Prognosis of immediately loaded implants and their restorations: a systematic literature review. *J Oral Rehabil* 2012;39:704-17.
2. Gamborena I, Blatz MB. Transferring the emergence profile of single-tooth implant restorations. *Quintessence Dent Technol* 2004;27:119-32.
3. Sadan A, Blatz MB, Salinas TJ, Block M. Single-implant restorations: A contemporary approach for achieving a predictable outcome. *J Oral Maxillofac Surg* 2004;62:73-81.
4. Sadan A, Blatz MB, Bellerino M, Block M. Prosthetic design considerations for anterior single-implant restorations. *J Esthet Restor Dent* 2004;16:165-75.
5. Carlsson RA, Persson AL. Morphologic changes of the mandible after extraction and wearing of dentures. A longitudinal, clinical and X-ray cephalometric study covering 5 years. *Odontologic Review* 1967;18: 27-54.
6. Hermann JS, Buser D, Schenk RK, Higginbottom FL, Cochran DL. Biologic width around titanium implants. A physiologically formed and stable dimension over time. *Clin Oral Implants Res* 2000;11:1-11.
7. Sullivan P. Guidelines for optimal fixture placement. In: Parel SM, Sullivan DY, eds. *Esthetics and osseointegration*. Dallas: Osseointegration Seminars Inc.; 1989.
8. Tarnow D, Elian N, Fletcher P, Froum S, Magner A, Cho SC, Salama M, Salama H, Garber DA. Vertical distance from the crest of bone to the height of the interproximal papilla between adjacent implants. *J Periodontol* 2003;74:1785-88.
9. Cohen B. Morphological factors in the pathogenesis of periodontal disease. *Br Den J* 1959;107:31-39.
10. Kohl JT, Zander HA. Morphology of interdental gingival tissues. *Oral Surg Oral Med Oral Pathol* 1961;60:287-95.
11. Matherson DG, Zander HA. Evaluation of osseous surgery in monkeys. *J Dent Res* 1963;42 (Spec. Issue) 116(Abstr. 326).
12. Tarnow DP, Magner AW, Fletcher P. The effect of the distance from the contact point to the crest of bone on the presence or absence of the interproximal dental papilla. *J Periodontol* 1992;63:995-96.

**How to cite this article:** Tyagi S, Dhaiya DR, Mehra P, Issar G. Immediate implant placement in the esthetic zone – a clinical report. *J Dent Specialities* 2016;4(1):95-98.

**Source of Support:** NIL

**Conflict of Interest:** All authors report no conflict of interest related to this study.