

A study of efficacy of platelet rich plasma in treatment of androgenetic alopecia in male patients

Krishnendra Varma¹, Ankit Agrawal^{2,*}, Meetesh Agrawal³

¹Professor & HOD, ²PG Student, ³Professor, RD Gardi Medical College, Ujjain

***Corresponding Author:**

Email: ankitrdgmc@gmail.com

Abstract

Background: Androgenetic alopecia is a very common clinical condition encountered by the dermatologists in their daily practice.

Aims: To study the efficacy of platelet rich plasma in treatment of androgenetic alopecia in male patients.

Settings and design: Observational and interventional study.

Methods: A total of 30 cases of clinically diagnosed male patients with androgenetic alopecia in the age group of 15-50 years constituted the subject material for present study. Detailed history and clinical examination of cases was done. All the routine investigations were carried out.

Statistical analysis used: Data analysis was done by using statistical package for social sciences (SPSS) and "paired t test".

Results: A total of 30 patients were studied. Large number belonged to the age group 26-30(36.7%) years and 21-25 years(33.3) respectively. Majority are from class 2 to 5, Hamilton Norwood classification of AGA. The family history was positive in 19 cases (63.3%). Frontal, parietal and occipital areas were involved in maximum number of patients i.e. in 20 patients (66.7%). The patients reported clinical improvement in the form of hair count, hair thickness, hair density with statistically significant p-value (p-0.00) after an average of 2-3 sessions.

Conclusion: In our study of 30 patients, 20 patients showed improvement of varying degrees ranging from +1 to +7 according to Jaeschke scale with significant p-value (p-0.00) after treatment with platelet rich plasma (PRP) based upon which we conclude that platelet rich plasma (PRP) is efficacious in the treatment of androgenetic alopecia.

Key-words: Androgenetic alopecia (AGA), Platelet rich plasma (PRP), Males

Introduction

Androgenetic alopecia (AGA) in males is progressive patterned hair loss in which there occurs androgen mediated conversion of susceptible terminal hairs into vellus hairs^[1]. It occurs due to transforming growth factor- β (TGF- β), an inhibitory factor secreted by hair follicles, while the androgen levels are comparable to those of non-balding males^[1,2,3]. The prevalence and severity of male baldness increases with age. The prevalence of AGA is approximately 93.5% in men above 20 years of age. The main effect of AGA is psychological^[1].

AGA is a genetically determined process like aging and hence cannot be cured but can only be slowed down. The goal of treatment is to prevent further hair thinning and to increase the coverage of the scalp by reversing the miniaturization process. Conventional therapies for AGA include finasteride and topical minoxidil for mild to moderate AGA and hair transplantation for severe AGA.

The conventional therapies for the treatment of AGA have not been found to be effective. Hair restoration surgery is a very tedious procedure. Therefore attempt is being made to carry out this study to establish the efficacy of platelet rich plasma in the treatment of androgenetic alopecia as it is an easy, safe

and inexpensive modality. Platelet Rich Plasma is being widely used in a number of medical and surgical specialities to enhance tissue repair and healing. Its potentiality to promote hair growth in areas containing hair follicles is known since 1900.^[4]

Methods

The present study was an observational and interventional study undertaken to study the efficacy of platelet rich plasma (PRP) in the treatment of androgenetic alopecia in male patients. In this study PRP was given as a monotherapy without any concomitant treatment. A total of 30 cases of clinically diagnosed male patients with androgenetic alopecia constituted the subject material for present study. Detailed history and clinical examination of cases was done. All the routine investigations were carried out. Prior approval for the study and the protocol was obtained from the ethical committee.

The cases were selected on the basis of the following inclusion and exclusion criteria:

Inclusion criteria

- Patients who are willing for the procedure.
- Male patients in age group 15-50 years.
- Patients with androgenetic alopecia of all classes as per Hamilton Norwood classification.

Exclusion criteria

- Patients with alopecia other than androgenetic alopecia, such as alopecia areata, alopecia totalis, telogen effluvium, anagen effluvium, acquired cicatricial alopecia etc.
- Patients with history of bleeding disorders.
- Patients on anti-coagulant medications (aspirin, warfarin, heparin).
- Patients with active infection at the local site.
- Patients with keloidal tendency.
- Patients with history of psoriasis or lichen planus because of risk of Koebner's phenomenon.

Procedure

- Collection of the patient's blood sample.
- Preparation of Platelet Rich Plasma by ultracentrifugation of the blood sample (manual double spin method).
- Activation of the procedure site (scalp) by micro needling technique using a derma-roller with needle length 1.5 mm.
- Application of extracted plasma on the activated site and massaging, to allow it to percolate through the epidermis.

The procedure has been illustrated as a simplified flow chart below:



The molecular mechanism of action of PRP can be explained with the help of the following:

1. There is increased bcl-2 levels which being anti-apoptotic prolongs the survival of dermal papilla cells.
2. Expression of FGF-7 in dermal papilla cells leading to prolongation of anagen phase of hair cycle.
3. Upregulation of transcriptional activity of β -catenin leading to differentiation of stem cells into hair follicle cells.

4. Increased VEGF and PDGF which being pro-angiogenic increases the perifollicular vascular plexus.
5. There occurs activation of AKT and ERK signalling pathways which prolongs the survival of dermal papilla cells.

A total of 6 such sittings will be given to each patient at interval of 3 weeks each, over a total period of 3 months.

Photographs will be taken before and after each sitting with the help of a camera(Canon A800 power shot digital camera). In this way photographs will be taken periodically every 3 weeks for the first 3 months, and then monthly after all the sittings have been completed for another 3 months.

In our study we adopted a macrophotographic protocol. We preferred this to the spot and ultrasound images obtained with software-assisted methods, because techniques such as the trichoscan, although very popular, have been criticized over the last decade. In fact, although relying on such images would have stressed the almost microscopic details of the follicular units emerging on the scalp, this technique would have missed the "wider shot" images that may provide an idea of the "scalp framed as a whole," which we rated as the most relevant aesthetic parameter for a realistic evaluation of any kind of clinical improvement.

The baseline severity of the condition was estimated by the independent evaluator (principal investigator) using a 15-point scale proposed by Jaeschke and colleagues. Because our study was ethically approved as an observational study, our evaluation was necessarily constrained to "before/after" observations. The clinical change between the first assessment and the end of the follow-up was rated by the evaluator using the same 15-point scale used for assessing the baseline severity. The evaluator had to answer the following question: Overall, has there been any change in this patient's condition since the first visit? Please indicate if there has been any change by choosing one of the following options. The answers ranged from -7, corresponding to "A very great deal worse," to +7, corresponding to "A very great deal better," and with 0 corresponding to "About the same." The evaluations were made by an independent observer who was blinded to pre and post-information. We report here the whole Jaeschke scale:

- -7: A very great deal worse.
- -6: A great deal worse.
- -5: A good deal worse.
- -4: Moderately worse.
- -3: Somewhat worse
- -2: A little worse.
- -1: A little worse, hardly any worse at all.
- 0: About the same.
- +1: A little better, hardly any better at all.
- +2: A little better.
- +3: Somewhat better.

- +4: Moderately better.
- +5: A good deal better.
- +6: A great deal better.
- +7: A very great deal better.

“Before treatment score” and “After treatment score” was assigned to each patient by the evaluator according to the Jaeschke scale mentioned above.

Results will be assessed at the end of six months for the extent of re-growth of hair over the procedure area on the basis of:

- Independent observer evaluation of the photographs.

The statistical tools used for the analysis were SPSS-16 version, graphical representation, descriptive statistics and “paired t test”.

Results

A total of 30 male patients of androgenetic alopecia were studied. The age ranged from 15-50 years. Majority of cases were in 26-30 years age group(36.7%), followed by 21-25 years(33.3%), 15-20 & 31-35 years(10% each), 36-40 years(6.7%) and >40

years(3.3%). The family history was positive in 19 cases (63.3%). Frontal, parietal and occipital areas were involved in maximum number of patients i.e. in 20 patients (66.7%). Majority of patients ranged from class 2 to 5 of Hamilton Norwood classification. The patients reported clinical benefit in the form of hair count, hair thickness, hair density after an average of 2-3 sessions. The improvement was maximum in class 2-5 and minimum in class 6-7.

Table 1: Distribution of cases according to Hamilton Norwood classification

Hamilton Norwood classification(Class)	Our study(No of patients)
I.	2
II.	4
III.	9
IV.	6
V.	4
VI.	3
VII.	2
Total	30

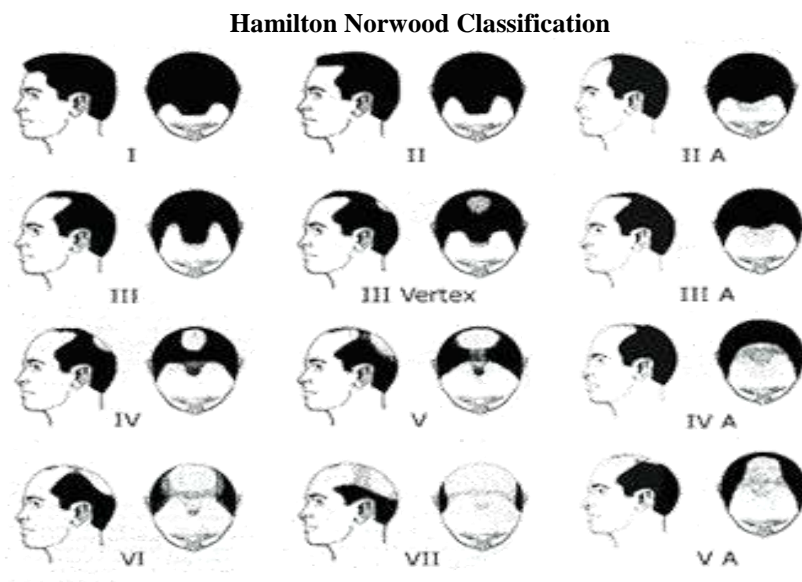


Table 2: Distribution of cases according to site involved

Site	No of patients	Percentage(%)
Frontal, parietal	5	16.7
Frontal, parietal, temporal	1	3.3
Frontal, parietal, temporal, occipital	3	10
Frontal, parietal, Occipital	20	66.7
Parietal, occipital	1	3.3
Total	30	100

Appropriate statistical tool (“paired t test”) was applied and the result was obtained as follows:

Result

		Paired Samples Statistics				
		Mean	N	Std. Deviation	t value	p value
Pair 2	Before treatment score	-3.4667	30	1.56983	7.25	0.000
	After treatment score	1.3000	30	3.79791		

Discussion

Androgenetic alopecia (AGA), common baldness is the result of progressive, patterned hair loss in genetically predisposed individuals exposed to androgens. Whether someone is considered bald or prematurely bald, is a matter of subjective assessment. The process by which common baldness occurs is androgen-mediated conversion of susceptible terminal hairs into vellus hairs. The lack of balding in eunuchs, pseudohermaphrodites and individuals with androgen insensitivity syndrome confirms that androgens are a prerequisite for common baldness. The prevalence and severity of male baldness increases with age.

Platelet Rich Plasma is widely used in a number of medical and surgical specialities to enhance tissue repair and healing. Its potentiality to promote hair growth in areas containing hair follicles is known since 1900. The early clinical evidence and basic science supports the application of Platelet Rich Plasma in hair growth. But the awareness regarding its use in hair growth is limited as the procedure is a recent upcoming procedure.

In our study we found that platelet rich plasma is efficacious in the treatment of androgenetic alopecia, 20 out of 30 cases showed varying degrees of improvement at the end of the treatment as observed by the independent evaluator which was statistically significant ($p=0.00$). A study conducted by **Singhal P, Agarwal S, Dhot PS, Sayal SK**^[5] in 10 patients who were given autologous PRP injections on the affected area showed clinical improvement in form of hair counts, hair thickness, hair root strength and overall alopecia after 3 months treatment. The study carried out by **Khatu SS, More YE, Gokhale NR, Chavhan DC, Bendsure**^[6] showed a significant reduction in hair loss after 3 months of treatment with PRP. It included 11 patients of AGA who were not responding to minoxidil and finasteride. **Schiavone G et al**^[7] studied sixty-four patients. Some improvement was seen in all patients by 1 evaluator and in 62 by the other.

A Study by **Rosa Borhan, Cindy Gasnier and Pascal Reygagne**^[8] reported 14 cases of androgenetic alopecia (AGA) in men treated by autologous platelet rich plasma (PRP). A slight improvement of hair density was observed in 11 cases while 2 cases showed cosmetic improvement according to 3 assessors. **Gkini MA et al**^[9] studied 20 patients (18 men, 2 women). In their study hair loss was reduced and at 3 months it reached normal levels. Hair density reached a peak at 3 months. At 6 months and at 1 year, it was significantly increased compared to baseline. Patients were satisfied

with a mean result rating of 7.1 on a scale of 1-10. No remarkable adverse effects were noted.

The possible limitations of our study are:

- We have adopted a macrophotographic method instead of the trichoscan.
- The follow-up period has to be extended, to verify whether the improvement observed at an interval of 6 months after the intervention may be maintained over time.
- Both measures used to assess the clinical severity and the possible improvement at follow-up, are subjective and so are exposed to some extent to the bias of the investigator.
- Significant pain and headache were the two side effects observed in the patients.

It is important to determine the frequency and the number of sessions not only based on half-life of platelets but also up to patient's background. The role of age, AGA staging and correlation with androgenic activity may be considered. These factors could interfere with PRP efficiency. For example, in a young subject, the regenerative capacity and androgenic activity is equally high. These two factors can thwart variously and alter PRP efficacy. On the other hand AGA staging and disease progress are important. PRP seems to be less effective in late AGA and/or rapidly progressing AGA.

Patient compliance is not always very good with minoxidil, because of cosmetic effects and long term use. Finasteride has raised concerns for some patients regarding its sexual side effects (decreased libido, hypofertility). PRP as an autologous and non-chemical treatment is better accepted by patients who wish to avoid these disadvantages. Consequently for non-responders to these therapies, PRP can be an alternative. As the mechanism of action of PRP is different from the two other treatments, we may have an additional positive effect by using PRP in responders to minoxidil and finasteride. In terms of costs, PRP may be more cost effective in long term than conventional therapies.

Unlike the conventional treatments of AGA, our approach does not require long term therapy or high degree of compliance with no potential side effects.

For optimum results select the following responders:

- Young subjects (less than 40- year-old).
- Early staging (stage III to V).
- Recent AGA (less than 4 years of progress).

References

1. Sinclair RD, Burns T, Breathnach S, Cox N, Griffiths C. Disorders of Hair. In: Burns T, Breathnach S, Cox N, Griffiths C, editors. Rook's Textbook of Dermatology. 8th edition. UK: Blackwell Publishing Ltd; 2010:66.16-66.31.
2. Wadhwa SL, Khopkar U, Nischal KC, Valia RG, Valia AR. Hair and Scalp Disorders. In: Valia RG, Valia AR, editors. IADVL Textbook of Dermatology. 3rd edition. India: Bhalani Publishing House; 2008:887-894.
3. Paus R, Oslen EA, Messenger AG, Wolff K, Goldsmith LA, Katz SI, Gilchrist BA, Paller AS, Leffell DJ. In: Wolff K, Goldsmith LA, Katz SI, Gilchrist BA, Paller AS, Leffell DJ, editors. Fitzpatrick's Dermatology in General Medicine. 7th edition. USA: The McGraw-Hill Companies, Inc; 2008:766-769.
4. Knighton DR, Hudson, Wis inventors. Regents of the University of Minnesota, Minneapolis, Minn, Curative Technologies. Method for Promoting Hair Growth. 1990 (September 18). US Patent 4957742.
5. Singhal P, Agarwal S, Dhot PS, Sayal SK Asian J transfus Sci 2015 jul-dec,9(2):15962.doi:10.4103/0973-6247.162713 PMID:26420936.
6. Khatu SS, More YE, Gokhale NR, Chavhan DC, Bendsure J cutan aesthet surg.2014 apr,(7):107-10.doi:10.4103/0974-2077.138352.PMID:-25136212.
7. Giovanni Schiavone, Desanka Raskovic, Joseph Greco and Damiano Abeni © 2014 by the American Society for Dermatologic Surgery, Inc. Published by Lippincott Williams & Wilkins. ISSN: 1076-0512. Dermatol Surg 2014;40:1010-1019. DOI: 10.1097/01.DSS.0000452629.76339.2b.
8. Borhan R, Gasnier C, Reygagne P (2015) Autologous Platelet Rich Plasma as a Treatment of Male Androgenetic Alopecia: Study of 14 Cases. J Clin Exp Dermatol Res 6:292. doi:10.4172/2155-9554.10000292.
9. Gkini MA, Kouskoukis AE, Tripsianis G, Rigopoulos D, Kouskoukis K. Study of platelet-rich plasma injections in the treatment of androgenetic alopecia through an one-year period. J Cutan Aesthet Surg 2014;7:213-9.