

Odontogenic Keratocyst associated with impacted maxillary 3rd molar and involving the maxillary antrum: a rarity

Latika Bachani^{1,*}, Ashok Lingappa²

¹PG Student, ²Professor & Head, Bapuji Dental College & Hospital, Karnataka

***Corresponding Author:**

Email: latikabachani@gmail.com

Abstract

Odontogenic keratocyst (OKC) was first introduced by Phillipsen in 1956 to describe keratin containing jaw cysts. This cyst is considered unique because of its aggressive behavior, high recurrence rate, and characteristic histopathologic features. In 2005, the World Health Organization reclassified OKC and named it as "keratocystic odontogenic tumor" (KCOT). It frequently involves the mandibular posterior region and involvement of the posterior maxilla is a rare occurrence. However, when it does, it can easily expand to occupy the entire maxilla. Hence, this article highlights this rarity by reporting a case of OKC associated with impacted right maxillary third molar in the maxillary antrum.

Keywords: Odontogenic Keratocyst; Maxillary Sinus; Impacted maxillary third molar; Keratocystic odontogenic tumor.

Introduction

Tooth development is a result of multiple interactions between the oral epithelium and the underlying mesenchymal tissue. Ectopic teeth arise when these tissue interactions during development are affected by developmental disturbances, iatrogenic activity, or pathological conditions, such as the presence of a tumor or a cyst. Jaw cysts are very common due to the presence of odontogenic epithelium remnants⁽¹⁾. OKC was categorized by the latest WHO classification as a developmental, non-inflammatory odontogenic cyst that arises from cell rests of dental lamina⁽²⁾. Its most common site is in mandible than maxilla; in mandible, the majority of the cysts occur in mandibular ramus and molar area. In maxilla, canine region is the most common location and its occurrence in maxillary antrum involving the impacted maxillary molar is very rare. Radiographically, they appear as well-defined radiolucencies, which can be either unilocular or multilocular. Due to non-specific clinical and radiographic features of maxillary OKCs in the posterior region, they may be confused with other cysts, leading to under-diagnosis and under-treatment, resulting in unnecessary recurrences⁽³⁾. Successful treatment depends on the precise diagnosis, adequate surgical procedure and follow-up.

Case Report

A 18 years old female patient reported to our Department with a chief complaint of pain in her right upper back tooth region since 3 months and discharge from the same site since 2 months (Fig. 1). Pain was insidious in onset, slowly progressing in intensity, mild to moderate in severity, intermittent in nature, throbbing type, aggravates on chewing food and temporary relieved on taking over the counter medications and was non-radiating. She also gave a positive history of heaviness in the maxillary sinus

region on right side while bending her head down. No history of nasal discharge, common cold or fever was given. History of intermittent discharge noted intraorally from that region since 2 months which was bitter in taste. She also complained of foul smell from the mouth. No history of sensitivity or mobility of teeth in that region. No history of paraesthesia or dyesthesia. She has noticed mild swelling extraorally on right side of her mid-facial region since 1 month which was insidious in onset and is slowly progressing in size. No history of any topical application over that region. Her medical history was non-contributory. On general physical examination, she was moderately built and well oriented to time, place and person and showed no signs of pallor, icterus, cyanosis, clubbing and organomegaly and was afebrile.

On local examination, solitary diffuse swelling was noted extraorally over the right side of mid-facial region. The swelling was oval in shape, measuring approx. 3x3cm in size, extending antero-posteriorly from approx. 2cm distal to ala of nose till approx. 4cm anterior to tragus of ear and superior-inferiorly from ala-tragal line till the level of corner of mouth. Skin over the swelling appeared normal in color, surface appeared smooth and the borders were ill-defined. Surrounding skin appeared normal. On palpation, all the inspeactory findings were confirmed. The swelling was soft in consistency, tender on palpation with a mild local rise in temp. The skin over it was pinchable and it was immobile. No paresthesia was present.

Intraorally, the marginal gingiva wrt 14, 15, 16 and 17 appeared pinkish-red in color and slightly enlarged in size with rolled borders. The vestibule in the region of 17 and distal to it appeared obliterated. Creamish-yellow color discharge could be seen from the gingival sulcus of 17. Buccal cortical plate expansion could be seen wrt 17 and distal to it. No palatal expansion seen. On palpation, inspeactory findings were confirmed. The

region was tender on palpation with buccal cortical plate expansion present irt 17 and distal to it with intermittent yielding areas. The teeth 16 and 17 were non-tender on percussion and immobile (Fig. 2).

On the basis of these findings, a provisional diagnosis of Odontogenic cyst involving right posterior maxilla was given. The differentials were listed as Infected Dentigerous cyst wrt missing 18 and Infected Odontogenic keratocyst wrt missing 18.

Pulp vitality testing revealed that teeth 16 and 17 were vital.

Fine needle aspiration cytology in that region revealed a dirty creamy white aspirate of viscous consistency (Fig.3), which had a protein content of 0.573 g/l.

IOPA irt 17 revealed solitary, roughly oval shaped radiolucency measuring approx. 5x3 cm in size seen distal to 17. The radiolucency had irregular borders. It is involving the crown of 18. The internal structure appears homogeneously radiolucent. The roots of 17 appear displaced mesially (Fig. 4).

OPG revealed full complement of permanent dentition with impacted 18 seen in the periapical region of 17 (Fig. 5).

Further CBCT was done to determine the exact location and orientation of the impacted 18 and also to investigate the involvement of maxillary sinus. The coronal sections revealed discontinuity in the anterolateral border of maxillary sinus distal to 16. As the scans were moved posteriorly, there was presence of 18 superior to the roots of 17. Crown of 18 was facing buccally and its roots were attached to the lower third of the medial wall of the sinus. Thinning of walls of sinus was seen laterally and superiorly (Fig. 6). In sagittal sections, 18 was seen to be superiorly placed within the sinus just apical to roots of 17 surrounded by mesodens area filling the sinus with Hounsfield units -300 to -150. Breach in the continuity of sinus wall distal to 17 and thinning of posterior wall of sinus was seen. Follicular space of approx. 1mm was seen surrounding 18 (Fig. 7). On axial sections, Impacted 18 was seen attached to medial wall of sinus with thinning of anterolateral, posterolateral and posterior walls of sinus. As the scans were moved down, palatal cortical plate expansion could be seen with complete discontinuity of maxilla distal to 17 (Fig. 8).

Radiographic differential diagnosis was given as Dentigerous cyst wrt impacted 18 and Odontogenic Keratocyst.

Hence the management was enucleation of cystic lesion along with the tooth 18, removal of maxillary sinus lining through curettage followed by primary closure under GA.

Histopathology report revealed multiple sections showing stratified squamous epithelium lining with patchy parakeratosis and few bits showing desquamated lining, dense infiltrate of lymphocytes, histiocytes and neutrophils in the wall.

Hence final diagnosis was given as infected Odontogenic Keratocyst.

7 months later patient reported back with persisting pain and discharge from that region.

The lesion was managed as curettage of the lesion followed by 3 cycles of chemical cauterization by Carnoy's solution under GA.



Fig. 1: Pre-op picture of the patient

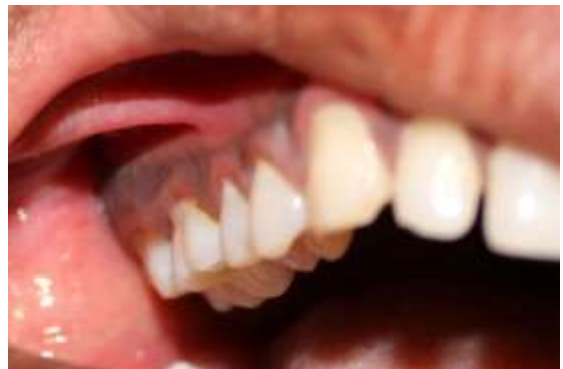

Fig. 2: Intraoral picture irt 17

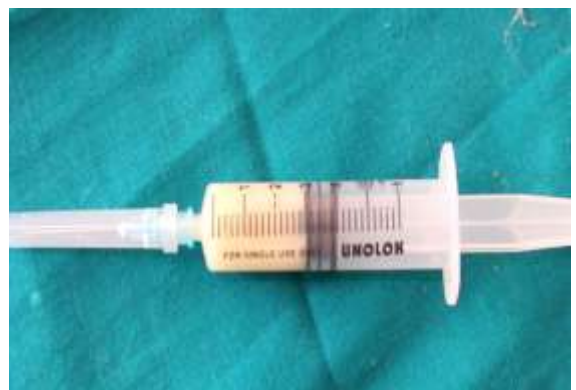

Fig. 3: FNAC aspirate

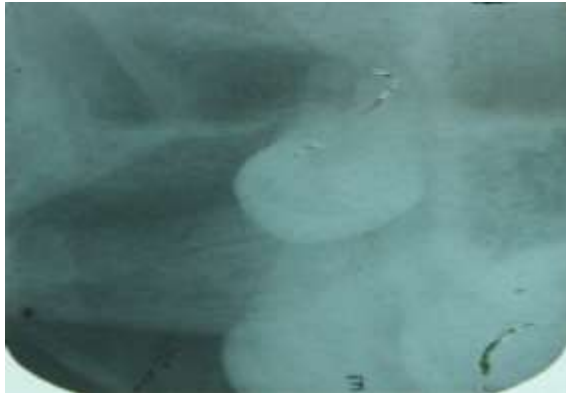


Fig. 4: OPG

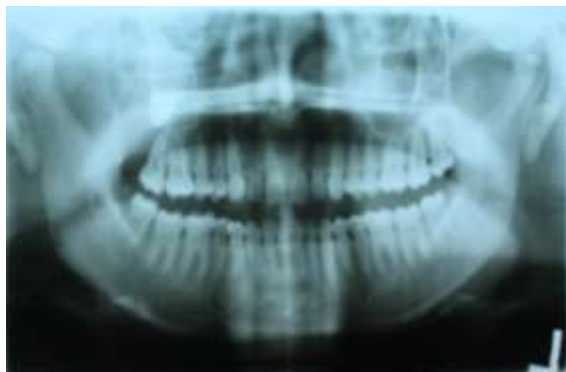

Fig. 5: IOPA irt 17

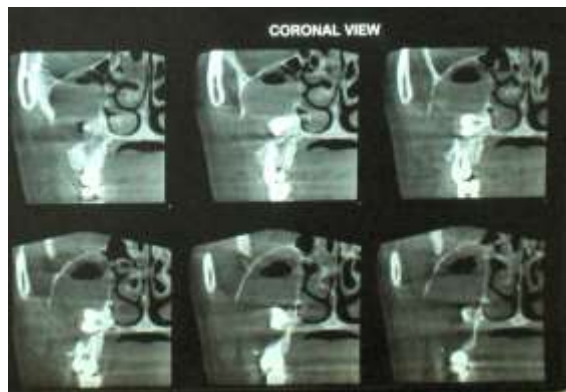


Fig. 6: Coronal view CBCT

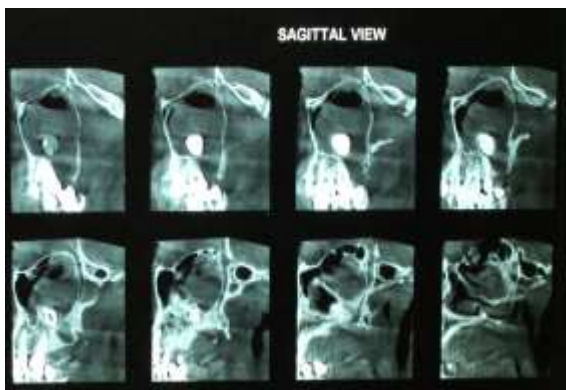


Fig. 7: Sagittal view CBCT

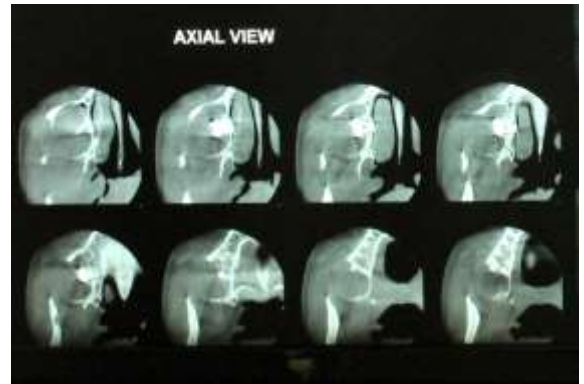


Fig. 8: Axial view CBCT

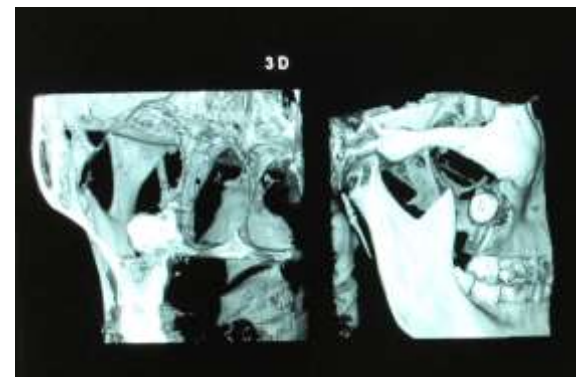


Fig. 9: 3D reconstruction CBCT

Discussion

Cysts of the jaw are a common clinicopathological finding. From the viewpoint of assumed origins, they can be divided into odontogenic and non-odontogenic.

Odontogenic keratocyst, first described by Philipsen in 1956⁽¹⁾ and later designated by the World Health Organization as Keratocystic odontogenic tumor (KCOT)⁽²⁾, is a benign uni- or multicystic intraosseous tumor of odontogenic origin, with a characteristic lining of parakeratinized squamous epithelium^(3,4). They are an independent clinical entity with a typical microscopic picture, clinical growth and biological behavior⁽⁵⁾. They arise from proliferation of the epithelial dental lamina of the upper and lower jaw⁽³⁾.

It shows bimodal age distribution with additional peak in the fifth and sixth decades of life. Many studies have shown a male preponderance by ratio of 1.6:1/1.3:1. Majority of OKCs are found in the lower jaw most commonly in the posterior body, angle and ramus of the mandible and in the maxilla in the area of the third molar⁽²⁾. As per the literature, less than 1% of all cases of OKC occur in the maxilla with the involvement of the maxillary sinus⁽⁶⁾. In these cases, the OKC's are found to be primarily developing from the maxillary bone and then extending to involve the maxillary sinus. Six such cases have been reported with KCOT in maxillary antrum⁽⁷⁾.

Clinically, OKCs generally present with swelling, pain, discharge, aggressive growth, invasion of adjacent

structures and recurrence. A localized asymptomatic swelling is the most common symptom, spontaneous drainage into the oral cavity and mobility of teeth are also common. Nasal erosion, paraesthesia, root resorption are rare symptoms⁽³⁾.

Growth is chiefly in the anteroposterior dimension and the lesions may attain remarkable size without significantly deforming the jaw skeleton⁽⁴⁾. The particular tendency to rapid growth is due to higher activity of the epithelial cells of the cyst lining stimulating osteolytic activity of prostaglandin substances in the cell population of the cyst lining and higher accumulation of hyperkeratotic scales in the lumen of the cyst with resulting greater difference in hydrostatic pressure⁽⁵⁾.

The histopathological picture of OKCs/KCOTs is a characteristic thin epithelial layer, composed of 8 to 10 cell layers. The basal layer shows palisaded organized cells with a uniform nucleus. In the direction of the cyst lumen there is parakeratosis with a focal zone created of orthokeratins. The lumen is frequently filled with a foul smelling cheese-like material that is not pus but rather collected degenerating keratin⁽⁴⁾. Sometimes there is invasion of the basal cell layer into the region of surrounding connective tissue and the formation of satellite microcysts. The fibrous walls of the cells may be relative thin and usually without inflammatory cell infiltrates. In addition to the parakeratotic type of OKC, also described is an orthokeratinised type with a prominent granular layer lying immediately under the thin surface layer. The frequent occurrence of microscopic satellite cysts connected to fragile relatively thin vacuoles is considered the main cause of the high tendency to postsurgical recurrence (10-60%). The tendency to recurrence is particularly high in patients with multiple lesions⁽⁸⁾.

The ectopic eruption of teeth in regions other than the oral cavity is rare. One of the non-dental sites in which an ectopic tooth has been observed is the maxillary sinus. The etiology of ectopic eruption has not yet been completely clarified, but many possible etiologies have been suggested. They include trauma, infection, developmental anomalies, and pathological conditions, such as odontogenic cysts. With regard to the latter, it is known that, as the growth of an odontogenic cyst continues, the cyst encroaches on the space of the sinus and displaces its borders: it may be that the displacement of teeth buds by this expansion of a cyst results in the "ectopic" eruption of a tooth⁽⁹⁾.

A range of studies is currently focused on identifying markers that could predict the biological behavior of these lesions and clarify the mechanisms leading to frequent postoperative recurrence. The significance of immunohistochemical analysis of epithelial cell markers was handled extensively by Shear⁽⁸⁾. In general, he suggested that several cytokeratins but above all cytokeratin10, could be a valuable marker for differentiating odontogenic cysts. It

is possible that syndromic OKC has a different phenotype to sporadic OKC which is characterised by higher expression of Bcl-2, p27Kipl and C-erbB-2 (in non-specific odontogenic cysts also p53), lower proliferation in basal cell layers and much higher proliferation in suprabasal layers. Sporadic OKC shows only some of these characteristics, which may be used to advantage for more precise differential diagnosis between the two types⁽¹⁰⁾.

Radiographically, KCOT appears as well defined radiolucency that may be unilocular or multilocular. KCOTs are poor bone resorbers and hence involve the cancellous bone in early stages of its development. The compact bone is invaded much later; therefore very little expansion is observed in keratocyst⁽¹¹⁾. Cystic lesion that has been reported for long periods of time showed scalloped margins due to the regional resorption of the surrounding bone. Routine radiography is sometime inadequate in most cases to determine the site & size of OKC. However, advanced imaging techniques like CT & MRI can be beneficial in large and complicated OKCs involving maxillary sinus and more rarely, when it involves the base of skull. MR imaging of these lesions is performed infrequently and has not been reported. Hence, CT and conventional radiographs had been the mainstay in imaging of these lesions. But conventional CT protocols are associated with relatively high radiation dose levels, hence alternative imaging modality, CBCT can be used which would allow lowering the effective radiation dose for the patient, without significant loss of image quality. Moreover, it is of great help in localization of pathologies, association of pathology with the surrounding structures, evaluation of the extent of cortical destruction, and in assessing the soft tissue involvement. They also provide accurate picture of spatial relationship of the impacted tooth with the lesion⁽¹²⁾.

In conclusion, OKCs are relatively rare in the maxillary sinus. It is suggested that if clinical signs and symptoms are absent, the radiological appearance on conventional images may be misinterpreted. Therefore, advanced imaging like CBCT or CT is important in assessing the full extent of the lesion and a definitive diagnosis must be made histologically. Post-operative follow-up is essential for atleast five years following surgery.

References

1. Philipsen HP. OM Keratocyster (Kolestent-Tomer). 1 Kaerberne. Tandialgeblad 1956;60:963 [in Danish].
2. Philipsen HP. In: Barnes L, Eveson JW, Reichart P, et al, editors. World Health Organization classification of tumours. Pathology and genetics of head and neck tumours. Lyon (France): IARC; 2005. p. 306-7.
3. Browne RM. The odontogenic keratocyst. Clinical aspects. Br Dent J 1970;128:225.
4. Browne RM. The odontogenic keratocyst. Histological features and their correlation with clinical behaviour. Br

- Dent J 1971;131:249.
5. Kaplan I, Hirshberg A. The correlation between epithelial cell proliferation and inflammation in odontogenic keratocyst. *Oral Oncol* 2004;40(10):985–91.
 6. Lund VJ. Odontogenic keratocyst of the maxilla: A case report. *Br J Oral Maxillofac Surg* 1985;23:210-5.
 7. Cakur B, Miloglu O, Yolcu U, Goregen M, Gursan N. Keratocystic odontogenic tumor invading the right maxillary sinus: A case report. *J Oral Sci* 2008;50:345-9.
 8. Shear M. *Cysts of the Oral and Maxillofacial Regions*. 4th edition. Blackwell Munksgaard publication. 2007.
 9. White SC, Pharoah MJ, O'Connor D. *Oral radiology: principles and interpretation*. 5th ed. St. Louis: Mosby, 2004.
 10. Shear M. The aggressive nature of the odontogenic keratocyst: Is it a benign cystic neoplasm? Part 3. Immunocytochemistry of cytokeratin and other epithelial cell markers. *Oral Oncol* 2002;38(5):407-15.
 11. Nartery NO, Saini T, Abomr D. Odontogenic keratocyst radiographic features. *Saudi Dent J* 1990;2:15-20.
 12. Sudhakar S. et al. A CBCT report & review emphasizing the characteristics of Orthokeratinized odontogenic cyst. *IOSR Journal of Dental and Medical Sciences*.2015(Sep),14;9:97-101.