

Clinicopathological Presentation of Peripheral Ossifying Fibroma with Surgical Management

Debarati Bhowmick¹, Arpita Kabiraj^{2,*}, Tanya Khaitan³, Kushal Chatterjee⁴

¹Senior Lecturer, Dept. of Periodontology & Implantology, ²Senior Lecturer, Dept. of Oral Pathology & Microbiology, ³Senior Lecturer, Dept. of Oral Medicine & Radiology, Haldia Institute of Dental Sciences and Research, Haldia West Bengal, ⁴Assistant Professor, Dept. of Dentistry, Jawaharlal Nehru Medical College & Hospital

***Corresponding Author:**

Email: arpita.kabiraj82@gmail.com

Abstract

Peripheral ossifying fibroma (POF) is a slow growing asymptomatic benign tumor which may induce facial asymmetry. It is an occasional growth of the anterior region of mandible and accounts for 3.1% of all oral tumors and 9.6% of the gingival lesions. About 60% of these tumors occur in maxilla and more than 50% of all cases of maxillary POFs are found in the incisors and canine areas. They are thought to arise from the gingival corium, periosteum or periodontal ligament. Dental calculus, plaque, microorganisms, dental appliances, and restorations are considered to be the irritants triggering the lesion. They can cause separation of the adjacent teeth, resorption of the alveolar crest, esthetic deformity. The treatment of choice is complete surgical excision with the removal of the irritating factors. Care must be taken to preserve or reestablish acceptable gingival architecture and periodontal integrity. Here, we present two cases of peripheral ossifying fibroma in left anterior mandible with complete surgical management.

Key words: Calcifications; Gingival growth; Mandible; Vimentin.

Access this article online	
Quick Response Code:	Website: www.innovativepublication.com
	DOI: 10.5958/2395-6194.2016.00015.1

Introduction

Peripheral ossifying fibroma (POF) is a non-neoplastic enlargement of gingiva that is thought to be reactive in nature. The peripheral variant is seen on the soft tissue over the alveolar bone or gingival and usually occurs in response to low-grade irritations such as trauma, plaque, calculus, microorganisms, masticatory forces, ill-fitting dentures and poor quality restorations.⁽¹⁾ There are several reactive lesions reported on the gingiva, including pyogenic granuloma, peripheral giant cell granuloma (PGCG), pregnancy tumor, POF and others.^(2,3) POF is an occasional growth of the anterior mandible accounting for 3.1% of all oral tumors and 9.6% of the gingival lesions. About 60% of these tumors occur in maxilla and more than 50% are found in the incisors and canine areas.^(3,4)

Clinically, they present as sessile or pedunculated, usually ulcerated and erythematous lesion and exhibits similar color to the surrounding gingiva. It affects both the gender but female predilection appears to be more with peak incidence in second and third decade of life. Microscopically, they consists of one or more mineralized tissues, including bone, cementum-like material, or dystrophic calcification within a matrix of

cellular fibroblastic tissue.⁽²⁾ Surgical correction is the treatment of choice although recurrences are common.⁽⁵⁾ Here, we present two unusual clinical and microscopic presentations of peripheral ossifying fibroma with its complete management.

Case Report

Case 1: A 46 year old female reported with a growth in lower right front teeth and gum region since 1 year. The growth was associated with mild pain causing difficulty in occlusion and displacement of teeth. There was no history of any blood and purulent discharge. On examination, a well-defined pale pink growth was seen in lower right lateral incisor and canine region measuring approximately 4x2 cm in size extending labially and lingually causing displacement of teeth. The growth was mild tender, firm in consistency and sessile. Fig. 1

Case 2: A 42 year old female patient reported with a similar growth in the lower left front teeth and gums since one year. There was no history of pain and blood or purulent discharge associated with the growth or any similar growth elsewhere. On examination, a well-defined, reddish-pink colored growth approximately 3.5 cm × 1.5 cm in diameter was seen in between left lower lateral incisor and canine region. The growth extended on both labial and lingual gingiva as well as occlusal surfaces causing displacement of the associated teeth. The growth was non-tender, sessile and firm in consistency. Fig. 2

Based on history and clinical findings, differential diagnosis of fibrosed pyogenic granuloma, irritational

fibroma and peripheral giant cell granuloma (PGCG) were well thought of.

Surgical intervention was planned for both the gingival growths. Routine hematological examination showed all parameters to be within normal limits. Patient's consents were taken for the same. Firstly, full mouth scaling was done to remove the local irritants. The growths were then excised completely using a 15no. and 11no. B.P blade and curettage was done. After suturing with 3-0 black silk suture, periodontal pack was given. The specimens collected were sent for histopathological analysis. Fig. 3 and 4

Microscopic examination revealed a hyperplastic stratified squamous epithelium with thin long rete ridges, Fig. 5a. Dense collagenous connective tissue stroma with numerous spindle shaped fibroblast cells, chronic inflammatory infiltrate and calcified areas Fig. 5b and c. Immunohistochemical analysis showed a considerable positive reaction with vimentin marker Fig. 5d. Therefore, based on the histopathological features, a final diagnosis of peripheral ossifying fibroma was established for both the cases.

The patients were being followed up after 10 days, 1, 3 and 6 months. No recurrence has been noted till date. Fig. 6 and 7

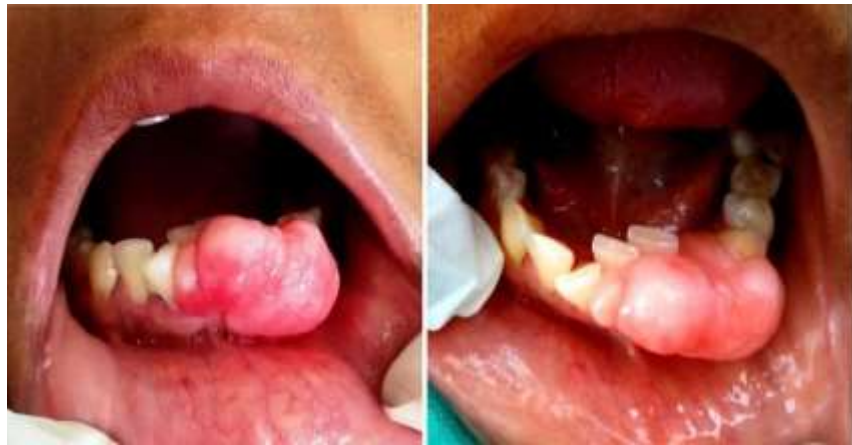

Fig. 1: Clinical presentation of the gingival growth for case 1

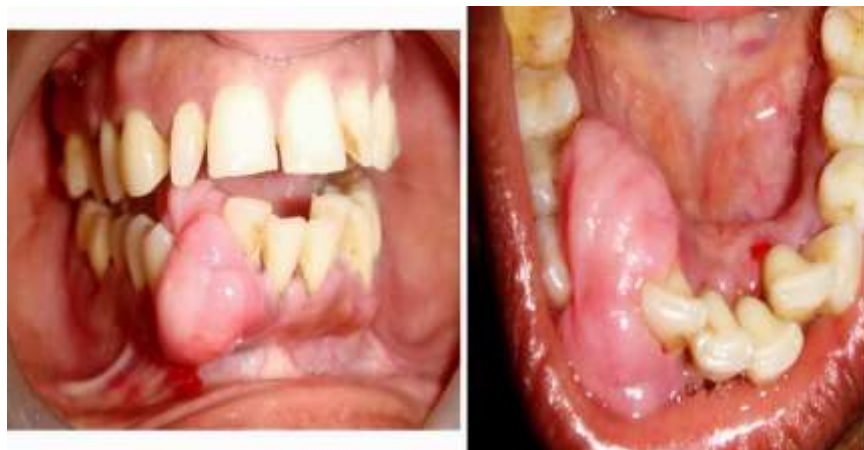

Fig. 2: Clinical presentation of the gingival growth for case 2

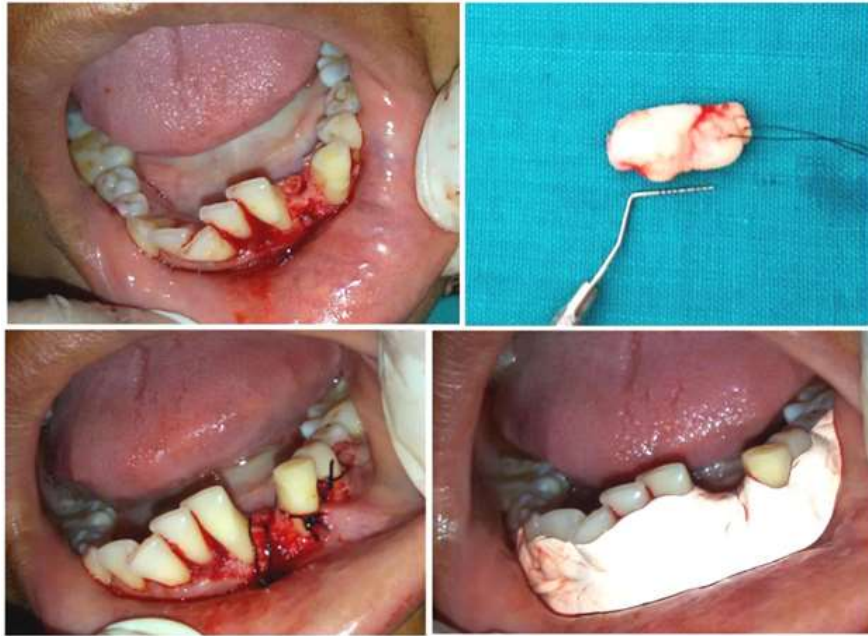


Fig. 3: Surgical procedure with the excised specimen for 1

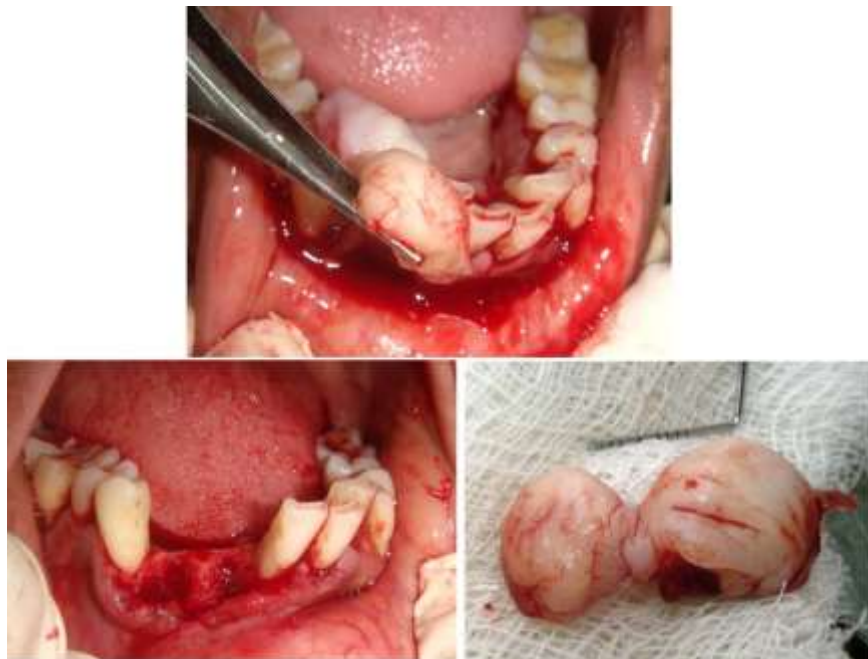


Fig. 4: Surgical procedure with the excised specimen for 2

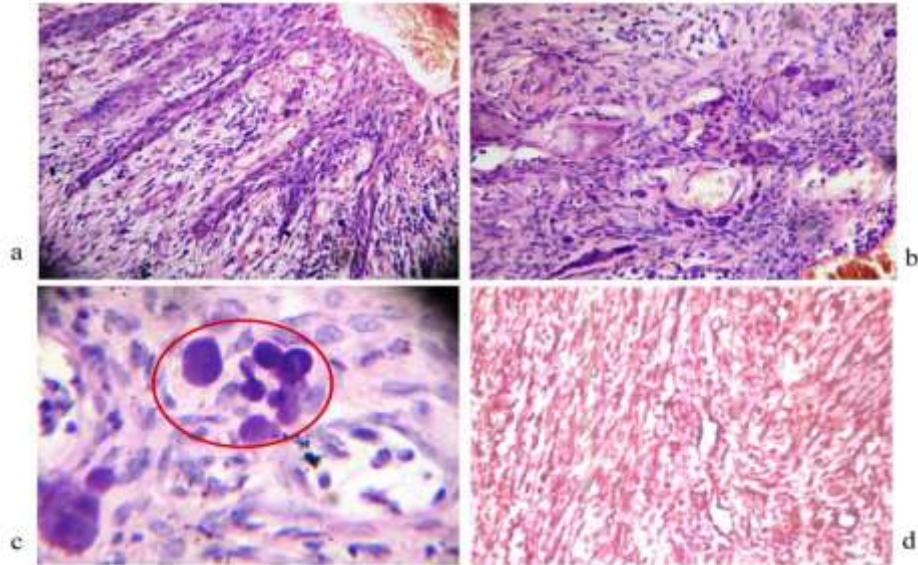


Fig. 5: H & E stained section revealed a hyperplastic stratified squamous epithelium with thin long rete ridges (a) dense collagenous connective tissue stroma with numerous spindle shaped mesenchymal cells, calcified areas (b,c). IHC positivity with reaction with vimentin marker (d)

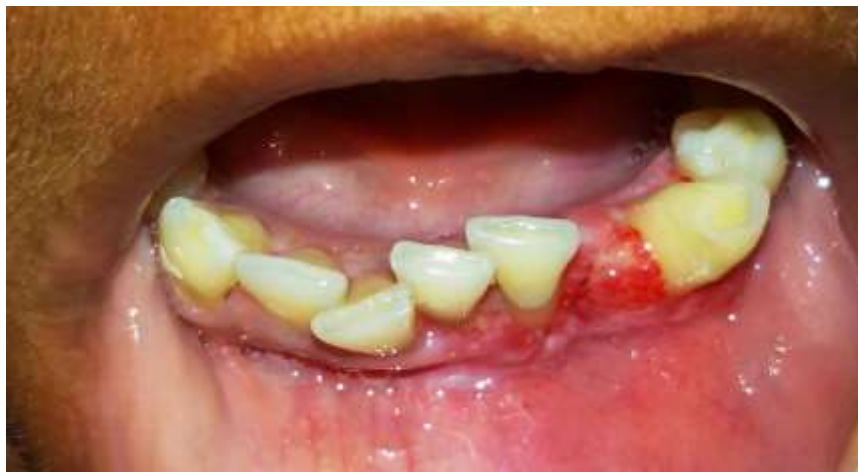

Fig. 6: Postoperative intraoral photograph after periodic follow up for case 1

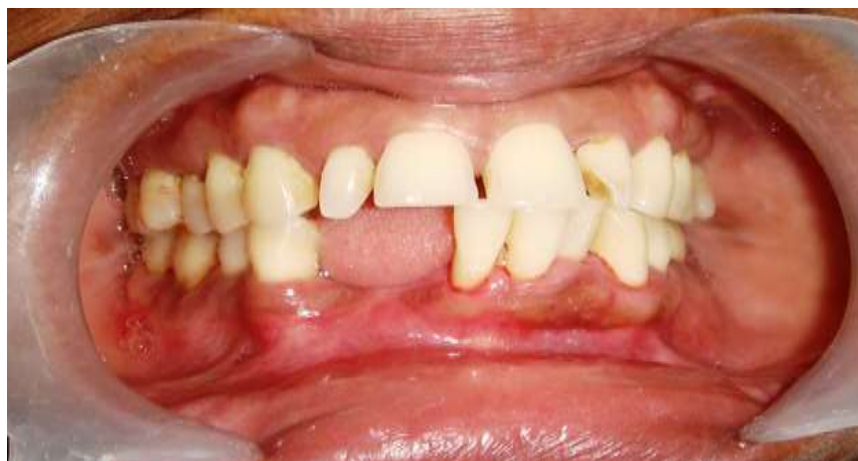

Fig. 7: Postoperative intraoral photograph after periodic follow up for case 2

Discussion

Intraoral ossifying fibromas have been described in the literature since the late 1940s. POF was first described as a relatively uncommon, solitary and non-neoplastic gingival growth by Eversol and Rovin. This entity was first reported as “alveolar exostosis” in 1844 by Shepherd.⁽¹⁾ Many names have been given to similar lesions, such as epulis, peripheral fibroma with calcification,⁽²⁾ peripheral ossifying fibroma,^(3,4) calcifying fibroblastic granuloma,⁽⁶⁾ peripheral cementifying fibroma, peripheral fibroma with cementogenesis⁽⁵⁾ and peripheral cemento-ossifying fibroma. The sheer number of names used for fibroblastic gingival lesions indicates that there is much controversy surrounding the classification of these lesions.^(7,8)

The etiopathogenesis of POF is quite not evident. It has been estimated that these lesions initiate in the cells of the periodontal ligament due to the following reasons: POF exclusively appears in the gingival tissue, close to the periodontal ligament; oxytalan fibers are found within the mineralized matrix of some lesions; the age distribution of the lesions is inversely proportional to the number of permanent teeth lost; and the fibrocellular response of POF is similar to that of other reactive gingival lesions originating in the periodontal ligament.⁽⁹⁾ It has been postulated by Kendrick and Waggoner that exuberant connective tissue response to chronic irritation due to plaque, calculus, restorative or orthodontic appliances are commonly observed in gingiva. Moreover, constant irritation can cause metaplasia of the mesenchymal cells especially fibroblast cells resulting in dystrophic calcifications.⁽¹⁾

When presented clinically with a gingival lesion, it is important to establish a differential diagnosis. In the aforementioned cases, differential diagnosis of irritational fibroma, pyogenic granuloma and PGCG were well thought of. Although it is imperative to maintain a high index of suspicion, discussion with family members should be tactful to prevent undue distress during the waiting period between differential diagnosis and definitive histopathologic diagnosis. It is possible to histopathologically differentiate these gingival growths from POF as the former contain hyperplastic epithelium with dense connective tissue consisting of numerous giant cells, whereas fibroma is characterized by flattened epithelium with loss of rete pegs and highly collagenous and hyalinized connective tissue stroma.^(3,4) Immunohistochemical profile of these gingival growths indicates that the proliferating cells are of a myofibroblastic nature (i.e., cells sharing morphological characteristics with fibroblasts and muscle cells). The most commonly used markers are vimentin, actin, S100, reticulin, etc. which have shown positive reactivity in such lesions. This finding was in accordance with the present case reports wherein vimentin positivity was seen.⁽⁹⁾

Treatment includes local surgical excision and oral prophylaxis with periodic recall. Recurrence is common due to incomplete excision and/or due to persistence of local factors.⁽¹⁰⁾ Care must be taken to preserve or reestablish acceptable gingival architecture and periodontal integrity. Cundiff and Eversole and Rovin have reported 16% and 20% recurrence rate respectively.⁽¹¹⁾

It is evident through literature review that differentiating between most of the reactive gingival lesions clinically, particularly in the early stages is intricate. POF is considered to be one of the commonest solitary gingival growths in the oral cavity that is quite often clinically diagnosed as pyogenic granuloma or fibroma. Hence, every excised tissue should be sent for the histological examination for confirmation of the clinical diagnosis. It is important for all the dental practitioners to have a keen observation, sound clinical acumen and ample knowledge about such gingival growths for better treatment prospective and prognosis of these cases.

References

1. Sujatha G, Sivakumar G, Muruganandhan J, Selvakumar J, Ramasamy M. Peripheral Ossifying Fibroma - Report of a case. *Indian Journal of Multidisciplinary Dentistry* 2012;2(1):415-8.
2. Bhaskar SN, Jacoway JR. Peripheral fibroma and peripheral fibroma with calcification: Report of 376 cases. *J Am Dent Assoc* 1966;73(6):1312-20.
3. Gardner DG. The peripheral odontogenic fibroma: an attempt at clarification. *Oral Surg Oral Med Oral Pathol* 1982;54(1):40-8.
4. Cuisa ZE, Brannon RB. Peripheral ossifying fibroma: A clinical evaluation of 134 pediatric cases. *Pediatr Dent* 2001;23(3):245-8.
5. Bodner L, Dayan D. Growth potential of peripheral ossifying fibroma. *J Clin Periodontol* 1987;14(9):551-4.
6. Lee KW. The fibrous epulis and related lesions. Granuloma pyogenicum, ‘Pregnancy tumor’, fibro-epithelial polyp and calcifying fibroblastic granuloma. A clinico-pathological study. *Periodontics* 1968;6(6):277-92.
7. Kumar SK, Ram S, Jorgensen MG, Shuler CF, Sedghizadeh PP. Multicentric peripheral ossifying fibroma. *J Oral Sci* 2006;48(4):239-43.
8. Zain RB, Fei YJ. Fibrous lesions of the gingiva: a histopathologic analysis of 204 cases. *Oral Surg Oral Med Oral Pathol* 1990;70(4):466-70.
9. García de Marcos JA, García de Marcos MJ, Rodríguez SA, Rodrigo JC, Poblet E. Peripheral ossifying fibroma: a clinical and immunohistochemical study of four cases. *Journal of Oral Science* 2010;52(1):95-9.
10. Farquhar T, MacLellan J, Dymont H, Anderson RD. Peripheral ossifying fibroma: a case report. *Journal of the Canadian Dental Association* 2008;74(9):809-12.
11. Jyothi L, Rao T. Peripheral ossifying fibroma - A case report. *Indian journal of dental research and review* 2012;3:75-7.