

Ectomesenchymal chondromyxoid tumor of the tongue – A rare case report

Anjana Sharma^{1*}, Ravindranath M.², Varsha Pandey³, Tanvir Khan⁴

^{1,3}Assistant Professor, ⁴Resident, CCM Medical College, Durg, ²HOD, Dept. of Pathology, JLN Hospital & Research Centre, Bhilai

***Corresponding Author:**

Email: anj_sh2000@yahoo.co.in

Abstract

Ectomesenchymal chondromyxoid tumor (ECMT) is a rare, benign tumor of oral cavity. So far fewer than fifty cases have been reported in the literature. It occurs in a wide age range but majority arise in the third to sixth decade. It exclusively arises in anterior tongue presenting as asymptomatic nodular lesion with size typically less than 2 cm. We reported a case of 20 years old male presented with a swelling on anterior part of tongue for one year duration. Following examination a presumptive diagnosis of adenoma/ papilloma was made. Histopathology following excision suggested ECMT. The diagnosis was confirmed by immunohistochemistry.

Key words: Benign, Ectomesenchymal chondromyxoid tumor, Tongue

Access this article online	
Quick Response Code:	Website: www.innovativepublication.com
	DOI: 10.5958/2395-6194.2016.00022.9

Introduction

ECMT is a recently described rare benign neoplasm of oral cavity.^[1] It was first described by Smith in 1995 after reviewing 19 cases of chondromyxoid lesions of oral cavity. It characteristically presents as an asymptomatic slow growing nodule in anterior tongue. It follows an indolent clinical course. The age range is wide from childhood to elderly with mean age 39 yrs. and no sex predilection.^[2] The histogenesis of ECMT is uncertain but immunohistochemistry points toward its origin from an undifferentiated mesenchymal cell.^[3]

Case Report

A 20 years old male presented with an asymptomatic, slowly enlarging swelling on anterior tongue for one year. Local examination of oral cavity revealed single, well defined, soft to firm, nontender swelling on anterior dorsum of tongue. The overlying tongue papillae and mucosa were normal. Presumptive diagnosis of adenoma or papilloma was made. Complete Excision was performed. The whole lesion was submitted for histopathological examination. The post operative follow up of patient was uneventful.

Gross Examination revealed single, nodular, well defined soft tissue mass measuring 0.5x0.5x0.3 cm in size. The H&E stained sections showed covering stratified squamous epithelium and underlying tumor [Fig. 1]. On higher magnification the tumor cells were

arranged in sheets and cords [Fig. 2]. At the periphery the tumor was more cellular with round to oval shaped cell with hyperchromatic nuclei and coarse chromatin. [Fig. 3] The tumor also showed areas of low cellularity with oval to stellate shaped cells lying in myxoid stroma. [Fig. 4] The individual tumor cells had scant cytoplasm and show mild pleomorphism. No mitosis or necrosis were seen. Focally chondroid matrix was also appreciated [Fig. 5].

On immunohistochemistry the tumor showed immunoreactivity for S-100 [Fig. 6] and vimentin. The tumor was negative for EMA, monoclonal glial fibrillary acidic protein (GFAP), pancytokeratin and smooth muscle actin [Fig. 7, 8, 9, 10]. Based on these findings a diagnosis of Ectomesenchymal chondromyxoid tumor was made.

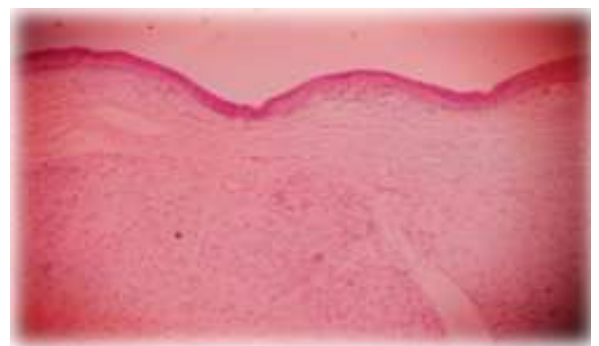


Fig. 1: Photomicrograph showing stratified squamous epithelium and underlying tumor. x100 H&E



Fig. 2: Photomicrograph showing oval tumor cells arranged in sheets and cords x400 H & E

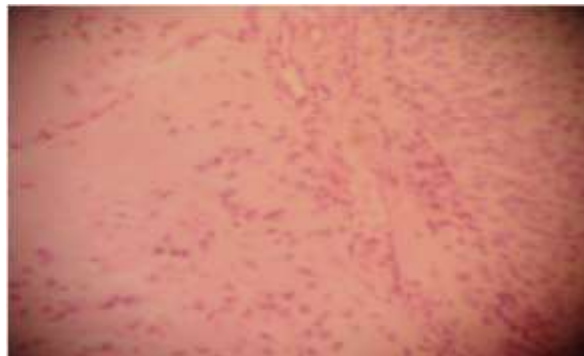


Fig. 5: Photomicrograph showing focally chondroid matrix x 400 H & E

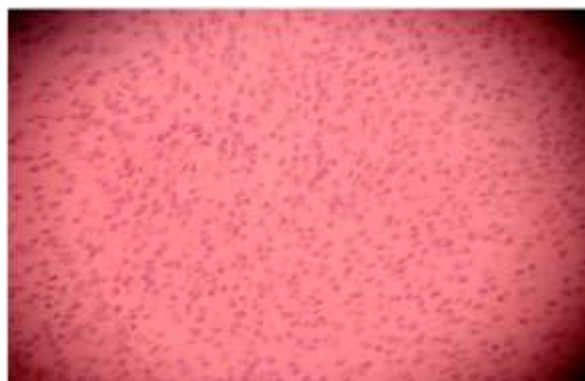


Fig. 3: Photomicrograph showing hyper cellular areas in periphery with no mitosis x400 H & E

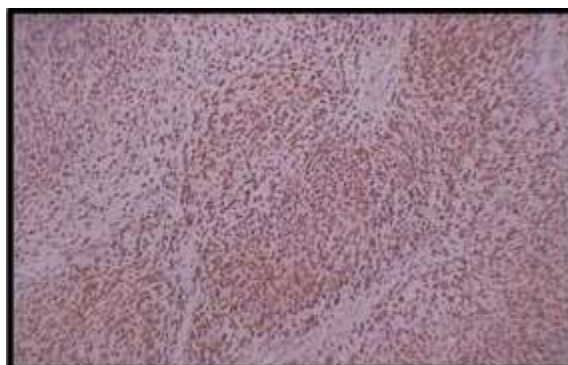


Fig. 6: Photomicrograph showing immunoreactivity for S-100

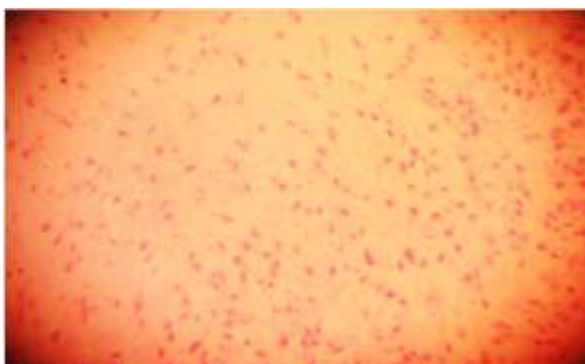


Fig. 4: Photomicrograph showing low cellular areas in myxoid matrix x 400 H & E

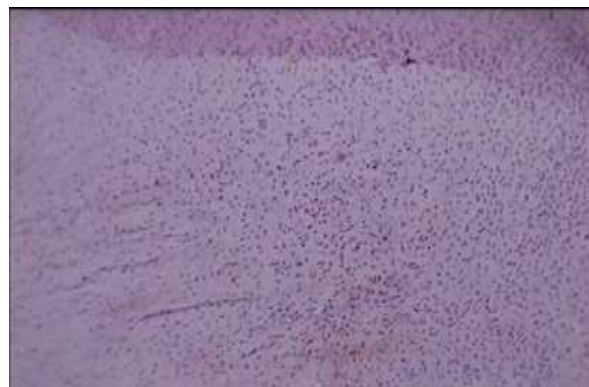


Fig. 7: Photomicrograph showing no immunoreactivity for EMA

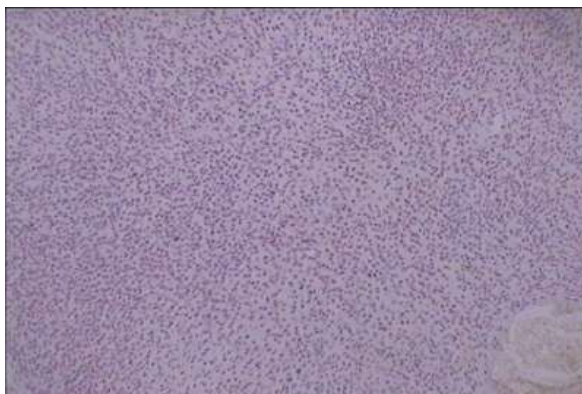


Fig. 8: Photomicrograph showing no immunoreactivity for monoclonal GFAP

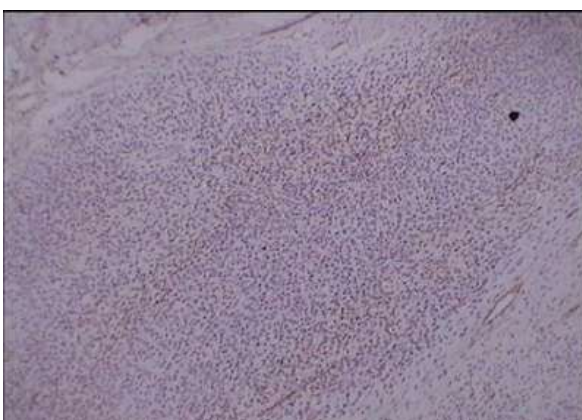

Fig. 9: Photomicrograph showing no immunoreactivity for CK

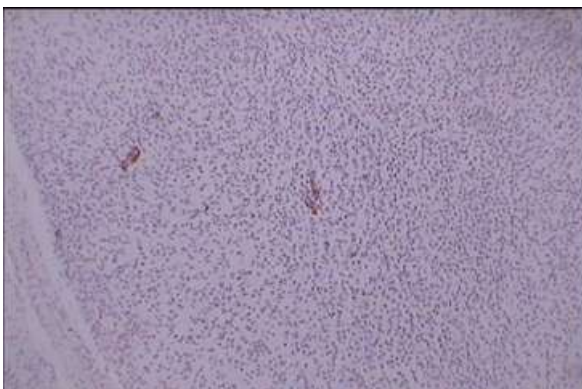


Fig. 10: Photomicrograph showing no immunoreactivity for SMA

Discussion

ECMT is recently described benign and rare neoplasm of oral cavity. Smith et al was first to describe the clinical, morphological and immunohistochemical aspect of the disease in 1995^[4]. Since then only about 48 cases have been reported^[5]. The scarcity of the reports may be accounted by the fact that it resembles closely other chondromyxoid lesions and may be under diagnosed. ECMT occurs commonly in anterior tongue and manifests as well circumscribed

indolent nodule. Only two cases of ECMT in posterior tongue and one case in hard palate is documented.^[1,6,7] The size is typically less than 2cm but larger sized tumor have also been reported. As these are asymptomatic, the tumor may be present for years before coming to clinical attention. There is no sex predilection.^[4] Histopathologically these are characterized by lobular proliferation of tumor cells in a myxoid to chondroid stroma. The cells are arranged in cords, sheets or in nests. The nuclei of tumor cells can be round to oval or spindle shaped. Nuclear pleomorphism and occasional multinucleated cells can be seen but mitotic activity is uncommon.

Focal calcification and muscle entrapment can be a feature but lack of muscle or angioinvasion supports its benign nature.^[8,9] Although ECMT can be diagnosed accurately on morphology, immunohistochemistry act as useful adjuvant tool. ECMT is typically positive for cell markers including GFAP, vimentin and S100. Polyclonal GFAP is more frequently expressed than monoclonal GFAP. The tumor shows variable positivity for cytokeratin, CD 57, SMA, desmin and EMA.^[10] Immunohistochemistry in our case showed positivity for S-100 and vimentin. The tumor was negative for pancytokeratin, smooth muscle actin, monoclonal GFAP and EMA. In the series reported by Smith et al 73% of the tumor were monoclonal anti-GFAP positive. This may be the reason for staining pattern of GFAP in this case. As in our case the monoclonal GFAP was also found to be negative in two other cases reported by Seo SH.^[9] The lesion should be differentiated from other myxoid lesions of oral cavity like myoepithelioma, soft tissue myxoma, neurothekoma, chondroid choriostoma and pleomorphic adenoma. Myoepithelioma is considered as close differential diagnosis and should be distinguished from ECMT.^[10] However myoepithelioma does not occur in anterior portion of tongue and ECMT lacks staining with myoepithelial markers like p63 or calponin and show variable positivity for SMA.^[4] Negative staining for EMA and cytokeratin differentiate it from other epithelial tumors like pleomorphic adenoma. Neurothekeoma shows wavy spindle nucleus in a myxoid background and lacks the chondroid areas as in ECMT and is negative for S-100. Soft tissue myxoma show scant cellularity with spindle cells in a myxoid matrix as compared to ECMT which is cellular. Chondroid choristoma shows mature hyaline cartilage surrounded by connective tissue which is not present in ECMT.^[5]

The histogenesis of ECMT is still speculative and controversial. Various hypothesis based on histogenesis and immunohistochemical staining pattern have been suggested. They point out towards its origin either from an undifferentiated mesenchymal cell that undergo neural differentiation or from the neural crest cells.^[10] The recommended treatment modality for ECMT is

complete excision due to its benign nature and it rarely recurs except in cases of incomplete excision.^[11]

Conclusion

ECMT is a rare and benign tumor of oral cavity found in any age group although majority occurs in middle aged adults. The clinical and histopathological diagnoses are challenging due to varied lesions mimicking the clinical entity. However the tumor has distinct morphological features and unique immunohistochemical profile which differentiates it from other lesions. The tumors show consistent positivity for neural and mesenchymal markers as compared to epithelial and smooth muscle markers. We emphasize here that Ectomesenchymal chondromyxoid tumor of tongue can easily go unrecognized because of its rare frequency, nonspecific symptoms and indolent course and it should always be considered in differential diagnosis of nodular lesions of tongue.

Conflict of Interest: None

References

1. Marie-josee, Pierre Olivier, Anthony G. Zeitouni, Derin Caglar. Ectomesenchymal Chondromyxoid Tumor of posterior Tongue. 2014;8:329-333.
2. Leeky M, Narayan T, Shenoy S, Jamadar S. Ectomesenchymal chondromyxoid tumor: Review of literature and a report of a rare case. J Oral Maxillofac Pathol. 2011 Jan-Apr;15(1):74–79.
3. Goveas N, Ethunandan M, Cowlisha T, Flood TR. Ectomesenchymal chondromyxoid tumor of the anterior tongue: unlikely to originate from myoepithelial cells. Oral Oncol. 2006;42:1026–8.
4. Min Gyoung Pak, Kyung Bin Kim Nari Shin, Woo Kyung Kim Dong Hoon Shin, Kyung Un Choi Mee Young Sol. Ectomesenchymal chondromyxoid tumor of anterior Tongue: Case report of a unique tumor. The Korean journal of Pathology. 2012;46:192-196.
5. A. Aldojain (&), J. Jaradat, K. Summersgill, E. A. Bilodeau. Ectomesenchymal Chondromyxoid Tumor: A Series of Seven Cases and Review of the Literature. Head and Neck Pathol DOI 10.1007/s12105-014-0578-9.
6. Nigam S, Dhingra KK, Gulati A. Ectomesenchymal chondromyxoid tumor of the hard palate—a case report. J Oral Pathol Med. 2006;35:126–8 .
7. Carlos R, Aguirre JM, Pineda V, Ectomesenchymal chondromyxoid tumor of tongue. Med oral.1999;4:361–5.
8. Van der Wal JE, van der Waal I. Ectomesenchymal chondromyxoid tumor of the anterior tongue. Report of a case. J Oral Pathol Med. 1996;25:456–8.
9. Seo SH, Shin DH, Kang HJ, Choi KU, Kim JY, Park DY, et al. Reticulated myxoid tumor of the tongue: 2 case supporting an expanded clinical and immunophenotypic spectrum of Ectomesenchymal chondromyxoid tumor of the tongue. Am J Dermatopathol. 2010;32:660–4.
10. Tsai S, Chang K, Tsai H, DDS YJ. Ectomesenchymal chondromyxoid tumor of tongue. Indian J Pathol Microbiol 2012;55:519-204
11. Allen CM. The ectomesenchymal chondromyxoid tumor: A review. Oral Dis. 2008;14:390–5.