

Acute hemiplegia of childhood, cerebral hypoplasia and homolateral hypertrophy of the skull and sinuses: case report and review

Shyama Choudhary¹, Niranjan Nagaraj^{2,*}, Pramod Kumar Berwal³

^{1,2}Senior Resident, ³Professor & Head, Dept. of Paediatrics, Sardar Patel Medical College Bikaner, Rajasthan

***Corresponding Author:**

Niranjan Nagaraj

Senior Resident, Dept. of Paediatrics, Sardar Patel Medical College Bikaner, Rajasthan

Email: getniranjan806@gmail.com

Abstract

We report the clinical and imaging features in 16 years old girl presented with seizures, right-sided hemiparesis, hemi atrophy of the right side of the body and mental retardation. Brain MRI showed loss of left side cerebral volume with ipsilateral hypertrophy and hyperpneumatization of the paranasal sinuses and mastoid cells, suggestive of congenital type of cerebral hemi atrophy (CH) diagnosis of DDMS was made.

Keywords: Dyke David-doff Masson syndrome, Hemiatrophy, Hemiplegia, Seizure, Bikaner.

Introduction

It was initially described by C G Dyke, L M Davidoff and C B Masson in 1933.⁽¹⁾ Dyke-Davidoff-Masson syndrome (DDMS) refers to atrophy or hypoplasia of one cerebral hemisphere (hemi atrophy). The syndrome results from an insult to the growing brain in utero, or during the early years of life. The insult to the developing brain results in loss of neurons compromising the growth of the brain. Hence, patients suffering from DDMS present with contralateral hemiparesis, seizures, mental retardation, facial asymmetry, learning disability along with radiographic findings of cerebral hemispheric atrophy on one side.^(2,3) It is a relatively rare syndrome, and since 1933 less than 100 cases have been reported. It may present at any age including children, adolescents, and adults. The typical radiological features are cerebral hemi atrophy with ipsilateral compensatory hypertrophy of the skull and sinuses. The syndrome has been documented mainly in adolescents and adults.^(4,6) However, it can also be seen in children.⁽⁷⁾ We present here a 16 year old girl with typical clinical and imaging features of DDMS.

Case report

A 16 years old girl, born full term, to non-consanguineous parents, presented to us with recurrent generalised seizures and weakness of right side of body for past 10 years. As per relatives, all developmental milestones were normally achieved till age of 6 years. She had first episode of seizures at the age of 6 years which was generalised tonic clonic type, lasting for 10-15 minutes with uprolling of eyeballs, clinching of teeth and frothing from mouth but without urine and bowel

incontinence. After 15 days she had second similar episode and then recurrent seizures were there every 10-15 days. Weakness of right side of body started after first episode of seizure and evolved into complete hemiplegia over a period of 3 months. No significant change in speech was noticed. She was treated with anticonvulsant medication which was satisfactory at first but even after good compliance, seizures eventually recurred and frequency increased over time, recently ranging from once every 4-5 days to 10-15 episodes per day.

Physical examination revealed right sided spastic hemiplegia with decorticate posture of limbs, tendon contractures on right side limiting movement of joints, brisk deep tendon reflexes and extensor planter response on right side, circumduction gait, obliteration of left nasolabial fold, deviation of angle of mouth to right side while speaking or smiling. She was mentally alert and had no significant mental retardation. Speech was largely preserved. Vision, hearing and other systemic examination were normal.

MRI of the brain (Fig. 1) revealed hemiatrophy of left fronto-parieto-occipito region with prominent sulci and ex-vacuo dilatation of left lateral ventricle. Left frontal sinus was markedly enlarged. Mild midline shift of 6mm towards the left was seen. From the above findings, a diagnosis of DDMS was made. There was atrophy of bilateral cerebellar hemisphere with prominent foliate pattern, likely due to anti-epileptic intake. She was started on oral valproate and phenytoin. She responded well to the drug followed by sessions of physiotherapy. Frequency of seizures was decreased for next 3 months but was unfortunately lost to follow-up.

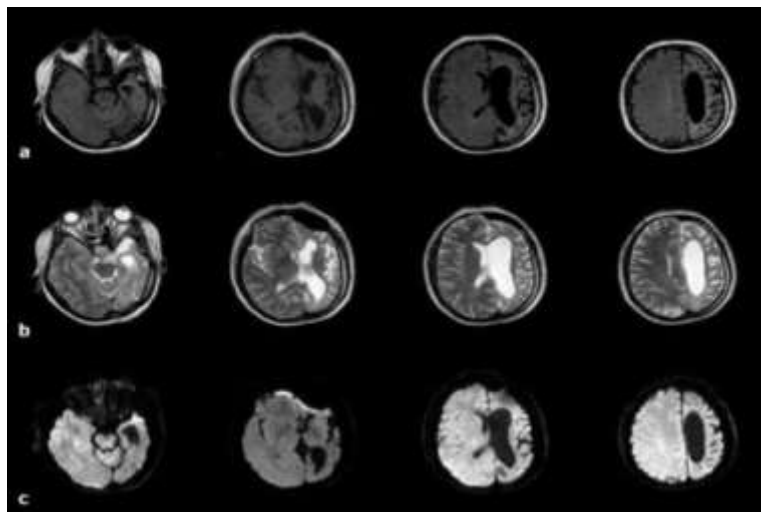


Fig. 1: Axial FLAIR (a) T2 weighted images (b) and diffusion weighted images (c) confirm CT findings

Discussion

In 1933, Dyke, Davidoff and Masson first described the syndrome in plain radiographic and pneumoencephalographic changes in a series of nine patients.⁽⁸⁾ It is characterized by asymmetry of cerebral hemispheric growth with atrophy or hypoplasia of one side and midline shift, ipsilateral osseous hypertrophy with hyperpneumatization of sinuses mainly frontal and mastoid air cells with contralateral paresis.⁽⁹⁾ Other features are enlargement of ipsilateral sulci, dilatation of ipsilateral ventricle and cisternal space, decrease in size of ipsilateral cranial fossa, and unilateral thickening of skull. Clinical presentations include variable degree of facial asymmetry, seizures, contralateral hemiparesis, mental retardation, learning disabilities, impaired speech etc. Seizures can be focal or generalized. Complex partial seizure with secondary generalization also had been reported.⁽¹⁰⁾ Both sexes and any of the hemisphere may be affected, but male gender and left side involvement are more common.⁽¹¹⁾ Mental retardation may not present or appear years after the onset of hemiparesis⁽¹²⁾. As Jules Cotard firstly recorded that unilateral cerebral atrophy in infancy does not necessarily lead to aphasia⁽¹³⁾, DDMS patient not necessarily be aphasic.

Although the nature and extent of the underlying pathologic processes vary widely, adaptation to unilateral decrease of brain substance may consist calvarial thickening affecting particularly the diploic space with loss of convolutional markings of the inner table of the skull^(8,12), overdevelopment of the frontal and ethmoid sinuses and of the mastoid air cells, elevation of the petrous ridge, dilatation of one lateral ventricle and displacement of the midline structures toward the atrophic side and widened subarachnoid space on the affected side.

Cerebral hemiatrophy can be of two types, infantile (congenital) and acquired.⁽¹⁵⁾ The infantile variety results from various etiologies such as infections,

neonatal or gestational vascular occlusion involving the middle cerebral artery, unilateral cerebral arterial circulation anomalies, and coarctation of the aortic arch.^(14,15) The patient becomes symptomatic in the perinatal period or infancy. The main causes of acquired type are trauma, tumor, infection, ischemia, hemorrhage, and prolonged febrile seizure. Age of presentation depends on time of insult and characteristic changes may be seen only in adolescence or adult. Typical skull changes develop when insult to the brain occurs during the first 18 months to 2 years of life.

A proper history, thorough clinical examination, and radiologic findings provide the correct diagnosis. Conditions that are associated with cerebral hemiatrophy such as Rasmussen encephalitis, Sturge-Weber syndrome, some brain tumors, Silver-Russell syndrome, linear nevus sebaceous syndrome and progressive multifocal leukoencephalopathy should be differentiated.^(12,16) Cerebral hemiatrophy without seizure most likely cause is due to cerebrovascular disease⁽¹⁷⁾. Medically intractable patients are the candidates for the surgical treatment in an attempt to achieve better seizure control.

Patients with DDMS usually present with refractory seizures and the treatment should focus on control of the seizures with suitable anticonvulsants. Sometimes multiple anticonvulsants are in use. Along with drugs, physiotherapy, occupational therapy, and speech therapy play a significant role in long-term management of the child. Prognosis is better if the onset of hemiparesis is after 2 years of age and in absence of prolonged or recurrent seizure.⁽⁹⁾ Hemispherectomy is the treatment of choice for children with intractable disabling seizures and hemiplegia with a success rate of 85% in selected cases.⁽⁷⁾ Functional evaluation by fMRI, PET should be performed while planning the surgery. If hemispherectomy is not available, the treatment should focus on optimum control of seizures,

revision of drug doses from time to time, and domiciliary physiotherapy.

References

1. Sharma S, Goyal I, Negi A, Sood RG, Jhobta A, Surya M. Dyke-Davidoff-Masson Syndrome. *Ind J Radiol Imag.* 2006;16:165–6.
2. Ono K, Komai K, Ikeda T. Dyke-Davidoff-Masson Syndrome manifested by seizure in late childhood: A case report. *J ClinNeurosci.* 2003;10:367–71.
3. Amann B, Garcia de la Iglesia C, Mckenna P, Pomarol-Clotel E, Sanchez-Guerra M, Orth M. Treatment-refractory Schizoaffective disorder in a patient with Dyke-Davidoff Masson Syndrome. *CNS Spectr.* 2009;14:36–9.
4. Singh P, Saggar K, Ahluwalia A. Dyke-Davidoff-Masson Syndrome: Classical imaging findings. *J Pediatr Neurosci.* 2010;5:124–5.
5. Koshy B, Surendrababu NR. Dyke-Davidoff-Masson Syndrome. *Ann Acad Med Singapore.*2010;39:501–2.
6. Shetty DS, Lakhkar BN, John JR. Dyke-Davidoff-Masson Syndrome. *Neurolindia.* 2003;51:136.
7. Narain NP, Kumar R, Narain B. Dyke-Davidoff-Masson Syndrome. *Indian Pediatr.* 2008;45:927–8.[PubMed]
8. Dyke CG, Davidoff LM, Masson CB. Cerebral hemiatrophy and homolateral hypertrophy of the skull and sinuses. *Surg Gynecol Obstet.* 1933;57:588–600.
9. Pendse NA, Bapna P, Menghani V, Diwan A. Dyke-Davidoff-Masson Syndrome. *Indian JPediatr.*2004;71:943.
10. Hsin YL, Chuang MF, Shen TW, Harnod T. Temporo-spatial analysis define epileptogenic and functional zone in a case of DDMS. *Seizure.* 2011;20:713–716.
11. Unal O, Tombul T, Cirak B, Anlar O, Incesu L, Kayan M. Left hemisphere and male sex dominance of cerebral hemiatrophy (DDMS). *Clin Imaging.* 2004;28:163–5.
12. Zilkha A. CT of Cerebral hemiatrophy. *Am J Roentgenol.* 1980;135:259–62.
13. Pearn J, Gardner-Thrope C: Jules Cotard (1840–1889): His life and the unique syndrome which bears his name. *Neurology* 2002;58:1400-1403.
14. Sener RN, Jinkins JR. MR of craniocerebral hemiatrophy. *Clin Imaging* 1992;16:93–7.
15. Stred SE, Byrum CJ, Bove EL, Oliphant M. Coarctation of midaortic arch presenting with monoparesis. *Ann Thorac Surg.* 1986;42:210–12.
16. Rao KC. Degenerative diseases and hydrocephalus. In: Lee SH, Rao KC, Zimmerman RA, editors. *Cranial MRI and CT.* New York: McGraw-Hill; 1999. pp. 212–4.
17. Nieman EA, Fullerton PM: Electroencephalographic findings in unilateral cerebral atrophy. *Neurology.* 1963;13:213-218.