

Role of office sac massage for congenital nasolacrimal duct obstruction in various age-groups

Nishith Panwar^{1,*}, Vimlesh Sharma², Kalpana Kumari³

^{1,3}PG Student, ²Assistant Professor, Govt. Medical College, Haldwani, Uttarakhand

***Corresponding Author:**

Email: doctornishith@gmail.com

Abstract

Purpose: To determine the success rate of hydrostatic office sac massage for congenital nasolacrimal duct obstruction (CNDLO) in various age groups.

Methods: 72 eyes of 65 patients aged 2 to 36 months diagnosed with CNDLO were included and divided into 6 groups; 2-4 months, group 2: 5-6 months, group 3: 7-12 months, group 4: 13-18 months, group 5: 19-24 months and group 6: 24-36 months. Office sac massage was done and patient was followed up at regular intervals upto three months. Successful procedure was documented as complete remission of symptoms in subsequent visits following the procedure.

Results: Overall success rate of sac massage was 79.1%. Success rate was high in lower age groups (100% in group 1, 95.6% in group 2, 83.3% in group 3, 72.7% in group 4) and lower in higher age groups (33.3% in group 5 and group 6 respectively).

Conclusion: Hydrostatic office sac massage is an effective conservative treatment for CNDLO, especially in lower age groups. Success rate of the procedure declines in higher age groups and results in subsequent surgical intervention.

Keyword: Sac Massage, Nasolacrimal duct, CNLDO, Hydrostatic, Probing

Introduction

Infants with epiphora are a common problem in clinical ophthalmology which is usually the result of a congenital abnormality of the lacrimal drainage system. In majority of the cases, it is due to a membranous obstruction at the lower end of the nasolacrimal duct (NLD)¹. Congenital nasolacrimal duct obstruction (CNLDO) is a common condition affecting 20% of infants in their 1st year of life and occurs due to the failure of canalization of nasolacrimal duct². Canalization of the NLD usually takes place at the end of six months of intrauterine life. However, it may be delayed for several weeks or months after birth³.

It has been noted that approximately 30% of full term infants have obstruction at birth, however only 2 to 4% become symptomatic⁴. Spontaneous resolution occurs in the majority of the cases by 1 year of age. Different interventions employed to overcome CNLDO range from conservative approaches such as lacrimal sac massage to more intrusive methods such as probing with or without intubation, balloon catheterization, silicone tube intubation, and dacryocystorhinostomy (DCR). Affected children up to 1 year of age are typically treated conservatively with digital sac massage which has been reported to have a high success rate (77–95%)⁵⁻¹⁰. Probing of the nasolacrimal duct is generally attempted after a child is more than 1 year of age⁶⁻⁸ and is generally quite effective with success rates ranging from 77% to 97% after 1st time application. Despite of its high success rates, the procedure is associated with risks of general anaesthesia, false passage formation canalicular fibrosis.

The diagnosis of CNLDO is based on a history of a watering/discharging eye within the first few weeks after

birth which may be complicated by conjunctivitis in some cases. The diagnosis can be confirmed by gently pressing over the nasolacrimal sac and observing mucopurulent material refluxing from either punctum¹¹.

It is observed that the technique of the massage generally advice to the parents did not have successful resolution of symptoms due to its faulty application and results in high rate of probing subsequently¹². The purpose of this study is to evaluate the success rate of hydrostatic office sac massage in CNDLO in various age groups.

Methods

This is a prospective study conducted at Department of Ophthalmology, Government Medical College, Haldwani from December 2014- December 2015. 72 eyes of 65 patients with CNDLO in the age group of 2-36 months were included in the study. Diagnosis of CNLDO was based on the presenting symptoms such as watering, discharge, swelling and redness near medial canthus notice since or shortly after birth. Acute dacryocystitis was diagnosed by the presence of acute onset swelling of the lacrimal sac area along with pain, redness, and tenderness. Cases with a history of multiple recurrences and remissions of pain and swelling were diagnosed as chronic dacryocystitis whereas mucocele was defined as the presence of asymptomatic swelling of the lacrimal sac area. Fistula was characterized by an abnormal opening around the sac area with or without discharge. Patients with a minimum follow-up of 3 months from the day of presentation were included in the study. Acquired NLDO due to trauma or craniofacial anomalies, and excessive tear production from a non-CNLDO induced etiology such as allergic

conjunctivitis and congenital glaucoma were excluded. Children who had undergone previous failed medical intervention or surgical procedures such as probing were also excluded. In cases with simultaneous or sequential bilateral presentation, each eye was considered as an independent case to avoid selection bias. ENT evaluation was done to rule out any nasal pathology. Patients with associated URTI were treated before performing the procedure. Informed consent was obtained from the parents of the patients.

The children were divided into 6 age strata including group 1: 2-4 months, group 2: 5-6 months, group 3: 7-12 months, group 4: 13-18 months, group 5: 19-24 months, group 6: 24-36 months.

Technique of hydrostatic office sac massage

Parents were instructed not to empty the sac 1 day before visiting the OPD. While performing the office sac massage, place the tip of the index finger over at the inner canthus pressed in such a way that it presses the puncta and canaliculi which blocks the reflux of secretions through the puncta into the conjunctival sac after which it is pressed firmly medially and downwards to increase the hydrostatic pressure within the NLD which results in a feeling of give way along with a snap sound which indicates an effective massage. Antibiotic

drops were instilled by the parents for two weeks. Weekly follow up is done and the successful massage was documented as complete remission of watering and discharge with no reflux on applying pressure over lacrimal sac massage two weeks after the procedure. The procedure was repeated on a full sac if not successful on previous attempt. Patient was followed up for three months duration.

Results

A total of 72 eyes of 65 patients, including 34 males and 31 females were included in the study. Unilateral obstruction was present in 58 patients and bilateral obstruction was present in 7 patients. The most common sign was epiphora with discharge followed by epiphora and swelling at the medial canthus. There was regurgitation of mucoid /mucopurulent discharge on applying pressure over the lacrimal sac in most of the patients.

The overall success rate of hydrostatic office sac massage was 79.1%. The rate of success was high upto 12 months (100% in 2-4 months, 95.6% in 5-6 months and 83.3% in 7-12 month age group) and low in the higher age groups.

Table 1: Success rate of hydrostatic sac massage in various age groups

Groups	Age group(months)	No. of eyes	Total successful NLD opening (%)
Group 1	2-4	8	8 (100)
Group 2	5-6	23	22 (95.6)
Group 3	7-12	18	15 (83.3)
Group 4	13-18	11	8 (72.7)
Group 5	19-24	9	3(33.3)
Group 6	25-36	3	1 (33.3)
Total		72	57 (79.1)

Bar chart showing success rate of office sac massage in different age groups

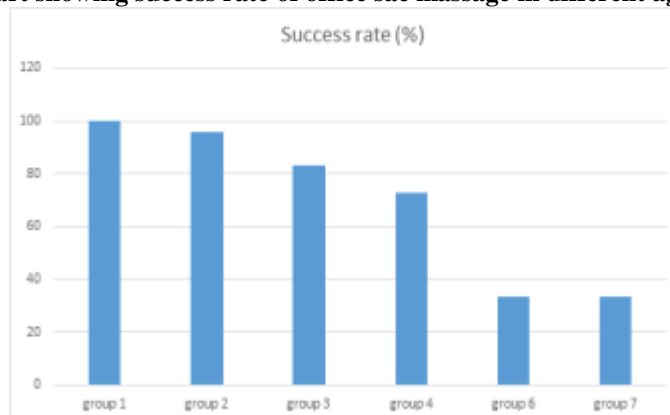


Table 2: Showing frequency of visits required for successful opening of NLD in various age groups

Age group(months)	No. of successful NLD openings	Successful opening of NLD		
		After first massage	After second massage	After third massage
2-4	8	5 (62.5)	3(37.5)	0(0)
5-6	22	11(50)	9 (40.9)	2 (22)
7-12	15	(16.6)	4 (33.3)	6 (50)
13-18	8	2 (25)	2 (25)	4 (50)
19-24	3	0 (0)	1 (33.3)	2 (66.6)
25-36	1	0 (0)	1 (100)	0 (0)

Discussion

Though it is widely known that massage of the nasolacrimal system relieves many congenital NLD obstructions during early infancy, the correct technique of massage is not properly understood by most parents resulting in a high failure rate and need for probing.

In 1923, Crigler¹³ stressed that proper massage of the NLD resulted in a 100% cure rate over an observation period of 7 years. However, he did not mention the number of infants in his study. Using the same technique Price¹⁴ in 1947 reported a cure rate of 94.6% in 203 infants with NLD obstruction by the age of one year. Peterson and Robb¹⁵ in 1978 studied the natural course of congenital NLD obstruction in 50 infants and found that 44 had spontaneous resolution with medical management. Kushner¹⁶ in 1982 demonstrated clearance of obstruction in 31 % of 59 eyes with proper massage as compared to 9% of 58 eyes with simple massage. In our study, the overall success rate was 79.1%. The success rate is highest in 2-4 month and 4-6 month age group (100%) which is comparable to the success rate of 91% with proper technique of massage the study of Shivpuri et al¹².

We observed that upto 3 office sac massage at one weekly interval have equivalent or even better results when compared to the daily sac massage done by the parents at home. This may be due to the result of the improper method used by the parents which results in failure rates and subsequent probing¹⁰.

In a large, prospective, nonrandomized trial enrolling children from 6 to 48 months undergoing primary probing, the Pediatric Eye Disease Investigator Group (PEDIG) investigators concluded that increasing age had no impact on the success rates of probing up to 36 months¹⁷. Therefore hydrostatic office sac massage should be considered as a primary procedure in cases of CNLDO upto 3 years of age. It serves as an effective conservative management, especially in the lower age groups. However with increasing age, the success rate of the procedure declines.

References

1. MacEwen CJ, Young JD. Epiphora during the first year of life. *Eye (Lond)* 1991;5(Pt 5):596-600.
2. Hughes RK, FitzGerald DE. Congenital nasolacrimal duct obstruction: An optometric perspective. *J Behav Optom* 2000;11:94-6.

3. Kersten RC. Congenital lacrimal abnormalities. In: Bosniak S (ed). *Principles and practice of ophthalmic plastic and reconstructive surgery*, Vol 2. 1st ed. Philadelphia: W.B. Saunders; 1995:731-747.
4. Jones LT, Wobig JL. *Surgery of the eyelids and lacrimal system*. 1st ed. Birmingham: Aesculapius Publishing Co; 1976.
5. Nelson LR, Calhoun JH, Menduke H. Medical management of congenital nasolacrimal duct obstruction. *Ophthalmology* 1985;92:1187-90.
6. Baker JD. Treatment of congenital nasolacrimal system obstruction. *J Pediatr Ophthalmol Strabismus* 1985;22:34-6.
7. Casady DR, Meyer DR, Simon JW, Stasiar GO, Zobal-Ratner JL. Stepwise treatment paradigm for congenital nasolacrimal duct obstruction. *Ophthal Plast Reconstr Surg* 2006;22:243-7.
8. Katowitz JA, Welsh MG. Timing of initial probing and irrigation in congenital nasolacrimal duct obstruction. *Ophthalmology* 1987;94:698-705.
9. Stager D, Baker JD, Frey T, Weakley DR Jr, Birch EE. Office probing of congenital nasolacrimal duct obstruction. *Ophthalmic Surg* 1992;23:482-4.
10. Success Rate of Probing for Congenital Nasolacrimal Duct Obstruction at Various Ages. *J Ophthalmic Vis Res* 2014;9(1):60-64.
11. Bhandari S, Sengupta S, Yadalla D, Rajagopalan J, Velis GB, Talele D, et al. Factors affecting treatment outcome in congenital nasolacrimal duct obstruction: A retrospective analysis from South India. *Indian J Ophthalmol* 2015;63:759-62.
12. Shivpuri D, Puri A. Congenital Nasolacrimal Duct Obstruction: The Proper Technique of Massage. *Indian Pediatrics*. Volume 31 March 1994:337-40.
13. Crigler LW. The treatment of congenital dacryocystitis. *JAMA* 1923;81:23-24.
14. Price HW. Dacryostenosis. *J Pediatr* 1947;30:302-305.
15. Peterson RA, Robb RM. The natural course of congenital obstruction of the nasolacrimal duct. *J Pediatr Ophthalmol Strabismus* 1978;15:246-250.
16. Kushner BJ. Congenital nasolacrimal system obstruction. *Arch Ophthal* 1982;100:597-600.
17. Pediatric Eye Disease Investigator Group, Repka MX, Chandler DL, Beck RW, Crouch ER rd, Donahue S, et al. Primary treatment of nasolacrimal duct obstruction with probing in children younger than 4 years. *Ophthalmology* 2008;115:577-584.e3.