

Histomorphological spectrum of paediatric surgical lesions: experience at a tertiary care centre

Seema Bijjaragi¹, Parismrita Borah², Omkar Puvvala^{3,*}

¹Associate Professor, ^{2,3}PG Student, JJM Medical College, Davangere, Karnataka

***Corresponding Author:**

Email: doctorpuvvala@gmail.com

Abstract

Aim: The aim of this study is to understand the profile of paediatric surgical pathology specimens in our region. There is paucity of studies on the histologic review in India.

Materials & Methods: This is a retrospective analysis of 462 cases of paediatric surgical specimens (Age group 0-12 years) in surgical pathology in a tertiary care centre encountered over a period of one and a half years.

Results: Out of 462 cases, 353(76.41%) cases belonged to acquired conditions (both Non-neoplastic and Neoplastic), and 109 (23.59%) cases belonged to congenital and developmental conditions. Males constituted 62.55% while females 37.45%. Gastrointestinal tract was most commonly affected (40.26%) followed by head & neck region (26.19%) and renal & urogenital system (15.58% each).

Among acquired conditions (Non-neoplastic and Neoplastic), the most common diagnosed condition was Appendicitis (27.19%) followed by Chronic tonsillitis (24.93%), Inguinal hernia (6.79%), Hydrocele (4.25%), Hemangioma (3.68%), Nonspecific lymphadenitis (3.39%), Empyema (2.83%), TB lymphadenitis and Juvenile polyp (2.55% each) etc. Among acquired neoplastic lesions, there were 4 cases of Wilms tumor, 4 cases of Osteochondroma, 1 case of Fibrous dysplasia, 2 cases of NHL, 1 case of Retinoblastoma, 6 cases of Lipoma and 1 case of Infantile rhabdomyosarcoma.

Among congenital and developmental conditions, the most common condition was Hirschsprung's disease (18.35%), Pelvic ureteric junction obstruction (11%), Meckel's diverticulum & anorectal malformations (9.17% each), Testicular anomalies & enterogenous cyst (6.42% each) etc.

Conclusion: The histopathological patterns of surgical pathology specimens in childhood differ from adults. There are very few published reports on histopathological profile of paediatric surgical pathology specimens in India. Hence, we conducted this study to characterize the histopathological types of surgical pathology specimens among the paediatric patients.

Keywords: Paediatric, Congenital, Developmental, Acquired.

Access this article online	
Quick Response Code:	Website: www.innovativepublication.com
	DOI: 10.5958/2394-6792.2016.00075.2

Introduction

The surgical pathology specimens differ from adults in their management and natural history and present a number of challenges for the pathologist. They are affected by several factors such as topographical location, tropical atmosphere and socio-economical conditions. They range from developmental and congenital anomalies to acquired conditions, benign and malignant neoplasm and other space occupying lesions. Paediatric surgical specimens differ from adults in having major proportion of congenital and developmental conditions. There are very few studies related to the general profile of paediatric surgical specimens in histopathology centers and laboratories. Search of previous literatures uncovers absence of reports, especially in India. In our study we have attempted to study the histopathological profile of

paediatric surgical specimens from a tertiary care centre in Central Karnataka.

Materials and Methods

This is a retrospective analysis of 462 cases of paediatric surgical specimens (Age group 0-12 years) in the department of pathology of a tertiary care centre encountered over a period of one and a half years from January 2014 to June 2015. Surgical specimens and biopsy tissues received were fixed overnight in 10% formalin and submitted for processing. Paraffin sections were cut and routine Hematoxylin and Eosin (H & E) staining were performed. All cases were evaluated histologically and Special stains & Immunohistochemistry were studied wherever necessary. The clinical, radiological and therapeutic data were obtained from patient's case papers. The cases were categorized according to age into three groups, age less than or equal to 5 years, 6 -10 years and more than 10 years. The histopathological diagnoses of the lesions were then categorized into two groups, 'congenital & developmental' and 'acquired' conditions, the later further subdivided into 'non-neoplastic' and 'neoplastic' lesions.

Results

Out of 462 cases, 353 (76.41%) cases belonged to acquired conditions, which included acquired non-neoplastic conditions (333 cases) and acquired neoplastic conditions (20 cases), and 109 (23.59%) cases belonged to congenital and developmental conditions.

Age-wise and gender-wise distribution

Males constituted 289 (62.55%) where as females were 173 (37.45%). Males were affected more than females in both the acquired conditions as well as congenital and developmental disorders. Among 353 cases of acquired conditions 63.45% were males and 36.55% were females where as out of 109 cases of congenital and developmental lesions 59.63% were males and 40.37% were females.

Their age ranged from one day old child to twelve years. Majority of the cases belonged to the age group of 0-5 years followed by 6-10 years and more than 10 years with the percentages of 46.1%, 33.33% and 20.56% respectively. Children with acquired conditions accounted for 41.08% followed by 34.84%, and 24.08% respectively in 6-10 years, 0-5 years and more than 10 years. Among congenital and developmental disorders, the incidence was highest in the age group of 0-5 years followed by more than 10 years and 6-10 years with the percentage of cases 82.57%, 9.17% and 8.26% respectively.

Distribution of surgical pathology specimens

Among acquired conditions (both non-neoplastic and neoplastic), the most common diagnosed condition was Appendicitis which includes both acute and chronic 27.19% (96 cases) followed by Chronic tonsillitis (24.93%), Inguinal hernia (6.79%), Hydrocele (4.25%), Hemangioma (3.68%), Nonspecific lymphadenitis (3.39%), Empyema (2.83%), TB lymphadenitis and Juvenile polyp (2.55% each) etc. Among acquired neoplastic lesions, there were 4 cases

of Wilms tumor, 4 cases of Osteochondroma, 1 case of Fibrous dysplasia, 2 cases of NHL, 1 case of Retinoblastoma, 6 cases of Lipoma and 1 case of Infantile rhabdomyosarcoma. (Table 2 & 3 and Fig. 1)

Among congenital & developmental conditions, the most common condition was Hirschsprung's disease (18.35%), Pelvic ureteric junction obstruction (11%), Meckel's diverticulum & anorectal malformations (9.17% each), Testicular anomalies & enterogenous cyst (6.42% each) etc. (Table 1 and Fig. 1)

A total of 96 appendectomy specimens were received. Chronic appendicitis (74%) was more common than acute condition. Appendicitis was 1.5 times more common in males and most common age group affected was 5-10 years.

Second most frequent specimen received was tonsillectomy, with 24.93% cases diagnosed as chronic tonsillitis. Occurrence was slightly higher in males than in females and common age group was 5-10 years.

A total of 28 colorectal biopsies were received with suspicion of Hirschsprung's out of which 20 specimens were diagnosed as Hirschsprung's disease. There was male preponderance with male to female ratio of 6:1.

Hemangioma was diagnosed in 13 patients and more number of cases was seen in age group 5-10 years.

Pelvic ureteric obstruction was reported in 12 cases (11%). Majority of these cases were diagnosed during infancy and preschool going age. Male to female ratio was 5:1. Anorectal malformation was seen in 10 cases (9.17%) including recto vesical fistula, ano rectal fistula, vaginorectal fistula, imperforate anus, and ectopic anus.

Gastrointestinal tract was most commonly affected with both congenital & developmental and acquired conditions, which occupied 40.26% out of total 462 cases and followed by head & neck region (26.19%), renal & urogenital system (15.58%), Musculoskeletal system (7.56%), Lymph nodes (5.19%), Lung (3.89%) and Nervous system (1.29%). (Table 4 and Fig. 2)

Table 1: Congenital and developmental lesions

Sl. no	Diagnosis	Total	Male	Female	0-5yr	6- 10yr	>10yrs
1	Meckel's diverticulum	10	6	4	6	2	2
2	Hirschsprung's disease	20	17	3	18	1	1
3	Intestinal duplication	2	1	1	2	0	0
4	Choledochal cyst	4	0	4	3	1	0
5	Branchial cyst/sinus/fistula	6	2	4	2	2	2
6	Thyroglossal duct cyst	1	1	0	0	0	1
7	Cystic hygroma	6	3	3	6	0	0
8	PUJ obstruction	12	10	2	10	2	0
9	Bladder diverticulum	1	1	0	1	0	0
10	Urachal cyst	1	1	0	1	0	0
11	Extrahepatic biliary atresia	2	2	0	2	0	0
12	Testicular anomalies	7	7	0	5	1	1
13	Umbilical hernia	5	2	3	5	0	0

14	Preauricular developmental anomalies	6	2	4	5	0	1
15	Anorectal malformation(ARM)	10	2	8	10	0	0
16	Intestinal atresia	2	1	1	2	0	0
17	Enterogenous cyst	7	3	4	6	0	1
18	Thymic cyst	1	1	0	0	0	1
19	Neural tube defects	6	3	3	6	0	0
	Total	109	65	44	90	9	10

Table 2: Acquired non-neoplastic lesions

Sl. no	Diagnosis	Total	Male	Female	0-5yr	6-10yr	>10yrs
1	Intussusception of intestine	2	0	2	2	0	0
2	Osteomyelitis	6	3	3	2	4	0
3	Chronic tonsillitis	88	47	41	5	52	31
4	Synovitis	4	2	2	3	1	0
5	Thymic necrosis	1	0	1	1	0	0
6	Empyema	10	4	6	8	2	0
7	Intestinal Perforation	2	2	0	2	0	0
8	Intestinal obstruction	1	0	1	1	0	0
9	Hydrocele	15	15	0	12	3	0
10	Nasal polyp	2	1	1	0	2	0
11	Inflammatory polyp	2	2	0	0	2	0
12	Interstitial nephritis	1	1	0	1	0	0
13	Bronchopneumonia	1	0	1	1	0	0
14	Pyogenic granuloma	2	0	2	0	1	1
15	Chronic adenoiditis	1	0	1	0	0	1
16	Aural polyp	1	0	1	0	1	0
17	Rosai dorfman disease	1	1	0	0	1	0
18	Microvesicular fatty liver	1	0	1	1	0	0
19	Acute & Chronic enteritis	2	2	0	2	0	0
20	Bursal cyst	1	1	0	0	1	0
21	Tuberculae abdomen	1	1	0	1	0	0
22	Cirrhosis with hepatitis	1	1	0	1	0	0
23	Foreign body aspiration	1	1	0	1	0	0
24	Chronic cholecystitis	1	0	1	0	1	0
25	A-V malformation	1	0	1	0	0	1
26	Torsion of testis	5	5	0	3	1	1
27	Appendicitis	96	60	36	13	49	34
28	Suppurative abscess	5	2	3	4	0	1
29	TB lymphadenitis	9	8	1	5	3	1
30	Inguinal hernia	24	23	1	21	2	1
31	juvenile polyp	9	7	2	6	1	2
32	hemangioma	13	7	6	4	6	3
33	Muscular dystrophy	2	2	0	1	1	0
34	Storage disorder	2	2	0	2	0	0
35	Bile duct obstruction	1	1	0	1	0	0
36	Teratoma(immature)	2	1	1	2	0	0
37	Umbilical adenoma	2	1	1	2	0	0
38	Rectal mucosa prolapse	1	0	1	1	0	0
39	Congestive splenomegaly	1	1	0	0	1	0
40	Nonspecific lymphadenitis	12	6	6	4	5	3
	Total	333	210	123	113	140	80

Table 3: Acquired neoplastic lesions

Sl. No	Diagnosis	Total	Male	Female	0-5yr	6- 10yr	>10yrs
1	Non hodgkin lymphoma	2	1	1	1	1	0
2	Osteochondroma	4	3	1	1	2	1
3	Lipoma	7	5	2	4	1	2
4	Retinoblastoma	1	1	0	0	1	0
5	Wilms tumor	4	2	2	3	0	1
6	Infantile rhabdomyosarcoma	1	1	0	1	0	0
7	Fibrous dysplasia(femur)	1	1	0	0	0	1
	Total	20	14	6	10	5	5

Table 4: Distribution of lesions (system wise)

Sl. No	System	Total	Male	Female	Acquired	Congenital and developmental
1	Gastrointestinal tract	186	113	73	124	62
2	Head and Neck region	121	63	58	101	20
3	Musculoskeletal system	35	21	14	35	0
4	Lymph node	24	16	8	24	0
5	Renal & urogenital	72	66	6	51	21
6	Lung	18	7	11	18	0
7	Nervous system	6	3	3	0	6
	Total	462	289	173	353	109

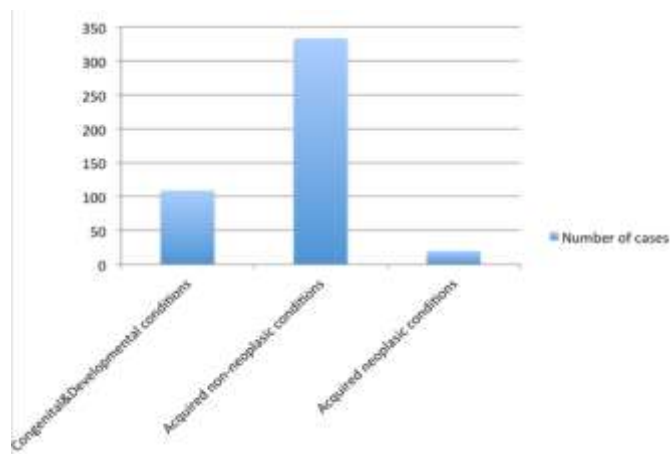


Fig. 1: Distribution of Cases

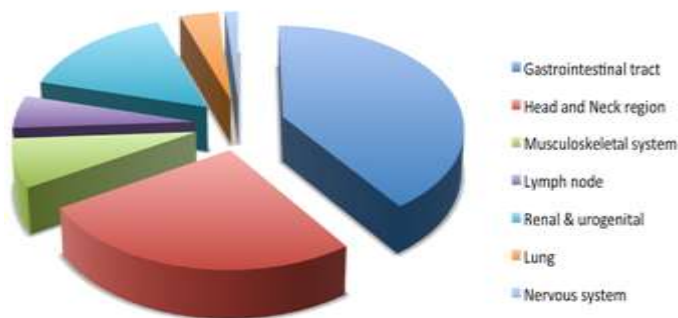

Fig. 2: System wise distribution of lesions



Fig. 3: Hirschsprung's disease. Enzyme histochemistry showing aberrant acetylcholine esterase (AChE)-positive fibers in the lamina propria mucosae

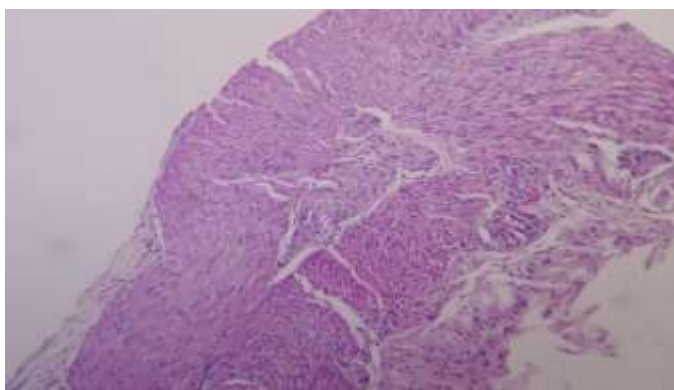


Fig. 4: Hirschsprung's disease. H&E section showing absence of ganglion cells and hypertrophy of nerve endings

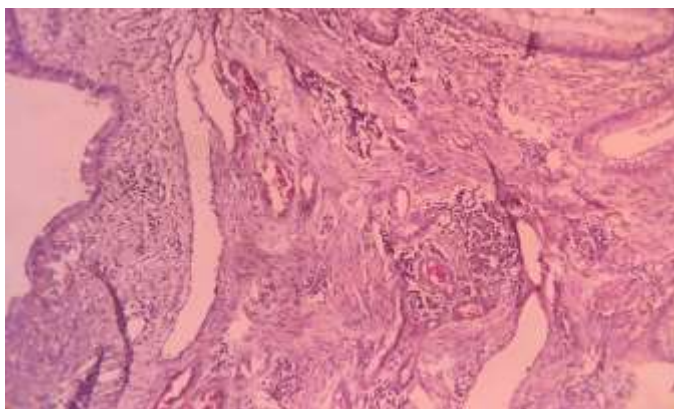


Fig. 5: Juvenile polyp. H&E section showing cystically dilated glands and inflammatory infiltrate in the stroma

Discussion

In the present study we retrospectively analyzed 462 cases of paediatric pathology specimens. Gastrointestinal tract was most commonly affected with both congenital & developmental and acquired conditions.

Appendicitis is the most common clinical condition requiring emergent abdominal surgery in children.¹ Majority of the cases belonged to age 6-10 years followed by age more than 10 years and males were

affected 1.5 times more, compared to females. Similar observation was made by Shah et al.² Presently there has been a drastic decrease in the mortality of children with acute appendicitis as a result of vigorous fluid resuscitation, advances in anesthetic technique, and antibiotic therapy.³

Tonsillectomy is one of the most frequently performed surgeries in paediatric population. Removal of tonsils is generally considered safe with no long term immunological effects. Study by Paradise J et al.⁴ on

efficacy of tonsillectomy for throat infection in severely affected children, showed that the incidence of throat infection was significantly lower ($P < 0.05$) in patients undergoing tonsillectomy compared to non surgical patients.⁴ Study by Mattila et al. on 483 patients who underwent tonsillectomy and adenoidectomy showed that frequency of tonsillectomy operations were multimodal, the frequency increased in preschool age children, declined thereafter and increased in teenagers.⁵ In our study, highest frequency of tonsillectomy was seen in age group 5-10 years followed by more than 10 years, with almost equal sex ratio. A survey in the trends of indication of tonsillectomy by Parker NP et al found that obstruction has become a more prominent indication than infection for paediatric tonsillectomy in younger children while infection becomes a more prominent indication as age increases.⁶

Hirschsprung's disease is a developmental disorder of the enteric nervous system which is characterized by the absence of ganglion cells in the myenteric and the submucosal plexuses of the distal intestine. In nearly half of the patients the diagnosis of Hirschsprung's disease is established by first 3 months of life and in another 20% by the first year of life. Up to 15% of cases may be diagnosed as late as 5 yrs of age.⁷ The diagnosis of clinically suspected Hirschsprung's disease is confirmed by the absence of ganglion cells along with hypertrophied nerve bundles in a rectal biopsy. (**Fig. 4**) In our study, Hirschsprung's disease was the most common disorder in congenital and developmental group. Out of 28 rectal biopsies received, 20 cases were diagnosed to be Hirschsprung's disease. Diagnoses were made both by AChE enzyme histochemistry on frozen sections of rectal biopsy supplemented by Haematoxylin and Eosin staining of serial sections of rectal biopsy. (**Fig. 3**) Majority were diagnosed in age less than 1 month (8 cases) followed by age between 1 month to 1 year (7 cases) and remaining 5 cases at age more than 1 year. The male to female sex ratio was approximately 6:1 in present study, however western literature reports male preponderance with male to female sex ratio of 4:1. A study by Shah N et al on profile of paediatric surgery specimens from western India, also found Hirschsprung's disease as the most common disorder in the congenital and developmental group with male to female ratio being 4:3.²

Hemangiomas are one of the most common benign tumors of infancy. They are unlikely to be present at birth, although the majority (80%) appears during the first month of birth. So, fully formed vascular lesion on a newborn is a vascular malformation and one develops in the neonatal period is hemangioma.⁸ In our study, majority of cases were diagnosed at age 5-10 years with equal incidence in both genders, the most common type being Capillary hemangioma.

Meckel's diverticulum is the most common congenital malformation of the gastrointestinal tract;

most studies suggest an incidence between 0.6% and 4%. This is due to the persistence of the proximal part of the congenital vitello-intestinal duct. It is a true diverticulum, typically located on anti-mesenteric border, and contains all the layers of intestinal wall with its separate blood supply from the vitelline artery.⁹ Ricardo Quarrie et al¹⁰ did a review of the incidence and Management of Meckel's Diverticulum and found incidence is more in males compared to females with the ratio of 1.5-4.1, which was also reflected in our study. In our study we have observed presence of ectopic gastric tissue in four specimens (40%) and ectopic pancreatic tissue in one specimen (10%). Complication of gangrene was present in three specimens out of ten.

Juvenile polyps: Polyps occur in as many as 1% of children, and 90% of colonic polyps in children are "juvenile" as defined histologically.¹¹ Juvenile polyps are generally thought to be hamartomatous lesions with little malignant potential. "Juvenile polyposis coli," on the other hand, is a rare condition with neoplastic potential.¹² In our study we found males were affected more than females and most common age group affected was 0-5 years, the diagnosis was made on the basis of both gross appearance and histological findings. (**Fig. 5**)

Inguinal hernias: The literature available so far has shown incidence of paediatric inguinal hernias is significant and males are more vulnerable with right sided occurrence¹³, which is also correlating with our study. In this study we confirmed the diagnosis of inguinal hernia in 24 patients (6.79% in acquired conditions).

Intussusception is defined as the invagination of a proximal segment of the intestine into a distal segment of the intestine.¹⁴ Patients usually present with classic triad of abdominal lump, abdominal pain, and bloody stools. It is the most common cause of acute intestinal obstruction in infants and young children which results in significant mortality and morbidity if not properly treated. Approximately, two-thirds of all intussusceptions in children occurring among infants aged less than one year.¹⁵ A 9 year retrospective study by Pandey A et al found the mean age at presentation to be 3.24 ± 2.49 years, and male: female ratio 2.5:1.¹⁶ However, in our study there were two cases and both were females and presented in less than 5 year age group.

Wilms tumor (WT) is the commonest paediatric renal tumor found in children below five years age.¹⁷ In our study three cases were found under the age of five years and one was above ten years. Most often, patients present with a palpable abdominal mass accidentally noted by the parents or in the course of a routine clinical examination. However, about one-third of patients present with abdominal pain, anorexia, vomiting, malaise or a combination of these symptoms. Gross or microscopic hematuria is found in 30% of

patients. In rare cases, renal vein or caval extension of tumor, varicocele, hepatomegaly, ascites or congestive heart failure may be present.¹⁷ In our study out of four cases, two cases presented with abdominal pain and vomiting and one more case has shown ascites and hepatomegaly. Histopathological examination showed tri-phasic tumor in three cases, while one case has shown diffuse blastemal pattern. The present study correlates with study by Shah et al.²

The current study is a single institution based study restricted by a small sample size and this retrospective review cannot serve as a benchmark for reference. This study is an attempt to provide a complete spectrum of paediatric surgical pathology specimens.

Conclusion

Congenital and developmental conditions constitute a significant portion of paediatric surgical pathology specimens. Histological type is important for understanding etiology and progression of disease, as the management and natural history differs from adults. There is no proper data and reports on surgical pathological specimens in childhood in India. Scarcities of specialized surgical centers are one of the causes for paucity of data. In this study we have categorized the cases as 'acquired' and 'congenital and developmental' conditions along with the histopathological profile of the cases.

Source of Support: Nil

Conflict of Interest: None declared

References

1. Janik JS, Firor HV. Pediatric appendicitis: a twenty-year study of 1640 children at Cook County Hospital. *Arch Surg* 1979;114:717-19.
2. Shah N, Shah A, Kamdar J, Shah J. Paediatric Surgical Pathology-a Profile of cases from western India and Review of Literature. *J Clin Diagn Res* 2015 Jan;9:08-11.
3. Rosser SB, Ahmad N. Appendicitis in the Pediatric Age Group. *J Natl Med Assoc.* 1988 Apr;80(4):401-3.
4. Paradise JL, Bluestone CD, Bachman RZ, Colborn DK, Bernard BS, Taylor FH et al. Efficacy of tonsillectomy for recurrent throat infection in severely affected children. Results of parallel randomized and nonrandomized clinical trials. *N Engl J Med.* 1984 Mar 15;310(11):674-83.
5. Mattila PS, Tahkokallio O, Tarkkanen J, Pitkaniemi J, Karvonen M, Tuomilehto J. Causes of tonsillar disease and frequency of tonsillectomy operations. *Arch Otolaryngol Head Neck Surg.* 2001 Jan;127(1):37-44.
6. Parker NP, Walner DL. Trends in the indications for pediatric tonsillectomy or adenotonsillectomy. *Int J Pediatr Otorhinolaryngol.* 2011 Feb;75(2):282-5.
7. Moore IE, Banxendine-Jones J. Diagnosis and molecular pathology of Hirschsprungs disease. In: lowe DG, Underwood JCE, editors. *Recent Advances in Histopathology.* No 19. Edinburg: Churchill Livingstone 2001.p51-66.
8. Washman JE, Honig PJ. Hemangiomas. *Pediatrics in Review* 1994;15:266-71.
9. Sagar J, Kumar V, Shah DK. Meckel's diverticulum: a systematic review. *J R Soc Med* 2006;99:501-5.
10. Quarrie R, Lindsey D, Bahner DP. Review of the Incidence and Management of Meckel's Diverticulum. *Austin J Surg* 2014;1(3):1015
11. Poddar U, Thapa BR, Vaiphei K, Rao KLN, Sing K. Juvenile polyposis in a tropical country. *Arch Dis Child* 1998;78:264-66.
12. McColl I, Bussey HJR, Veale AM, et al. Juvenile polyposis coli. *Proc R Soc Med* 1964;57:896-7.
13. Ein SH, Njere I, Ein A. Six thousand three hundred sixty-one pediatric inguinal hernias: a 35-year review. *J Pediatr Surg* 2006;41:980-86.
14. Buettcher M, Baer G, Bonhoeffer J, Schaad UB, Heininger U. Three-year surveillance of intussusception in children in Switzerland. *Pediatrics* 2007;120:473-80.
15. Bhowmick K, Kang G, Bose A, Chacko J, Boudville I, Datta SK et al. Retrospective Surveillance for Intussusception in Children Aged Less than Five Years in a South Indian Tertiary-care Hospital. *J Health popul nutr* 2009 Oct;27(5):660-5.
16. Pandey A, Singh S, Wakhlu A, Rawat J. Delayed presentation of intussusception in children-a surgical audit. *Ann Pediatr Surg* 2011;7:130-32.
17. Tongaonkar HB, Qureshi SS, Kurkure PA, Muckaden MA, Arora B, Yuvaraja TB. Wilms' tumor: An update. *Indian J Urol* 2007;23:458-66.