

## Role of guided fine needle aspiration cytology in mass lesions of liver

Pradeep Tandon<sup>1,\*</sup>, Winnie Gautam<sup>2</sup>

<sup>1</sup>Associate Professor, Mayo Institute of Medical Sciences, Barabanki, Uttar Pradesh, <sup>2</sup>Consultant Pathologist, Dept. of Pathology, Ama Diagnostic, Lucknow, Uttar Pradesh

**\*Corresponding Author:**

Email: tandonp72@yahoo.co.in

### Abstract

**Introduction:** High incidence of liver diseases is seen in our country. Diseases of liver that present as a mass lesion can be a diagnostic dilemma. Nowadays guided fine needle aspiration cytology (FNAC) is utilized with greater frequency to identify and diagnose such lesions. The present study was carried out to investigate the profile of liver diseases presenting as a mass lesion in a primary care setting, using guided FNAC as a diagnostic tool. Amongst these patients, efficacy of FNAC in segregating a cohort that needs palliative care only – at the level of primary care medical facility - is also analysed. This would help in minimizing the economic burden of the patient and the expenditure entailed by the society; thereby allowing proper use of scarce medical facilities in resource poor countries.

**Methods:** CT or ultrasound guided FNAC was carried out in 83 patients in a primary medical care facility. Based on cytological diagnosis, their demographic profile was analysed.

**Results:** Primary or secondary malignancy was diagnosed in 46 patients. Metastatic carcinoma comprised the predominant group amongst neoplastic lesions of the liver. In 28 patients, diagnosis of pyogenic or amoebic abscess or hydatid cyst was made. It was possible to identify with the help of guided FNAC, a group of patients suitable for palliative care only.

**Conclusions:** Guided FNAC is a cost effective investigative modality at the level of primary care medical facility for diagnosis of mass lesions in liver.

**Keywords:** Guided aspiration cytology, Mass lesions of liver, Pyogenic liver abscess, liver metastasis

Access this article online	
Quick Response Code:	Website: www.innovativepublication.com
	DOI: 10.5958/2394-6792.2016.00076.4

### Introduction

With the advent of newer radiological techniques like ultrasound, CT scan, MRI and nuclear scans, small lesions of liver which went undetected earlier, are now being discovered and investigated routinely. For patients this has been a fortunate development, as it offers the likelihood of early diagnosis and thereby possible curative treatment for a previously incurable disease. However pathologists are now burdened with the prospect of providing a diagnosis with minimal tissue material in form of miniscule biopsies or fine needle aspirates. For lesions of the liver, wide bore needle biopsies provide greater amount of tissue as compared to fine needle aspirates. However, the procedure carries greater risk of complications; it is more expensive, time consuming and uncomfortable for the patient. Because of these reasons, fine needle aspiration cytology (FNAC) is gaining popularity for investigating hepatic disorders. FNAC is used more often for investigating mass lesions in the liver, rather than for diffuse and inflammatory diseases, in which

appreciation of tissue architecture is important<sup>[1]</sup>. Occasionally inflammatory disorders are also investigated by FNAC when they mimic a mass lesion<sup>[2]</sup>.

In our country, because of economic and other factors, patients often present at an advanced stage of their disease. For hepatocellular carcinoma (HCC), best prognosis is seen in solitary stage 1 tumours less than 2 cm in diameter. In larger non-resectable HCC and in metastatic malignancies of the liver, the prospects of a cure are remote and the prognosis is dismal. Survival is usually less than one year<sup>[3]</sup>. In such cases, palliative care often becomes the only recourse available. Under these circumstances, realization of final diagnosis, with minimal discomfort and economic burden to the patient, becomes a practical choice for the clinician. In this endeavour, FNAC often assists as a first choice investigative technique.

In this study, we present our experience of guided FNAC for diagnosis of hepatic lesions. The aim of the study is to:

1. Assess the utility of CT or ultrasound guided FNAC as an investigative modality for mass lesions of the liver at primary care medical facility.
2. To assess the demographic and cytomorphological profile of such patients presenting for FNAC at a primary care medical facility.
3. To assess, whether deployment of FNAC as an investigative tool, helps in segregating a cohort of patients that need to be managed largely by palliative care.

## Material and Method

The study was conducted at Ama diagnostic centre, Lucknow, in collaboration with the department of Pathology, Mayo Institute of Medical Sciences, Barabanki. The period of study is from August 2008 to December 2015. FNAC was performed on patients presenting with single or multiple space occupying lesions in the liver. Fine needle aspiration was performed under ultrasound or CT guidance in 83 cases. The investigation was done after obtaining informed written consent from the patient or from a guardian in case of minors. The risks associated with the procedure were explained to the patient. Aspiration was performed after excluding any co-existing bleeding tendency as determined by prothrombin and activated partial thromboplastin time test.

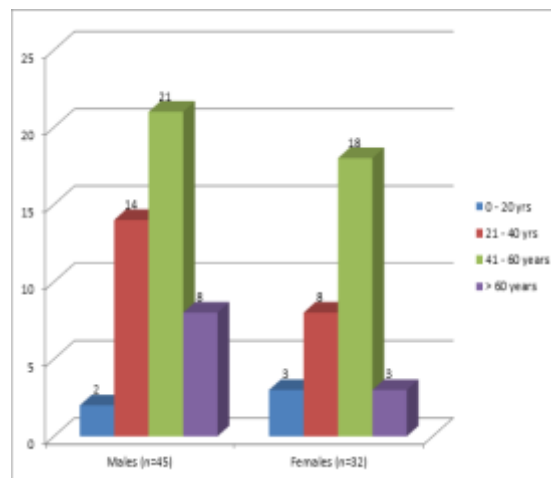
Aspiration was done using an 18 or 21 gauge spinal needle attached to a 10 ml syringe. Skin overlying the site of aspiration was thoroughly cleaned to achieve asepsis. Under radiological guidance, the needle was inserted into the lesion by the radiologist. All efforts were made to place the needle into the peripheral part of the lesion, avoiding necrotic or hemorrhagic areas. The patient was asked to withhold breath and the aspiration was performed by the pathologist.

After obtaining an adequate aspirate; the material was smeared onto glass slides. Both air dried smears for MGG stain or wet fixed smears for H&E and Papanicolaou stain were prepared. A representative smear was stained immediately by Leishman stain for 2-3 minutes. This permitted swift estimation of specimen adequacy although the staining achieved was sub-optimal. The procedure served as a replacement for Diff quick staining technique recommended by other workers for this purpose<sup>[4]</sup>. Subsequently this 'screening smear' was found to stain satisfactorily with MGG stain and thereby no wastage of valuable cytologic material was seen. When the initial aspirate was found inadequate, a re-aspiration procedure was performed in the same sitting. A maximum of three attempts were made to obtain adequate material. When necrotic or purulent material was aspirated, part of it was sent for routine culture and sensitivity assays and for Zeihl Neelsen staining of acid fast bacteria. Every case was examined individually by both pathologists and results were recorded separately. In case of discordant opinion - for purpose of analysis - a final consensus diagnosis was attempted.

## Results

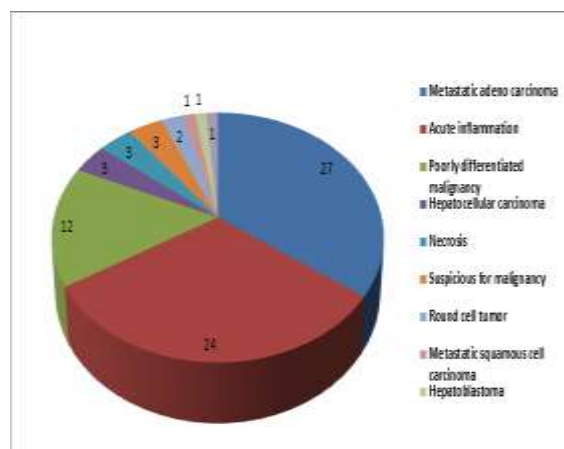
A total of 83 patients underwent guided FNAC procedure during this period. Adequate material was not obtained in 4 patients. In 2 patients, only normal hepatocytes showing cholestasis were seen. This indicated placement of needle outside of the mass. These 6 patients are excluded from further study. The age and sex distribution of remaining 77 patients is shown in Fig. 1. Maximum number of patients

belonged to the age group of 40 to 60 years (79.2% of cases)



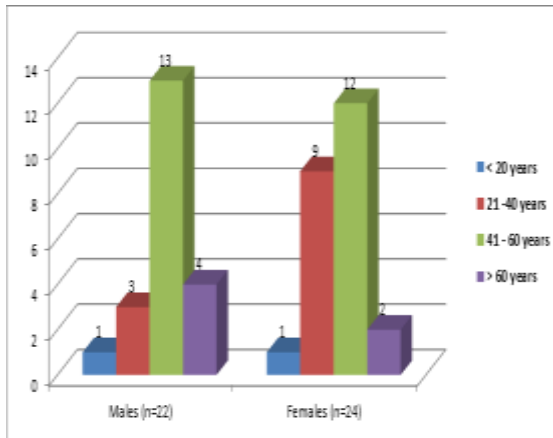
**Fig. 1: Age and sex distribution of patients with liver disease (n=77)**

The disease distribution in these 77 patients is shown in Fig. 2. Maximum numbers of cases were having metastatic adenocarcinoma. Acute inflammatory pathology was the second commonest cause producing a mass lesion in liver.



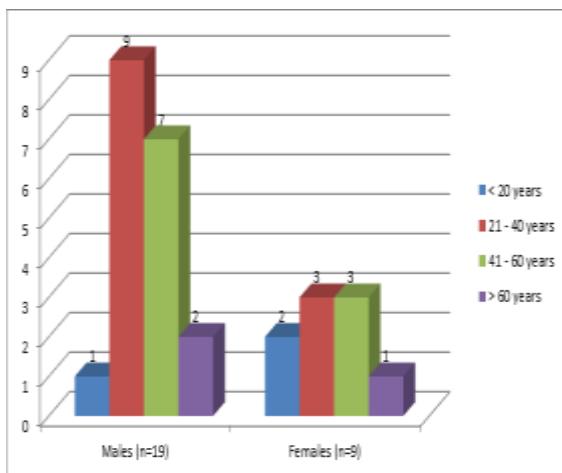
**Fig. 2: Showing distribution of diseases in patients of liver disorder (n=77)**

Definite diagnosis of malignancy was given in 46 patients. Age and sex distribution of these 46 patients is shown in Fig. 3. It is observed that maximum number of malignancies - both in males and females - are seen in between 41 to 60 years of age.



**Fig. 3: Age and sex distribution of patients with malignancy (n=46)**

Age and sex distribution of non-malignant disorders is shown in Fig. 4. It is seen that greater number of males are afflicted by a non-malignant disorder as compared to females. Amongst 28 cases of non-malignant disorder, cytological picture was indicative of pyogenic liver abscess in 24 cases, and in 3 cases, it was suggestive of amoebic liver abscess. 1 case was diagnosed as hydatid cyst.



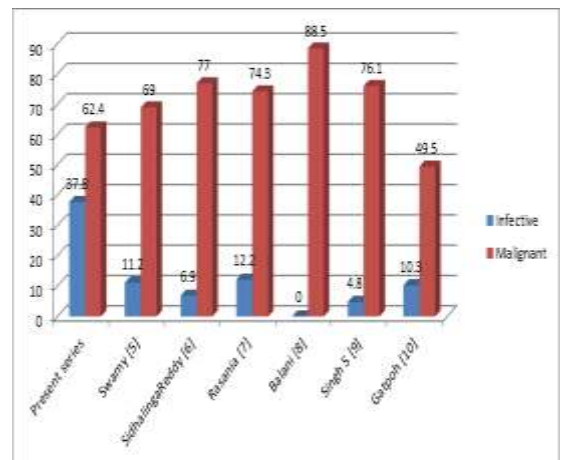
**Fig. 4: Age and sex distribution of patients with non-malignant liver disorders (n=28)**

## Discussion

Focal lesions of liver can be a diagnostic dilemma for the clinician. The possibilities range from benign or malignant primary tumours of the liver, metastatic lesions, different types of cysts and abscesses<sup>[4]</sup>. Both primary and secondary tumours can undergo central necrosis and simulate an abscess. Primary tumours of liver may be multifocal and thus imitate metastases. A patient of cirrhosis can develop hepatocellular carcinoma (HCC) and the neoplastic nodule may remain concealed amongst numerous other nodules. A single metastatic nodule simulates HCC on radiological examination. Chronic abscesses provoke surrounding

fibrosis and thereby imitate a neoplastic lesion. Treatment differs for each of these conditions. Few of them impose enormous economic burden on the patient – something that is of significant relevance to a large number of patients in our set up. Guided FNAC by providing an early diagnosis at a reasonable cost does mitigate some of this distress. And for some lesions, it provides an alternative therapeutic option. FNAC for hepatic lesions is reported to have reasonably good sensitivity, specificity and accuracy - spanning from 70% to 95%<sup>[1]</sup>.

In our series, 3 patients were given a cytological diagnosis of ‘suspicious for malignancy’. They were lost to follow up and no final diagnosis could be achieved. Of the remaining 74 patients, in 28 patients, the mass lesion in liver was caused by pyogenic bacterial or parasitic infection (37.83% of cases). In 46 patients (62.16% of cases), the aetiology was a malignant lesion. No benign tumours were diagnosed. The distribution of infective versus malignant lesions in some other recent series from India<sup>[5-10]</sup> is shown in Fig. 5.



**Fig. 5: Distribution of infective vs. malignant lesions in some other series from India\***

\*Numbers represent percentage of cases in relation to total number of cases in that particular study.

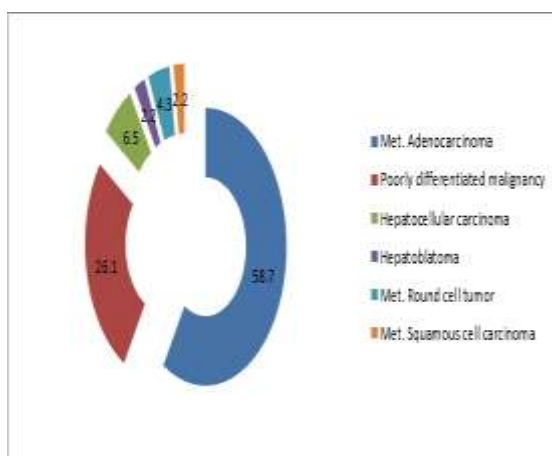
It is seen that a much higher percentage of cases in our series are due to infection. This disparity may represent difference in disease pattern, in this part of the country, or it may be due to referral bias that can be present in studies from tertiary care centres. It should be mentioned that great care was taken into exclude malignancy in cases presenting with a predominant cytological picture of necrosis. Sometimes tumours can undergo extensive necrosis and it becomes difficult to recognize malignant cells.

In our series, high incidence of pyogenic abscess – males being involved more often - can be attributed to large segment of population being involved in agricultural and related manual work and where minor infections are often ignored due to lack of awareness

and poverty. Low immune status due to malnutrition may also be responsible.

The diagnosis of HCC and metastatic carcinoma was based on features now well documented in numerous series<sup>[1,4]</sup>. HCC was diagnosed on following cytomorphological criteria: High cellularity, high N/C ratio, polygonal cells forming thick trabeculae, endothelial cells surrounding trabeculae, capillaries transgressing tumour cell clusters, presence of bile pigment, intranuclear inclusions, atypical naked nuclei and presence of dysplastic hepatocytes. Diagnosis of metastatic adenocarcinoma was based on following criteria: 3-dimensional cell clusters, cell dispersion, cuboidal to columnar cell pattern, cytoplasmic vacuolation, acinar and/or glandular formation, presence of mucin, necrosis, normal appearing hepatocytes and cholangiolar cells. Metastatic squamous cell carcinoma was diagnosed based on presence of squamoid cells, cytoplasmic keratinisation, dense nuclear hyperchromasia, tadpole cells and elongated cells.

As shown in Fig. 6, in our series, patients with metastatic adenocarcinoma formed the largest group of cases (58.7% of cases) amongst malignant lesion of the liver. In 12 patients (26.1% of cases), based solely on cytologic picture, it was not possible to determine the cell of origin. Neither any pointer was available in their clinical history. These cases were classified as poorly differentiated malignant tumour.



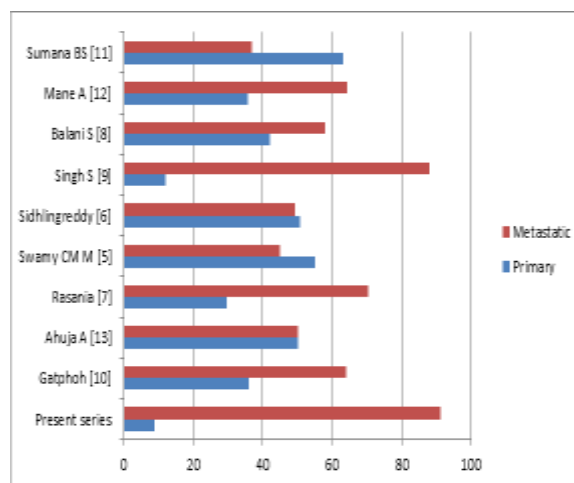
**Fig. 6: Distribution of malignant lesions of the liver in present series (n=46)**

\* Numbers represent percentage in relation to total number of malignant lesions in liver.

They could represent either poorly differentiated HCC or poorly differentiated metastatic lesions. Immunocytochemical analysis – not available in a primary care medical facility – would have clarified this uncertainty. In our series, primary malignancies of liver constitute just 8.7% of the all malignant tumours.

In Fig. 7, distribution of various neoplastic lesions of liver, in studies reported recently from India is

depicted<sup>[5-13]</sup> and compared with our findings. Except for the studies of Swamy<sup>[5]</sup> and Sumana<sup>[11]</sup>, in all other series, metastatic lesions are seen more frequently than primary tumours of the liver<sup>[6,7,8,9,10,12,13]</sup>. However, in our study, these statistics are realized - as has been done in other studies - when poorly differentiated malignancies are included amongst metastatic lesions. Still, when interpreting this data, the caveat mentioned above, regarding possibility of these lesions being poorly differentiated HCC should be kept in mind.



**Fig. 7: Comparison of distribution of primary versus metastatic malignancies in liver\***

\* Numbers represent percentage in relation to total number of malignant lesions in liver.

In conclusion we find that in our series it was possible to provide a diagnosis in 74 out of 83 cases (89.1% of cases) in which guided FNAC was attempted. Amongst these, non-neoplastic, and potentially permanently curable disease was seen in 28 cases. In 46 cases, different types of malignancy were diagnosed. Many of these patients, being in advanced stage of their disease, have poor prognosis. In our set up, palliative medical care may represent a humane and compassionate approach to this group of patients.

#### Acknowledgment

No financial and material support received from any source. No conflict of interest exists.

#### References

1. Ducatman BS. Liver: In Cibas ES, Ducatman BS eds. Cytology - Diagnostic Principles and Clinical Correlates. 4<sup>th</sup> edition 2014; Philadelphia Elsevier Saunders.
2. Tsui WM, Cheng F, Lee Y. Fine needle aspiration cytology of liver tumours. *Ann Contemp Diagn Pathol*. 1998;2:79-93.
3. Mayer J Robert. Tumours of the liver and biliary tree: In Harrison's Principles of Internal Medicine. 18<sup>th</sup> Ed. 2012; New York McGraw Hill Medical. Pg 779.
4. Orell SR and Sterrett GF. *Fine Needle Aspiration Cytology*. 5<sup>th</sup> Ed. 2012; Edinburgh Churchill Livingstone.

5. Swamy M CM, Arathi CA, Kodandaswamy CR. Value of ultrasonography-guided fine needle cytology in the investigative sequence of hepatic lesions with an emphasis on hepatocellular carcinoma. *J Cytol.* 2011;28(4):178-184.
6. Sidhalingreddy, Andola SK. Fine needle aspiration cytology of intra-abdominal lumps *J Clin Diag Res.* 2011;5(3):551-558.
7. Rasanía A, Pandey CL, Joshi N. Evaluation of FNAC in diagnosis of hepatic lesions. *J Cytol.* 2007;24(1): 51-54.
8. Balani S, Malik R, Malik R, Kapoor N. Cytomorphological variables of hepatic malignancies in fine needle aspiration smears with special reference to grading of hepatocellular carcinoma. *J Cytol.* 2013;30(2):116-120.
9. Singh S, Sen R, Kumar S, Gupta S, Chhabbra S, Sangwan M, Lamba S. *Eur J Hepato-Gastroenterology.* 2013;3(1):31-35.
10. Gatphoh ED, Gaytri S, Babina S, Singh AM. Fine needle aspiration cytology of liver: A study of 202 cases. *J Cytol.* 2003;57(3):22-25.
11. Sumana BS, Muniyappa B. Ultrasonography guided fine needle aspiration cytology with preparation of cell blocks in the diagnosis of intra-abdominal masses. *J Clin Diag Res.* 2015 (9)12:8-12.
12. Mane A, Kanetkar SR, Saini S, Saini N. Role of image guided fine needle aspiration cytology in cases of hepatic mass lesions. *Int J Healthcare Biomed Res.* 2015;3(3):149-155.
13. Ahuja A, Gupta N, Srinivasan R, Kalra N, Chawla Y, Rajwanshi A. Differentiation of hepatocellular carcinoma from metastatic carcinoma in liver-Clinical and cytological features. *J Cytol.* 2007;24(3):125-129.