

A clinical, radiological and histological study of jaw lesions from Pathologist's view

Prashant V. Kumavat^{1,*}, Nitin M Gadgil², Hemant Dhusia³, Sushant Agarwal⁴, Sangita S Margam⁵, Chetan S Chaudhari⁶

^{1,5,6}Assistant Professor, ²Associate Professor, ⁴Resident, Dept. of Pathology, ³Professor & HOD, Dept. of Dentistry & Maxillofacial Surgery, LTMMC & LTMGH, Sion, Maharashtra

***Corresponding Author:**

Email: drkumavat_83@rediffmail.com

Abstract

Background: This study was undertaken to correlate the clinical, radiological and histo-morphological features of jaw lesions. The histological problem and limitation was also assessed. Not many studies have been reported from India showing attempt to correlate these findings.

Material and methods: This is 5 years retrospective analysis of the 49 surgically resected or curetted lesions of jaw. Lesions were grouped as cystic, inflammatory, giant cell lesions, non neoplastic and neoplastic based on histological features.

Results: The commonest age group affected was second and third decade (32/ 49 cases). Commonest lesions noted were cystic 23 (46.94%), followed by inflammatory lesions 13 (26.53%). Dentigerous cyst was commonest in cystic lesion with 14 cases (60.87%). Cystic lesions were presented with unilocular radiolucencies. The inflammatory lesions showed characteristic moth eaten appearance. We noted 2 cases (4.08%) each of giant cell lesion and of fibrous dysplasia respectively. Neoplastic lesions were seen in 09 (18.37%) cases and the commonest one were ameloblastoma 3 (33.33%) and osteoma 3 (33.33%).

Conclusion: Lesions of jaw are common in second and third decade with most common is lesion being cystic followed by inflammatory. Clinical-radiological correlation is important for diagnosis of giant cell lesions and cystic lesions.

Keywords: Clinical, Histopathology, Jaw, Lesions, Neoplasm, Radiological.

Access this article online	
Quick Response Code:	Website: www.innovativepublication.com
	DOI: 10.5958/2394-6792.2016.00078.8

Introduction

The jaws are host to a wide variety of cysts and neoplasms, due in large part to the tissues involved in tooth formation. Many benign jaw tumours and several cysts, of both odontogenic and non odontogenic origin, can exhibit a biologically aggressive course and can be diagnostically difficult. Traditional histopathology continues to be the mainstay for the diagnosis of these lesions, as immunohistochemistry and molecular techniques have had, as yet, little impact in this area.^[1]

These lesions present clinically with almost identical, limited symptoms and sign of painless or painful swelling, loosening of tooth, facial deformity and sinus malformation. Radiologically most of the lesions are unilocular or multilocular radio lucencies. Hence, it is helpful in giving differential diagnosis only.

Though, microscopic features are classical in most of the cases, it is difficult to differentiate lesions like, giant cell granuloma and cherubism, infected dentigerous cyst and infected radicular cyst, fibrous dysplasia and ossifying fibroma just on histology alone.

Very few studies have been reported from Asia, particularly from Indian subcontinent.^[2,3] This study was undertaken to know incidence, clinical and radiological presentation of jaw lesions, with histological correlation. Problem areas and limitation of histomorphology in diagnosing jaw lesions were also assessed.

Material and Methods

This is retrospective analysis of the 49 surgically resected or curetted lesion of jaw of 5 years in department of pathology. The lesions of oral cavity-soft tissue and secondary lesions such as squamous cell carcinoma were not included in this study. For each case age, sex, anatomical site and chief associated dental complaints were noted. Radiological finding and provisional clinical diagnosis were also noted.

For ease of understanding, lesions were grouped as cystic, inflammatory, giant cell lesions, non-neoplastic and neoplastic based on histological features.

Results

Out of total 49 cases, 32 (65.31%) cases were found in second and third decade with male to female ratio of 1:1.13 (23/26). Out of total 49 cases of jaw, cystic lesions (46.94%) were most common (Table 1).

Cystic lesions

Dentigerous cysts were commonly noted (14/23 cases) 60.87%. They were common in second decade with male predominance and equal distribution in mandible and maxilla were observed. Impaction,

resorption, or displacements were noted in these cases (Fig. 1). Radicular cysts were more common in third decade and female predominance was noted. All cases were unilocular on radiology with periapices of involved tooth (Fig. 2).

Inflammatory lesions

Inflammatory lesion that was seen in 13 cases was diagnosed as osteomyelitis of Jaw. 9 were females and 4 were males. Mean age was 22.5 years for mandible (11cases) and in maxilla both cases were 12 years.

2 cases of each Giant cells lesion and Non neoplastic lesions were found.

Neoplastic

Neoplastic lesions were seen in 09 (18.37%) cases, which includes 3 (33.33) cases ameloblastoma and osteoma respectively (Table 2). Among all the neoplastic lesions we have not found secondary lesions like invasive squamous cell carcinoma in our study.

All ameloblastoma were arising in mandible and all were present with cortical expansion of both border and displacement of tooth (Table 3).

Cystic lesions presented mainly with unilocular radiolucency (90.48%). Well defined corticated borders were absent in 33 cases. Inflammatory lesions showed characteristic moth eaten appearance (100%) and irregular radiolucent areas (42.85%) (Table 4).

Table 1: Distribution of cases was according to Histological groups

Cysts (23)	Inflammatory (13)	Giant cell (2)	Non neoplastic(2)	Neoplastic (9)
Dentigerous (14)	Osteomyelitis (13)	Giant cell reparative granuloma(1)	Fibrous dysplasia (2)	Cemento- ossifying fibroma(1)
Radicular (9)		Cherubism (1)		Myxoma (2)
				Osteoma (3)
				Ameloblastoma (3)

Table 2: Site, age, and sex distribution of neoplastic lesions

Lesion (cases)	Site	Age	Sex
Cemento- ossifying fibroma (1)	Mandibular premolar	26	M
Myxoma (2 cases)	Mandibular body symphysis	15	F
	Maxilla alveolar bone	22	M
Osteoma (3 cases)	Right mandibular ramus	18	M
	Right mandibular ramus	19	F
	Left mandibular ramus	30	M
Ameloblastoma (3 cases)	Body and angle of mandible	35	M
	Body and angle of mandible	57	M
	Body and angle of mandible	45	M

Table 3: Radiographic features in Ameloblastoma

Finding	Case one	Case two	Case three
Locularity	Unilocular	Multilocular	Multilocular
Site	Right mandible	Left mandible	Right mandible
Impaction of teeth	2 nd molar	Absent	Absent
Cortical expansion of both border	Present	Present	Present
Root resorption	Present	Present	Absent
Displacement of tooth	Present	Present	Present

Table 4: Comparison between main radiological features and Histological groups

Finding	Cystic	Inflam matory	Giant cell	Non neoplastic	Neo plastic	Total
Unilocular	19	-	-	-	2	21
Multilocular	4	-	2	-	4	10
Radioopaque	-	-	-	2	3	5
Moth eaten appearance	-	7	-	-	-	7
Irregular radiolucent areas	-	3	-	-	-	3
Sequestrum formation	-	3	-	-	-	3

No well-defined corticated borders	12	13	2	-	6	33
Displacement of tooth	10	-	2	-	3	15
Resorption of tooth	7	-	2	-	2	11
Impaction of tooth	14	-	-	-	1	15

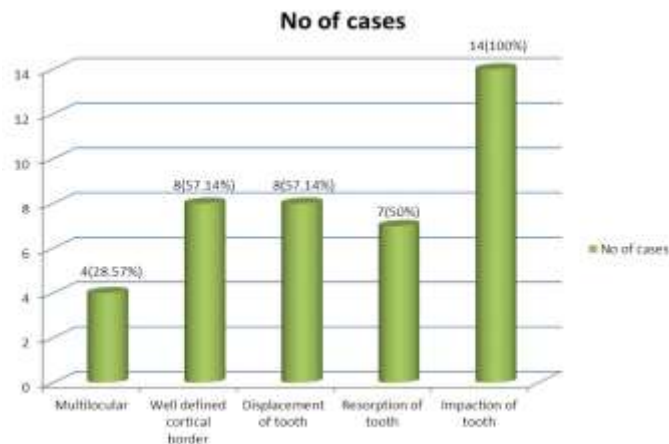


Fig. 1: Radiological finding in dentigerous cyst (14 cases)

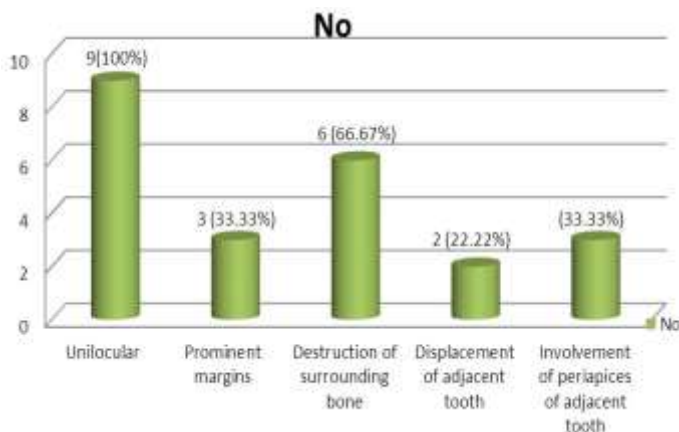


Fig. 2: Radiological finding in radicular cyst (9 cases)

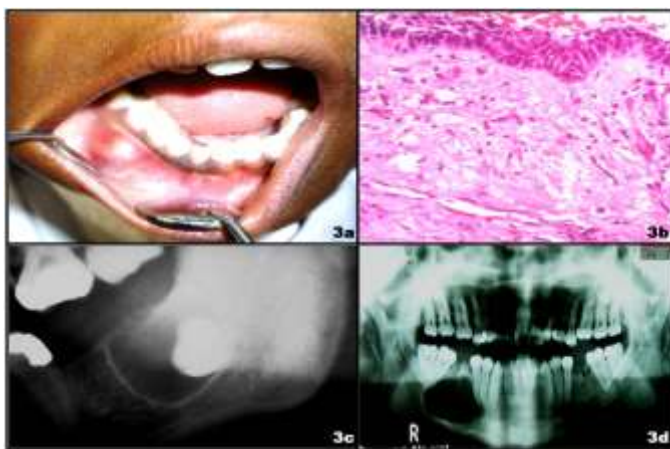


Fig. 3: 3a- Clinical picture of mandibular dentigerous cyst. 3b- Stratified squamous epithelial lining of dentigerous cyst (H and E 400x). 3c -Radiograph of 3a showing unilocular corticated radiolucency around the crown of impacted mandibular tooth. 3d- Radiograph of radicular cyst showing well defined, corticated, unilocular radiolucency

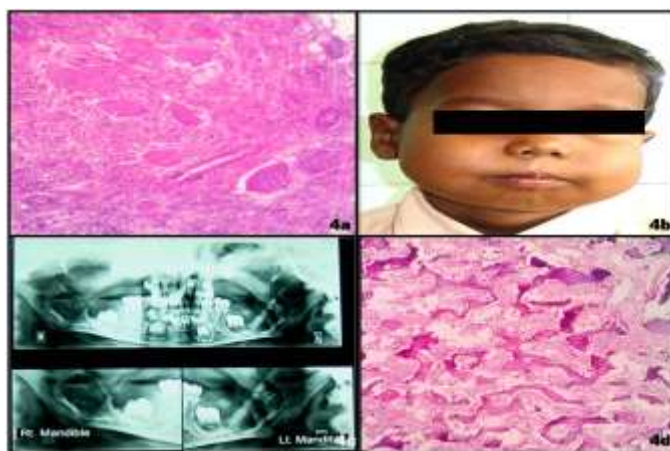


Fig. 4: 4a- GCRG showing evenly distributed regularly shaped giant cells in a cellular stroma (H and E 400x). 4b- Clinical picture of cherubism showing bilateral jaw swelling. 4c – Radiograph of 4b showing bilateral mandibular radiolucencies. 4d- Fibrous dysplasia showing woven bone trabeculae arranged in Chinese script writing pattern (H and E 100x)

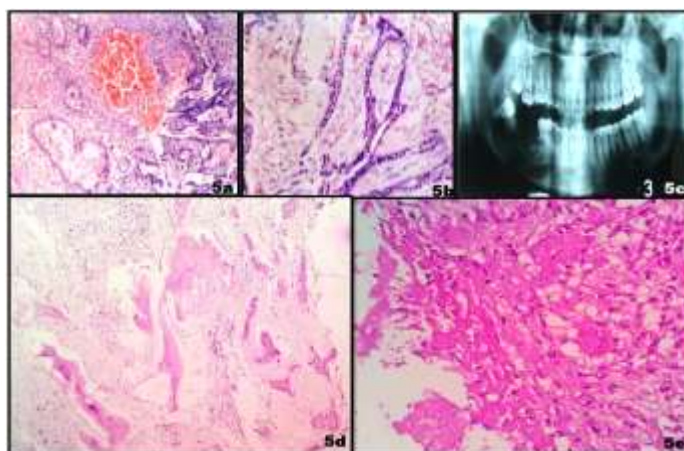


Fig. 5: 5a- Initial biopsy in a case of ameloblastoma showing stratified squamous epithelial lining (H and E100x). 5b- Is the subsequent curette material of same case showing classic plexiform pattern (H and E 400x). 5c- Radiograph of 5a showing multilocular radiolucency in mandibular body with cortical destruction. 5d- Osteomyelitis showing inflammatory infiltrate and trabeculae of dead bone (H and E 400x). 5e- Tuberculous osteomyelitis showing dead bone spicules and prominent Langerhans giant cells (H and E 400x)

Discussion

The study includes 49 cases of jaw lesions exclusive of soft tissue lesions and secondary lesions such as squamous cell carcinoma. In our study, jaw lesions were more common in 2nd and 3rd decade with mean age being 33 years which is similar to Ayaz B et al.^[4] There is slight female predominance in our study, with M: F ratio being 1:1.13, but neoplastic lesions were more common in males.

Cysts

In our study, the most common odontogenic cysts were dentigerous cyst (60.87%) followed by radicular cyst (39.13%) similar to Baghaei in which dentigerous cyst is commonest cyst (27.2%) followed by radicular cyst (18.6%).^[5]

Dentigerous cyst is thought to be developmental origin which encases the crown of a unerupted tooth by development of its follicle and is connected to the neck. It is important that this definition should be applied strictly and diagnosis of this entity should not be done on radiological proof alone because follicular keratocyst, unilocular ameloblastoma involving adjacent unerupted teeth, keratocyst of developmental variety may be misdiagnosed as dentigerous cysts.^[6] In our study, Male to female ratio was 1.3:1 which is similar to reported by Mourshed and Shear.^[7,8] Mandibular 3rd molar (78.57%) was most commonly affected which is also seen in Jones study (73.2%).^[9] 50% of cases occurred in late second and third decade; because this is age period in which 3rd molar is completely developed (Fig. 3a).

Histopathologically they were lined by thin non keratinizing stratified squamous epithelium (Fig. 3b). Cholesterol cleft were found in 3 cases. In two cases, complete ulceration of lining epithelium with presence of granulation tissue and inflammatory infiltrate was present. Radiograph of dentigerous cyst showing unilocular corticated radiolucency around the crown of impacted mandibular with displacement of teeth (Fig. 3c) and uncorticated unilocular radiolucency around crown of mandible premolar, secondarily infected by deciduous molar.

Radiographically resorption of tooth was found in 50% of cases (Fig. 1). This is consistent with observation of Struther, in which 55% of dentigerous cyst appears to have tendency to produce resorption of roots.^[10] All our cases were associated with mature impacted teeth (Fig. 1).

Radicular and residual cyst accounted for 39.13% of the cysts of jaw in our study. The prevalence of radicular cyst ranged from 84.5% in Tortoric to 37.8% in the study of Sharifian.^[11,12]

Radicular cyst arises as result of inflammation from the epithelial residues (cell rests of Malassez) in the periodontal ligament causing death of dental pulp. Cyst arising in this way found mostly in apices of involved teeth. Residual cyst is a radicular cyst which remains behind in the jaw after removal of offending teeth.^[8]

Some private practice-based studies reported a predominance of radicular cyst.^[13,14] Low prevalence of radicular cyst in our study may be because of most of the maxillofacial surgeons don't send periapical inflammatory tissues for histological evaluations associated with the extracted teeth. For diagnosis of radicular cyst is non vital pulp with presence of tooth is required. According to shear et al radicular cyst cases are most common in 3rd, 4th and 5th decade and antrum of maxilla is most common site.^[8] Deciduous teeth is very rarely involves.^[15] Histologically radicular cyst was lined by proliferated stratified squamous epithelium with arcing of basal cells. Fibrous capsule is infiltrated by chronic inflammatory cells, plasma cell being quite conspicuous. Hyaline bodies referred to as Rushton's bodies are found in epithelial lining in 10% of the cases. Cholesterol crystals are present in 28- 50 cases.^[8] Radiographically unilocular radiolucencies around periapices surrounded by narrow radio opaque margin were seen (Fig. 3d). High and Hirschmann showed inverse relationship between cortication of the cyst wall and intensifying acute inflammatory infiltrate.^[16] They also suggested that mean cyst size was also larger in asymptomatic patients. In our study decortication was present in 66.67% cases, though all were infected (Fig. 2). This finding proves above suggestion.

To conclude, only on the basis of histology, distinction between two cysts is difficult and almost impossible when both are secondarily infected. A definitive

diagnosis can be made out only on clinico- radiological correlation.

Giant cell lesions

Giant cell reparative granuloma (GCRG): The giant cell lesions of the jaw, demonstrates variable clinical, behaviour and Histopathological features. There are no useful histopathological criteria to distinguish between giant cell tumour and giant cell reparative granuloma. Therefore broad term giant cell lesion should be applied.

There was, 41 year female presented with pain and blood stained nasal discharge. Histologically, it showed stroma composed of spindle to oval shaped mesenchymal cells with interspersed multinucleated giant cells (Fig. 4a). Prominent stromal cellularity was seen in all section. Areas of haemorrhage and haemosiderin deposition were prominent. The giant cells were evenly distributed, small in size and regular in shape.

Radiograph showed multilocular radiolucent lesion, destruction of maxillary antrum with root absorption and displacement of teeth. Borders were non corticated with root resorption and displacement of teeth.

We have observed and opine that findings of our study regarding the aggressive giant cell lesion matches with the criteria laid by Choung for clinical symptom like pain and radiological features like root resorption or cortical perforation as well as the histological findings of lesion that is small, regular & evenly distributed cells as observed by Whitakar.^(17,18) So we suggest that the designation of giant cell lesions of the jaw as either potentially aggressive or non aggressive may be of more aid to the clinician than to designate these entire lesions as giant cell granuloma.

Cherubism or familial intraosseous fibrous swelling of jaw is an autosomal dominant disorder. An indolent clinical course and symmetrical swellings are characteristic. In Cherubism, bilateral mandibular enlargement may lead to retraction of the facial skin including the lower eyelids, resulting in sclera exposure and the typical "looking toward Heaven" appearance (Fig. 4b).^[19] Histologically loose fibrous connective tissue composed of spindles shaped cells was seen. Rich vascular area with abundant haemorrhage and haemosiderin deposits were found. Giant cells were found scattered more prominent around blood vessels. Radiograph showed multilocular cystic osteolytic lesion expanding from mid body to rami of mandible bilaterally with displaced unerrupted tooth (Fig. 4c).

In our study, histopathological findings were similar to Giant cell regenerative granuloma (GCRG) but clinically patient was 7 year female presented with bony hard painless bilateral mandibular swelling since 2 years. This presentation went in favour of cherubism. It is important to differentiate cherubism from GCRG as its carries a better prognosis. Clinical-radiological

features are important for diagnosis. Histology alone is not sufficient.

Non neoplastic

Fibrous dysplasia: There were 2 cases of fibrous dysplasia, clinically both presented with painless, slowly growing swelling. Histologically 18 year old patient showed richly cellular connective tissue matrix containing numerous plump fusiform cells and considerable intercellular collagen. Fibrous connective tissue was arranged in whorled pattern. Island of irregularly shaped trabeculae of immature woven bone was found arrangement of which gave appearance of Chinese script writing (Fig. 4d). 30 year old patient showed scant cellularity with cells arranged in diffuse manner. Bone component was same as described above except for presence of more mature (lamellar) bony trabeculae at few places suggesting bony component in fibrous dysplasia matures as age of the patient advances. Radiograph showed radio opacities which blended with the adjacent normal bone. Interface was difficult to identify.

Neoplastic

Cemento Ossifying fibroma: Cemento- ossifying fibroma presented with painless swelling involving the molar-premolar region of the mandible which is also seen in Eversole study.^[20] Histopathology showed compact spheroid-curvoid basophilic masses (morphology suggestive of cementum) lying within a hypercellular fibroblastic stroma.

Radiograph showed well defined unilocular radiolucent lesion which on histology showed woven bone, with irregular opacities. Eversole in his study observed that fibrous dysplasia fail to exhibit well demarcated borders radiographically while ossifying fibroma are well demarcated and amenable to surgical enucleation or curettage.^[20]

Myxoma: Myxoma of jaw bones a locally aggressive tumour with high recurrence rate. They occur primarily in young patients with second and third decade which is also seen in our cases (100%).^[21] Histologically polyhedral cells were seen embedded in soft mucinous matrix. Cells had long anastomosing cytoplasmic process with small hyperchromatic nuclei. In one case island of inactive odontogenic epithelium was identified which confirmed the odontogenic origin of myxoma. Radiologically a multilocular radiolucency with thin out and expanded cortex was seen in mandibular case. In maxilla, honey- combed appearance with perforation and destruction of cortical plate and invasion of alveolar bone was seen.

Osteoma: In our study, all patients presented with painless sessile mass. History of trauma was present in all 3 cases. So we can assume that trauma may act as an initiating factor in aetiology of osteoma. Mandible especially on the lingual aspect of the horizontal ramus and lower border of angle are preferred site which is

also seen in our case.^[22] Histologically 2 out of 3 cases showed lamellae of dense bone with small haversian spaces. One case showed mature cancellous bone with lamellar structure. Radiographically radioopaque a well circumscribed sclerotic mass was seen attached to cortical bone by a sessile stalk.

Ameloblastoma– Ameloblastoma appear most commonly in young adults with average age of 35 years and 80% occur in mandible (Table 2).^[23] All patients of ameloblastoma presented with pain with loosening of tooth seen in 2 cases. Egg shell cracking was present in one case.

In first case, biopsy exhibited feature of infected dentigerous cyst, but the diagnosis was suspected due to presence of odontogenic epithelial cell rests (Fig. 5a). Subsequently curette material was received. One bit showed 8-10 cell layer thick lining of stratified squamous epithelium. No continuity was found between this plexiform pattern (Fig. 5b) and lining epithelium. Epithelial cell were columnar with nuclei polarised away from basal lamina. Few places showed follicular pattern with peripheral ameloblast cells and central loose stellate reticulum. Stromal vascularity and areas of fresh haemorrhage were prominent.

Dentigerous cysts have a potential to develop into ameloblastoma, is a controversial subject. But Ackermann in their study of 57 cases could not find evidence that any odontogenic cyst existed prior to development of Ameloblastoma.^[23] According to them much of confusion arises because of following reason, biopsies of ameloblastoma are often taken of an expanded locule lined apparently by a thin layer of epithelium. If surgeon's provisional diagnosis is dentigerous cyst because of radiological picture, the pathologist may well regard such histopathological feature is consistent with diagnosis. When the tumour is removed entirely and a diagnosis of ameloblastoma is made, once again this may be interpreted as having developed from a dentigerous cyst. Considering above reason we stress the need for complete curettage by surgeon and multiple serial sections of surgical specimen by pathologist.

Other two cases showed follicular pattern of ameloblastic cells in fibrous stroma. Cystic degeneration and squamous metaplasia in stellate cells was evident in one case. Stromal vascularity was marked in both cases.

Radiologically they appear multilocular or unilocular lytic lesion with honey comb appearance which also seen in our cases (Fig. 5c).

Inflammatory lesion: Inflammatory lesion that was seen in 13 cases was diagnosed as osteomyelitis of Jaw. Mean age in Paravali study was 44 years, in our study mean age for maxilla was 13 years and mandible was 25.5. ^[24] In Paravali study maxilla is more involved as compared to mandible, similar to our studies. No case was found in infants, both in our and Paravali studies

proves that osteomyelitis is becoming less common in infants because of better antibiotic therapy for dental infections. Male to female ratio was 2.1:1 in Paravali studies. Female predominance in our study was due to increase incidence of anemia and other nutritional disease. In our study, we found odontogenic infection to be major cause of osteomyelitis similar finding was noted by Paravali clinically most of maxillary and mandibular swelling presented with swelling, pain and sequestrum formation. Sinus formation and purulent discharge was seen in 5 cases. Tooth loss was seen in 3 cases and pathological fracture was seen in one case.

Histologically the features are same as that of Osteomyelitis elsewhere in body (Fig. 5d). One case showed tuberculous granuloma (Fig. 5e). Radiologically 3 cases showed irregular radiolucent patches with breaking up of bony trabeculae. Mottled appearance was seen in 7 cases. 3 cases showed involucrum which is surrounding sequestrum.

Conclusion

Jaw lesions are commonly seen in 2nd and 3rd decade of life. Cystic lesions are predominantly seen. Radiologically displacement, resorption, and impaction of tooth are associated with cystic lesions and “moth eaten appearance in inflammatory lesions. Clinico-radiological correlation is important in diagnosis of giant cell lesions like cherubism, giant cell reparative granuloma and giant cell tumour as histology is similar. Radiology alone can differentiate between dentigerous cysts and radicular cysts. Histology is important for diagnosis of neoplastic lesions. Radiologist, clinician and histopathologist should discuss to improve accuracy and reproducibility of above discussed jaw lesions.

Bibliography

1. Regezi J. Odontogenic cysts, odontogenic tumours, fibrous, and giant cell lesions of the jaws. *Modern Pathology*. 2002;15(3):331-41.
2. Varkhede A, Tupkari J, Mandale M, Sardar M. Odontogenic tumors: Review of 60 cases. *J Clin Exp Dent*. 2010;2:e183-186.
3. Gupta B, Ponniah I. The pattern of odontogenic tumors in a government teaching hospital in the southern Indian state of Tamil Nadu. *Oral Surgery, Oral Medicine, Oral Radiology and Endodontology*. 2010;110(1):e32-39.
4. Ayaz B, Zaib N, Mushtaq S, Mamoon N, Akhter N, Abbas S et al. Pathological spectrum of jaw lesions: analysis of 178 cases. *J Pak Dent Assoc*. 2012;21(02):78-84.
5. Baghaei F, Zargaran M, Najmi H, Moghimbeigi A. A clinicopathological study of odontogenic cysts and tumors in Hamadan, Iran. *J Dent (Shiraz)*. 2014;15(4):167-72.
6. Shear M, Speight P. Classification and frequency of cysts of the oral and maxillofacial tissues. In: *Cysts of the oral and maxillofacial regions*. 4th ed. Oxford: Blackwell Munksgaard; 2007. p.1-2,59-76.
7. Mourshed F. A roentgenographic study of dentigerous cysts. Analysis of 180 cases. *Oral Surgery, Oral Medicine, Oral Pathology*. 1964;18:466-73.

8. Shear M, Seward G. *Cysts of the oral regions*. 3rd ed. John Wright: Oxford;1992. p.75-180.
9. Jones A, Craig G, Franklin C. Range and demographics of odontogenic cysts diagnosed in a UK population over a 30-year period. *J Oral Pathol Med*. 2006;35(8):500-507.
10. Struthers P, Shear M. Root resorption by ameloblastoma and cysts of the jaws. *International Journal of Oral Surgery*. 1976;5(3):128-32.
11. Tortorici S, Amodio E, Massenti M, Buzzanca M, Burruano F, Vitale F. Prevalence and distribution of odontogenic cysts in Sicily: 1986-2005. *J Oral Sci*. 2008;50(1):15-18.
12. Sharifian M, Khalili M. Odontogenic cysts: a retrospective study of 1227 cases in an Iranian population from 1987 to 2007. *J Oral Sci*. 2011;53(3):361-367.
13. Prockt A, Schebela C, Maito F, Sant'Ana-Filho M, Rados P. Odontogenic cysts: Analysis of 680 cases in Brazil. *Head and Neck Pathol*. 2008;2(3):150-156.
14. Meningaud J, Oprean N, Pitak-Arnop P, Bertrand J. Odontogenic cysts: a clinical study of 695 cases. *J Oral Sci*. 2006;48(2):59-62.
15. Subramanya P. Radicular Cyst associated with Deciduous Incisor: A Rare Case Report. *IJCPD* 2012;5(3):217-219.
16. High A, Hirschmann P. Symptomatic residual radicular cysts. *J Oral Pathol Med*. 1988;17(2):70-2.
17. Chuong R, Kaban L, Kozakewich H, Perez-Atayde A. Central giant cell lesions of the jaws: A clinicopathological study. *Journal of Oral and Maxillofacial Surgery*. 1986;44(9):708-13.
18. Whitaker S, Waldron C. Central giant cell lesions of the jaws. A clinical, radiologic, and histopathological study. *Oral Surgery, Oral Medicine, Oral Pathology*. 1993;75(2):199-208.
19. Jundt G. Cherubism. In: Barnes L, Eveson J, Reichart P, Sidransky D, editors. *World Health Organization Classification of Tumors; pathology and genetics of tumors of the head and neck tumors*. Lyon: IARC Press;2005.p.325.
20. Eversole L, Leider A, Nelson K. Ossifying fibroma: A clinicopathologic study of sixty-four cases. *Oral Surgery, Oral Medicine, Oral Pathology*. 1985;60(5):505-11.
21. Sivakumar G, Kavitha B, Saraswathi T, Sivapathasundharam B. Odontogenic myxoma of maxilla. *Indian Journal of Dental Research*. 2008;19(1):62-65.
22. Mehta R, Yadav A, Bansal S, Deshpande M. Solitary Periosteal Osteoma of the Mandible: A case report. *Sultan Qaboos University Medical Journal*. 2014;14(1):145-148.
23. Ackermann G, Altini M, Shear M. The unicystic ameloblastoma: A clinicopathological study of 57 cases. *J Oral Pathol Med*. 1988;17(9-10):541-546.
24. Peravali R, Jayade B, Joshi A, Shirganvi M, Bhasker Rao C, Gopalkrishnan K. Osteomyelitis of Maxilla in Poorly Controlled Diabetics in a Rural Indian Population. *Journal of Maxillofacial & Oral Surgery*. 2011;11(1):57-66.