

Cytomorphological spectrum of pediatric head and neck lesions – a comparative study in a tertiary teaching hospital in Western Uttar Pradesh, India

Alok Mohan^{1,*}, Ravindra Kumar Jain², Rajender Kumar Thakral³

¹Associate Professor, ²Professor, Dept. of Pathology, ³Assistant Professor, Dept. of Paediatrics, Muzaffarnagar Medical College & Hospital, Uttar Pradesh

***Corresponding Author:**

Email: dr.alokmohansinha@gmail.com

Abstract

Background: Fine needle aspiration cytology (FNAC) is a well accepted as a diagnostic procedure in adult head and neck lesions. Its use in pediatric population is comparatively new. Only a few studies are available in archives of medical literature in pediatric population.

Aims: The study the cytomorphological spectrum of head and neck lesions in pediatric age group. Histopathological correlation was done wherever possible.

Material and methods: This was a hospital based, prospective type of study. Patients of age group between 0-12 years of age were included. Cases in two years between the time duration from January 2014 to December 2015 were evaluated for head and neck lesions on Cytopathology. Cytomorphological results were compared with other studies. Histopathological correlation was done wherever possible.

Results: FNAC was performed on 1938 patients out of which 215 cases of 0-12 years of age group were included in this study. Cervical lymph nodes were most commonly affected (83.73%). Reactive lymphadenitis followed by granulomatous lymphadenitis was the most common pathology. Second most common site was skin and eyelid. Lesions of salivary glands, soft tissue and thyroid were also encountered.

Histopathological correlation was possible in only 8.33% cases and concordant results were seen in 88.89% cases.

Conclusions: FNAC plays a crucial role in the diagnosis of pediatric head and neck lesions. Preliminary diagnosis can be made and the spectrum of disease can be easily assessed. Histopathology was needed for confirmation of diagnosis in suspicious cases.

Keywords: Fine needle aspiration cytology, Pediatric, Lesions, Cytology, Histopathology

Access this article online	
Quick Response Code:	Website: www.innovativepublication.com
	DOI: 10.5958/2394-6792.2016.00085.5

Introduction

Fine needle aspiration cytology (FNAC) is a rapid and simple technique for diagnosing mass lesions. Its popularity is due to its safety, minimal invasive procedure technique, wonderful patient acceptance and very low morbidity. Lack of sedation or general anesthesia is also a favoring point. Moreover, advanced ancillary techniques such as cell block preparation, immunochemistry, cytogenetic studies, electron microscopy and flow cytometry can be performed on the aspirated material.^[1]

The cytological features are comparable with histopathological features and thus it imparts qualities of micro biopsy.^[2]

The role of Fine needle aspiration cytology in evaluation of mass lesions in adult patients is a well-established early diagnostic method.^[3]

For quite a long time, this technique was hesitantly used in pediatric population which is reflected in the

form of only a few research articles in Indian pediatric literature archives. Earlier reports suggested the utility of FNAC only in a smaller group series of pediatric population.^[4] But now it is also becoming pretty popular in pediatric patients.^[5]

FNAC of head and neck region is well accepted and performed. It has high specificity.^[6]

Medical cost of diagnosis is decreased by FNAC and the process of diagnosis is accelerated. FNAC is a helpful tool for treating clinicians and surgeons in deciding the further line of treatment and management. Selection, guidance and planning the modality of treatment is done on rapid basis.^[7]

Material and Methods

The present study was conducted in the Muzaffarnagar Medical College and Hospital in the department of Pathology between the time duration of two years, i.e. from January 2014 to December 2015. This study was a hospital based study of prospective type. The study was done to evaluate the cytomorphological spectrum of head and neck lesions in pediatric age group and compare the results with other studies on pediatric head and neck lesions.

Patients coming to OPD of the department Pediatrics, Tuberculosis and chest, Surgery and Medicine, who were advised FNAC for their mass

lesion in head and neck region were included in the study.

A brief clinical history of the patients was taken from parents or by him/her self and thorough physical examination of the lesion/lesions was done. Consent was taken from the parents of the children. The patients were made comfortable, swellings made prominent and cleaned with antiseptic solution and FNAC was done aseptically.

Smears were made from the aspirated material and stained with- Geimsa staining, Papanicolaou staining (PAP) and Ziehl Neelsen staining. Histopathology was done wherever possible.

Inclusion criteria

- Palpable mass lesion in head and neck region,
- Patient age between 0-12 years of age.

Exclusion criteria

- Un-palpable lesion,
- Totally unsupportive patient,
- Age more than 12 years of age,
- Lesions of areas other than head and neck region.

Results

FNAC was performed on 1938 cases in two years out of which 215 cases of age 0-12 years were included in the study (11.09%). Out of these, 130 patients were males (60.46%) and 85 were females (39.54%).

Most common site of FNAC was cervical lymph nodes (180), followed by skin (14), salivary gland (08), soft tissue (08) and thyroid (05). Results are tabulated in **Table 1** and **Table 2**.

Table 1: Distribution of Cases in Different Sites- Non-malignant and Malignant lesions

S No.	Site	Number of cases	Non-malignant (inflammatory and benign)	Malignant
1	Lymph node	180 (83.72%)	176	04
2	Skin including eyelids	14(6.52%)	14	00
3	Salivary glands	08(3.72%)	08	00
4	Soft tissue	08(3.72%)	07	01
5	Thyroid	05(2.32%)	05	00
Total		215	210 (97.67%)	05(2.33%)

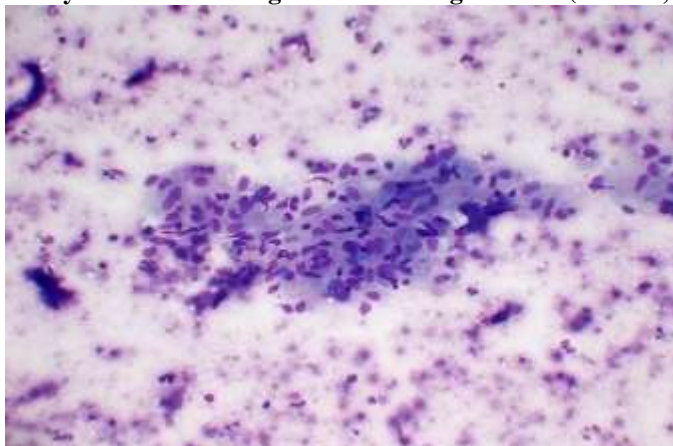
Table 2: Cytomorphological Diagnosis of Lesions at different sites

Site and number of cases	Diagnosis	Number of cases (diagnosis-wise)
Lymph node (180 cases)	Reactive hyperplasia	92
	Granulomatous lymphadenitis	69
	Suppurative	15
	Hodgkin's lymphoma	03
	Non-Hodgkin's lymphoma	01
Skin- eyelid(14 cases)	Vesicluo-bullous lesion	06
	Epidermal cyst	05
	Dermoid cyst	03
Salivary gland(08 cases)	Pleomorphic adenoma	03
	Mucocele	03
	Sialadenosis	02
Soft tissue(08 cases)	Lipoma	03
	Hemangioma	03
	Lymphangioma	01
	Small blue round cell tumour	01
Thyroid(05 cases)	Colloid goiter	04
	Auto-immune thyroiditis	01

Most common finding in cervical lymph nodes was reactive pathology (92/180), followed by granulomatous (69) and suppurative (15) cases.

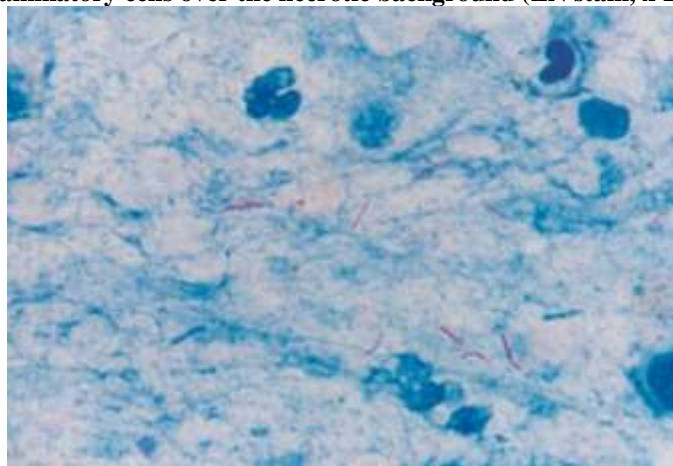
Tubercular lymphadenitis was diagnosed on smears showing epithelioid cell granulomas, lymphocytes, plasma cells and histiocytes over the background revealing necrosis. (**Image 1**)

Image 1: Photomicrograph of cytology smears showing epithelioid cell granulomas, lymphocytes, plasma cells and histiocytes over the background revealing necrosis (Giemsa, x 200)



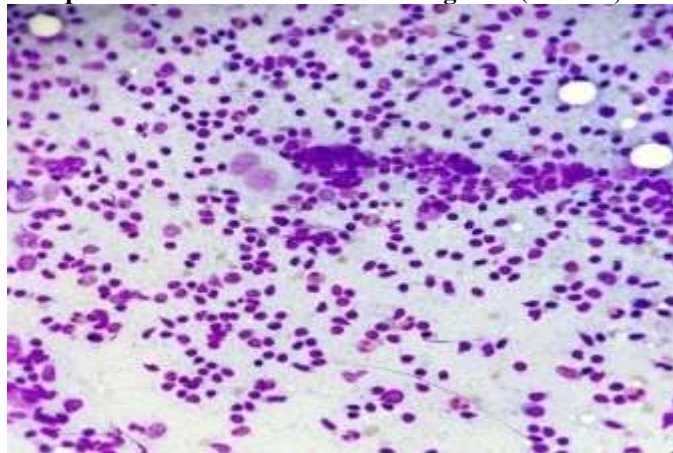
Presence of acid fast bacilli on Ziehl Neelsen (ZN) stain was noticed. Out of 69 cases of granulomatous lymphadenitis AFB was seen in 42 cases (**Image 2**), i.e. 23.3% of cervical lymphadenitis and 60.87% of granulomatous lymphadenitis. In remaining twenty seven cases AFB was not seen.

Image 2: Photomicrograph of cytology revealing acid fast bacilli with degenerated and partly intact inflammatory cells over the necrotic background (ZN stain, x 1000)



Malignant lymphoma was seen in only four cases, out of which three cases were of Hodgkin's lymphoma. Smears of non-Hodgkin's lymphoma revealed mixed population of lymphoid cells along with eosinophils, neutrophils and classical Reed-Sternberg cells. (**Image 3**)

Image 3: Photomicrograph of cytology revealing mixed population of lymphoid cells along with eosinophils, neutrophils and classical Reed-Sternberg cells (Giemsa, x 200)



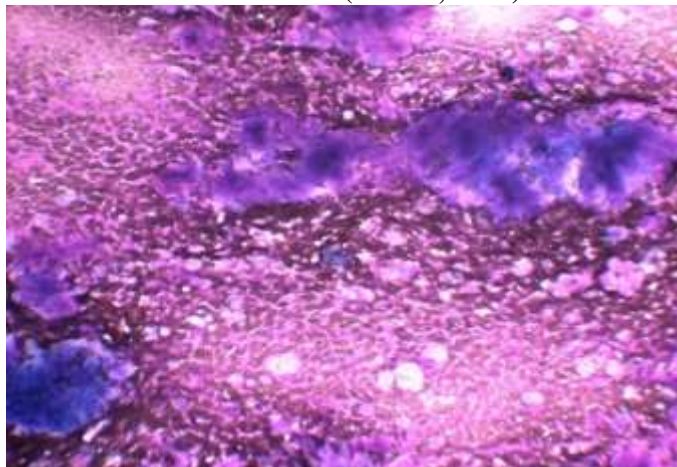
One case was of non-Hodgkin's lymphoma. This was a cellular sample of poorly cohesive monotonous lymphoid population with irregular nuclear membrane and inconspicuous nucleoli.

Skin lesions were vesiculo-bullous lesions (06), epidermal cyst (05), and dermoid cyst (03).

Soft tissue lesions were mainly benign tumours- lipoma, hemangioma, and lymphangioma. One case was of small blue round cell tumour.

Salivary gland lesions included cases of pleomorphic adenoma, mucocele, and sialadenosis. Smears of pleomorphic adenoma revealed epithelial cells both singly, in groups forming acini, strands, cords, sheets etc. along with fibrillary chondromyxoid ground substance. (Image 4)

Image 4: Photomicrograph of cytology showing area of epithelial elements arranged in ducts, tubules, strands, clumps lined by polygonal cells & myoepithelial cells in parotid gland. Fibrochondromyxoid stroma is remarkable. (Giemsa, x 200)



Colloid goiter was the main diagnosis in case of thyroid lesions. One case of autoimmune thyroiditis was also encountered.

Histopathological correlation was possible in only 18 cases out of 215 cases (8.33%). Results were concordant with cytological findings in 16 cases. Two cases which were reported as suppurative lesion were reported as tubercular lesion on histopathology.

Discussion

Head and neck lesions in pediatric age group are mostly benign in nature. Only a few cases are malignant. FNAC has got limited acceptance in pediatric population as compared to adults.^[3,5]

Only a limited number of pediatric studies have been published concerned with FNAC done in head and

neck lesions, lymphadenopathy, soft-tissue lesions, liver and renal lesions.^[8,9,10,11]

In their study, Jain et al reported 6% of unsatisfactory aspirated samples. In our study, repeat FNAC was done in case of unsatisfactory smear. Repeat sampling was done if the primary aspirate was found unsatisfactory on rapid methylene blue stain screening technique. This led to reduction in unsatisfactory sampling to zero percentage. These findings are in concordance with the studies of Taylor et al and S Prathima et al.^[12,13]

Male: Female ratio in our study was 1.52:1 which is concordant with other studies. It was 1.15:1 in study by S Prathima et al.^[13] M: F ratio in study by Handa U et al was 1.5:1.^[14] M: F ratio was 2:1 in study by Maheshwari et al.^[15]

Table 3: Comparison of Various Studies in Pediatric Population

Comparative study	M Jain et al ^[5] (1999)	Handa U et al ^[14] (2003)	Amy Rapackwicz et al ^[1] (2007)	P. Mittra et al ^[7] (2013)	Present study
Total cases	748	692	85	100	215
Age group	0-12	0-14	0-18	0-15	0-12
Sex predominance	Male	M:F 1.5:1	Male (69.4%)	Male (55%)	M:F 1.52:1)
Most common site	Cervical LN(81%)	Cervical LN(84.3%)	Cervical LN(69.4%)	Cervical LN(87%)	Cervical LN(83.72%)
Non-malignant	98.5%	98.46%	83%	88.17%	93.67%
Malignant	1.5%	1.54%	17%	11.83%	2.33%

Malignant lesions in our study were 2.33%. This finding is synchronous with findings of studies by M. Jain and U. Handa.^[5,14]

In the present study, the commonest site of involvement was cervical lymph nodes. This finding is in concordance with various studies. S. Prathima, et al., Shonubi, et al., also reported similar findings.^[13,16]

Cytopathological findings among cervical lymph node lesions were compared (Table 4) with similar studies.

Table 4: Comparison of Studies of Lymph Nodes of Head and Neck Lesions of Children

Comparative study	M Jain et al ^[5] (1999)	Handa U et al ^[14] (2003)	Amy Rapackwicz et al ^[1] (2007)	P. Mittra et al ^[7] (2013)	Present study
Lymph nodes	81%	84.3%	69.4%	87%	83.72%
Reactive hyperplasia	60.6%	63%	66%	42%	51.1%
Granulomatous lymphadenitis	30.5%	25%	15%	55%	38.3%
Suppurative	7.1%	6%	10.1%	2%	8.3%
Hodgkin's lymphoma	2 cases	4 cases	2 cases	03 cases	03 cases
Non-Hodgkin's lymphoma	5 cases	2 cases	3 cases	2 cases	1 case
Lymph nodes	81%	84.3%	69.4%	87%	83.72%

Reactive lymphadenitis followed by granulomatous lymphadenitis is the most common findings. M. Jain, U. Handa, P. Mittra also had similar findings in their studies.^[5,14,7]

In skin and soft tissue lesions our findings were comparable to other studies. We got cases of epidermal inclusion cyst, dermoid cyst, haemangioma and lymphangioma. Amy Rapackwicz found cases of lymphangioma and haemangioma. M Jain^[5] found cases of epidermal inclusion cyst, dermoid cyst, lymphangioma, fibroma and neurofibroma. P. Mittra^[7] found cases of epidermal inclusion cyst, haemangioma and lymphangioma.

Findings in salivary gland lesions were pleomorphic adenoma and sialadenitis. M. Jain^[5] got similar findings.

Colloid goiter was the main finding in thyroid lesions. M. Jain^[5] got similar results. We got one cases of auto-immune thyroiditis. P. Mittra^[7] also got one case of Hashimoto thyroiditis.

Malignant lesions of head and neck region in pediatric population in the present study were 2.33%. M. Jain^[5] and Handa U^[14] also got similar results i.e. 1.5% and 1.54% respectively, while few researchers like Ponder et al^[17] got a higher percentage (5%) of malignant lesions, P. Mittra^[7] got 11.83% and Amy Rapackwicz^[1] got 17%.

Comparison of cytomorphological and histopathological diagnosis was possible in only 8.33% (18/215) cases. The cytological findings were concordant with histopathological findings in 88.89% cases (16/18). In 11.11% cases (2/18) there was discrepancy between cytological and histopathological findings. These findings are correlating with findings of S Prathima et al. They did cyto-histopathological

correlation in 9.4% cases and got concordant results in 81.6% cases.^[13]

Conclusion

FNAC is a safe, easy and reliable method for evaluating pediatric lesions. It is cost-effective and minimal invasive procedure. Results of FNAC in pediatric population are promising. Our study generated results which were concordant to other studies in pediatric population. Histopathological examination is mandatory in suspicious cases.

References

1. Rapkiewics A, Thuy Le B, simsir A, Cangiarella J, Levine P. Spectrum of head and neck lesions diagnosed by fine needle aspiration cytology in the pediatric population. *Cancer*.2007;111:242-51.
2. Steel BL, Schwartz MR, Ibrahim R. Fine needle aspiration biopsy in diagnosis of lymphadenopathy in 1,103 patients. *Acta Cytologica*.1995;39:76-81.
3. Saad RS, Singh HK, Silverman FJ. Fine needle aspiration cytology. In: Orell SR, Sterett GF, editors. *Pediatric Tumors*. 5th ed. New Delhi: Churchill Livingstone Ltd; 2012.pp445-67.
4. Mobley DL, Wakely PE, Frable MAN. Fine needle aspiration biopsy: Application to pediatric head and neck masses. *Laryngoscope*. 1991;101:469-72.
5. Jain M, Majumdar DD, Agarwal K, Basis AS, Choudhury M. FNAC as a diagnostic tool in pediatric head and neck lesions. *Indian pediatr*. 1999;36:921-3.
6. EI Hah IA, Chiedozi LC, alReyees FA, Kollur SM. Fine needle aspiration cytology of head and neck masses. Seven years experience in a secondary care hospital. *Acta Cytol*. 2003;47:387-92.
7. Mittra P, Bharti R, Pandey MK. Role of fine needle aspiration cytology in head and neck lesions of Pediatric age group. *Journal of Clinical and Diagnostic research*.2013 June Vol-7(6):1055-1058.

8. Bakshi P, Srinivasan R, Rao KL, Marwaha RK, Gupta N, Das A, et al. fine needle aspiration biopsy in pediatric space occupying lesions of liver: A retrospective study evaluating its role and diagnostic efficacy. *J Pediatr Surg.* 2006;41:1903-8.
9. Khan RA, Wahab S, Chana RS, Naseem S, Siddique S. Children with significant cervical lymphadenopathy: Clinicopathological analysis and role of fine-needle aspiration in Indian setup. *J Pediatr (Rio J)* 2008;84:499-54.
10. Dey P, Mallik MK, Gupta SK, Vasistha RK. Role of fine needle aspiration cytology in the diagnosis of soft-tissue tumours and tumour-like lesions. *Cytopathology.* 2004;15:32-7.
11. Iyer VK. Role of fine needle aspiration cytology in management of pediatric renal tumors. *J Ind Assn Paediatr.* 2007;12:116-9.
12. Taylor SR, Nunnez C. Fine-needle aspiration biopsy in a pediatric population- Report of 64 consecutive cases. *Cancer.* 1984;54:1449-53.
13. S Prathima, TN Suresh, ML Harendra Kumar, J Krishnappa. Fine needle aspiration cytology in pediatric age group with special references to pediatric tumors: A retrospective study evaluating its diagnostic role and efficacy. *Ann Med Health Sci Res.* 2014 Jan-Feb;4(1):44-47.
14. Handa U, Mohan H, Bal A. Role of fine needle aspiration cytology in evaluation of pediatric lymphadenopathy. *Cytopathology.* 2003;14:66-69.
15. Maheshwari V, Alam K, Jain A, Agarwal S, Chana RS. Diagnostic utility of fine needle aspiration cytology in pediatric tumors. *J Cytol.* 2008;25:45-9.
16. Shonubi AM, Akiode O, Salami BA, Musa AA, Ntele LM. A preliminary report of fine needle aspiration biopsy in superficially accessible lesions in children. *West Afr J Med.* 2004;23:221-3.
17. Ponder TB, Smith D, Ramzy I. Lymphadenopathy in children and adolescents: role of fine-needle aspiration in management. *Cancer Detect Prev.* 2000;24:228-33.