

A study of the internal diameter of popliteal artery, anterior and posterior tibial arteries in cadavers

Anjali Vishwanath Telang^{1,*}, Mangesh Lone², M Natarajan³

¹Assistant Professor, ³Professor, Dept. of Anatomy, Seth GS Medical College, Parel, Mumbai, Maharashtra, ²Assistant Professor, Dept. of Anatomy, LTMMC, Sion, Mumbai, Maharashtra

*Corresponding Author:

Anjali Vishwanath Telang

Assistant Professor, Dept. of Anatomy, Seth GS Medical College, Mumbai, Maharashtra

Email: dranatelang@gmail.com

Abstract

Introduction: Popliteal artery is the continuation of femoral artery at adductor hiatus. It is one of the most common sites for peripheral aneurysms. It is also a common recipient site for above or below knee femoro-popliteal bypass grafts in cases of atherosclerosis. The aim was to study the internal diameter of popliteal artery, anterior tibial and posterior tibial arteries and to compare findings of the current study with previous studies and to find their clinical implications.

Methods: Fifty cadavers (100 lower limbs) embalmed with 10% formalin were utilised in this study.

Results: Internal diameter of popliteal artery was measured at its origin and at its termination. The diameter of popliteal artery at its origin was found to be (mean in mm \pm SD) 4.7 ± 0.9 & at its termination was 4.4 ± 0.7 . The diameter of anterior tibial artery at its origin was 3.5 ± 1.1 & that of posterior tibial artery at its origin was 4.1 ± 0.9 . These findings were compared with the previous studies.

Conclusion: Metric data of internal diameter of popliteal artery, anterior tibial artery & posterior tibial artery from the present study will be of help for vascular surgeons & radiologists.

Keywords: Popliteal artery, Anterior tibial artery, Posterior tibial artery, Internal diameter, Peripheral aneurysm

Access this article online	
Quick Response Code:	Website: www.innovativepublication.com
	DOI: 10.5958/2394-2126.2016.00065.7

Introduction

The popliteal artery is the continuation of the femoral artery from the fifth osseo-aponeurotic opening of adductor magnus to the lower border of popliteus muscle. It descends laterally from the opening in adductor magnus to the femoral inter-condylar fossa, inclining obliquely to the distal border of popliteus, where it divides into the anterior and posterior tibial arteries. This division usually occurs at the proximal end of the asymmetrical crural interosseous space between the wide tibial metaphysis and the slender fibular metaphysis. The artery is relatively tethered at the adductor magnus hiatus and again distally by the fascia related to soleus. The artery may divide into its terminal branches proximal to popliteus, in which case the anterior tibial artery sometimes descends anterior to the muscle.^{1,2,3}

The clinicians and radiologists dealing with the popliteal area use description of branching pattern of the popliteal artery, in which it first gives rise to anterior tibial artery followed by the tibial-peroneal trunk, which

then terminates by dividing into the posterior tibial and peroneal arteries.⁴

As popliteal artery is one of the most common sites for aneurysm formation, the knowledge of the normal popliteal artery diameter is essential to determine the relevance of popliteal dilatations. Considering the clinical importance of diameter of popliteal artery, anterior tibial artery and posterior tibial artery, this study was undertaken to note the internal diameter of popliteal artery, anterior tibial artery & posterior tibial artery.

Methods

Fifty cadavers (100 lower limbs) embalmed with 10% formalin from a medical college located in Western Maharashtra were utilised in this study. All the cadavers were adult males ranging between the age group of 18 - 65 years. None of the limbs showed any evidence of previous surgery. After taking incision, skin was reflected followed by removal of superficial fascia and deep fascia to expose the popliteal fossa. Hamstring muscles were reflected to expose the region of adductor hiatus i.e. origin of popliteal artery and two heads of gastrocnemius were reflected to expose the popliteal vessels. Soleus muscle was dissected vertically up to the termination of popliteal artery. (Fig. 1)

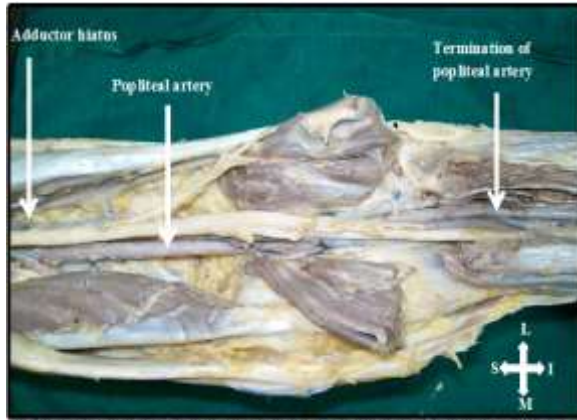


Fig. 1: Illustration showing the exposed popliteal fossa

The following landmarks were exposed:

- Adductor hiatus
- Termination of Popliteal artery

Parameters measured were:

- Inner circumference of popliteal artery at its origin (Fig. 2) and at its termination
- Inner circumference of anterior tibial artery and posterior tibial artery at their origin

At the level of adductor hiatus, intact piece of popliteal artery was removed, incised and cut opened. Inner circumference was measured with the help of divider after fixing the cut opened popliteal artery. The same procedure was followed for measuring circumference of popliteal artery at its termination, origin of anterior tibial and posterior tibial arteries.

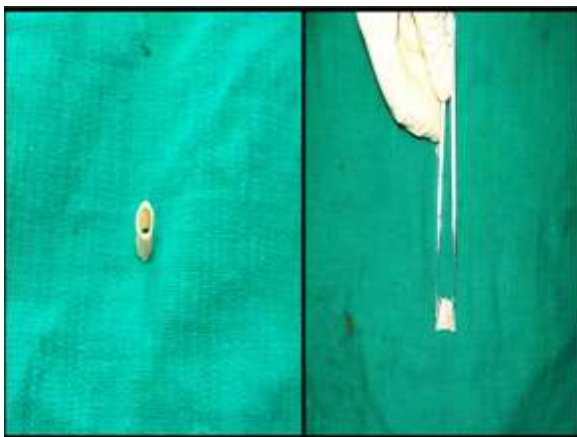


Fig. 2: Illustration showing the measurement of circumferences (from which diameter was calculated) of the popliteal artery at its origin

With the help of following formula internal diameters of these arteries were calculated:

$$\begin{aligned} \text{Circumference} &= 2 \pi r \\ &= \pi d \quad (d= 2r) \end{aligned}$$

$$d = \text{circumference} \div \pi$$

Where, r-radius of artery, d- diameter of artery, $\pi= 3.14$

Results

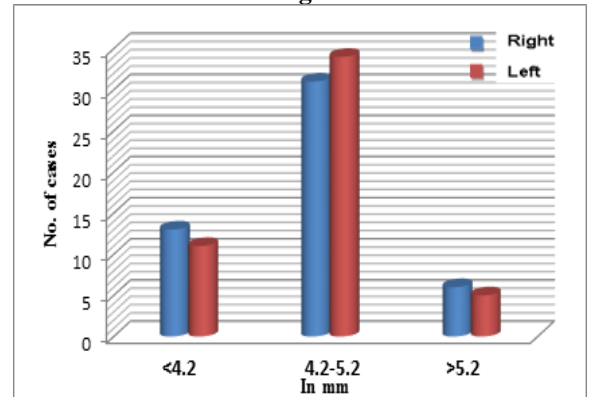
It was found that the mean diameter of popliteal artery at its origin on the right side was 4.7 mm, range being 3.8 mm -5.7 mm and 4.7 mm on the left side, the range being 3.8 mm -5.7 mm. (Graph 1)

The diameter of popliteal artery at its termination on the right side was 4.4 mm, range being 3.8 mm - 5.1 mm and 4.4 mm on the left side, the range being 3.5 mm - 5.4 mm. (Graph 2)

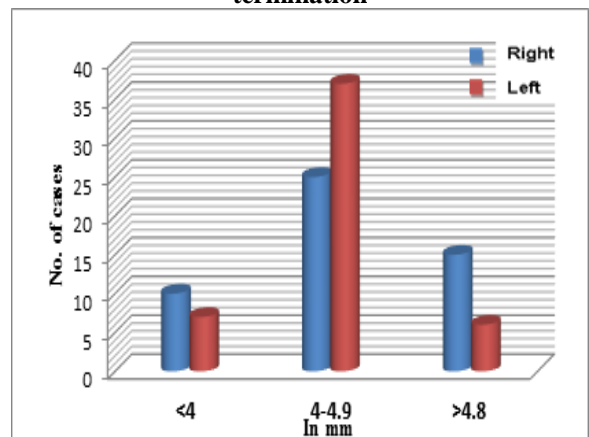
The diameter of anterior tibial artery at its origin on the right side was 3.5 mm, range being 2.5 mm -4.8 mm and 3.5 mm on the left side, the range being 2.5 mm - 4.8 mm. (Graph 3)

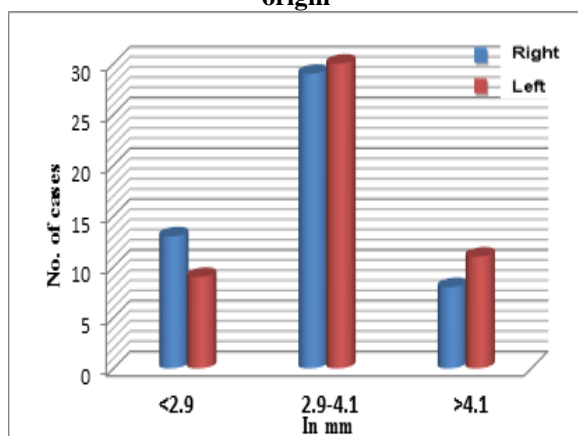
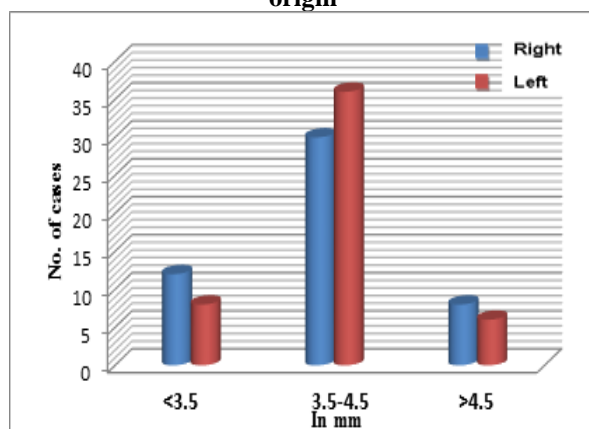
The diameter of posterior tibial artery at its origin on the right side was 4 mm, range being 3. 2 mm - 5.1 mm and 4.1 mm on the left side, the range being 3. 2 mm - 5.1 mm. (Graph 4)

Graph 1: Diameter of the popliteal artery at its origin



Graph 2: Diameter of the popliteal artery at its termination



Graph 3: Diameter of the anterior tibial artery at its origin**Graph 4: Diameter of posterior tibial artery at its origin**

Discussion

Popliteal artery has been an artery of interest for researchers and scientists for a long time. Accurate anatomical knowledge of the popliteal artery and the region of popliteal fossa are of great importance in various diagnostic and therapeutic procedures. Knowledge of morphometric data of popliteal artery is important for infra-popliteal interventions such as bypass surgery, trans-luminal angioplasty and sub intimal angioplasty. Despite improvements in vascular surgical techniques, popliteal vascular injuries and popliteal aneurysms continue to be potentially dangerous lesions with high percentage of leg amputations.^{1,5,6,7}

The anterior tibial artery is an acceptable run-off vessel in femoro-tibial grafting. The patency rate in anterior femoro-tibial bypass is determined by the luminal diameter of the anterior tibial artery.^{8,9,10}

Majority of the studies on the popliteal artery had measured the diameter of the popliteal artery at various points using B-mode ultrasound and Duplex ultrasound scanning methods. There are few cadaveric studies which measured the diameter of the popliteal artery. Thomas Sandgren et al. measured the diameter of the popliteal artery in 121 healthy human volunteers (59 males and 62 females) with echo tracking B-mode ultrasonography and found that the mean diameter of the popliteal artery was $7.4 \text{ mm} \pm 0.9$. They also found that the diameter of the popliteal artery was larger in males as compared to females in > 25 year age group.¹¹

Wolf YG et al. in their study on 204 (104 male and 100 female) healthy volunteers measured the external diameter of the popliteal artery at three levels using Duplex ultrasound scan. They found that the external diameter of the popliteal artery in its upper part was $6.4 \text{ mm} \pm 0.7$, in middle part was $6.4 \text{ mm} \pm 0.7$ and in its distal part was $4.6 \text{ mm} \pm 0.6$. With the help of their findings, they concluded that the diameter of the normal popliteal artery was not uniform throughout its length. In popliteal artery aneurysms, the mid popliteal artery has largest diameter. The mid popliteal artery diameter to superficial femoral artery diameter ratio is greater than normal in popliteal aneurysms.¹²

Crawford et al. in their study on 200 consecutive volunteers without overt vascular disease measured the diameter of the popliteal artery using duplex ultrasound and found that, the mean diameter was 6.7 mm .¹⁰ Zuhail et al. in their cadaveric study on 40 specimens had measured diameter of popliteal artery at various places and found it to be $8.2 \text{ mm} \pm 1.6$ five cm distal to adductor hiatus, $7.5 \text{ mm} \pm 1.3$ at the distal edge of the femoral condyles.¹³

The present study was a cadaveric study, whereas most of the referred studies were done on living subjects. Because of the difference in method of measurement (technique used) and the sample group (cadavers/ living subject) studied, it is expected that there will be some difference in measurements. In the present study, the diameters of popliteal artery at origin and termination were smaller than those noted by previous studies. (Table 1)

Table 1: Showing comparison of mean diameters \pm SD of PA between previous studies with present study

Diameter in mm \pm SD of	Sandgren et al. (B-mode ultrasonography)	Wolf et al. (duplex ultrasound)	Crawford et al. (duplex ultrasound)	Zuhail et al. (Cadaveric study)	Present study (Cadaveric study)
PA (mean)	7.4 ± 0.9	-	6.7	7.8 ± 1.4	-
PA at its origin		6.4 ± 0.7	-	-	4.7 ± 0.9
PA at its termination		4.9 ± 0.6	-	-	4.4 ± 0.7

Note: PA- Popliteal artery

Table 2: Showing comparison of mean diameters± SD of ATA & PTA between previous studies with present study

Diameter in mm ± SD of	Zuhal et al. (Cadaveric study)	Deepali et al. (Cadaveric study)	Present study (Cadaveric study)
ATA at its origin	6.1 ± 1.1	2.82 ± 0.72	3.5 ± 1.1
PTA at its origin	5.7 ± 1.1	1.89 ± 0.67	4.1 ± 0.9

Note: ATA- Anterior Tibial Artery; PTA- Posterior Tibial Artery

Zuhal et al. in their study measured the diameters of anterior tibial artery and posterior tibial arteries at their origin; they referred the posterior tibial artery as tibial-peroneal trunk before origin of its peroneal branch. The diameter of the anterior tibial artery at its origin was 6.1 mm±1.1 and diameter of tibial- peroneal trunk was 5.7 mm±1.1.¹⁴

Deepali et al. in their cadaveric study on 100 specimens measured external diameter of the anterior tibial artery, posterior tibial artery and peroneal artery at their origin by using sliding calipers. The diameter of anterior tibial artery at its origin was 2.82 mm±0.72 (0.282 cm±0.072) and diameter of posterior tibial artery at its origin was 1.89 mm±0.67 (0.189 cm±0.067).¹⁵

The present study measured diameters of anterior tibial artery and posterior tibial artery at their origin and results were compared with previous studies. (Table 2)

Conclusion

The morphometric data from present study will be helpful for vascular surgeons, radiologists. Individuals working with angiography, duplex ultrasound, magnetic resonance angiography and computed tomography angiography should have an insight of the ranges of diameters provided.

Competing interests: None

Acknowledgement

We would like to gratefully acknowledge the support given by Dr. P S Bhuiyan, Professor & Head, Department of Anatomy and the Dean, Seth GS Medical College & KEM Hospital, Mumbai.

References

- Colborn GL, Lumsden AB, Taylor BS, Skandalakis JE. The Surgical Anatomy of the Popliteal Artery. *Am surg.* 1994 Apr;60(4):238-246.
- Richard LM Newell. Pelvic Girdle and Lower Limb (knee). In Gray's Anatomy: The Anatomical Basis of Clinical Practice. Edited by Standring S. 39th edition. Edinburgh: Elsevier Churchill Livingstone, printed in Spain, 2005; p 1471, 1486-1487.
- Datta AK. Essentials of Human Anatomy (Superior and inferior extremities) Part III. 3rd edition. Kolkata. Current Books International. 2007; p 195-197.
- Day CP, Orme R. Popliteal Artery Branching Patterns – An Angiographic Study. *Clin Radiol.* 2006;61(8):696-699.
- Deglise S, Qanadli SD, Rizzo E, Ducrey N, Doenz F, Haller C, Denys A, Corpataux JM. Long-Term Follow-Up Surgically Excluded Popliteal Artery Aneurysms With

- Multislice CT Angiography And Doppler Ultrasound. *Eur Radiol* 2006;16:1323-1330.
- Orcutt MB, Levine BA, Root HD, Sirinek KR. The Continuing Challenge of Popliteal Vascular Injuries. *Am J Surg* 1983;146:758-761.
- Smith PN, Gelinis J, Thain L, Rorabeck CH, Bourne RB. Popliteal Vessels in Knee Surgery. A Magnetic Resonance Imaging Study. *Clin Orthop Relat Res* 1999;367:158-164.
- Kremen AF, Mendez-Fernandez MA, Geis RC, Henly WS. The Dacron EXS graft: patency in Femoropopliteal and femoro-tibial surgery. *J Cardio vasc Surg Torino* 1986;27:125-130.
- Sidawy AN, Menzoian JO, Cantelmo NL, LoGerfo FW. Effect of inflow and outflow sites on the results of tibio-peroneal vein grafts. *Am J Surg* 1986;152:211-214.
- Plecha EJ, Seabrook GR, Bandyk DF, Towne JB. Determinants of successful peroneal artery bypass. *J Vasc Surg* 1993;17:97-106.
- Thomas Sandgren, Björn Sonesson, Asa Ryden Ahlgren, Toste Länne. Factors Predicting the Diameter of the Popliteal Artery in Healthy Humans. *J Vasc Surg.* Aug 1998;28(2):284-289.
- Wolf YG, Kobzantser Z, Zelmanovich L. Size of Normal and Aneurysmal Popliteal Arteries: A Duplex Ultrasound Study. *J Vasc Surg* 2006;43(3):488-492.
- Crawford M, Huber D, Hogg J, Grayndler V, Cooney J, Etheredge S. Normal Popliteal Artery Diameter by Duplex Ultrasound. *J Vasc Tech* 1998;22(1):13-16.
- Zuhal Ozgur, Hulya Ucerler, Z Asli AktanIkiz. Branching Patterns of the Popliteal Artery And Its Clinical Importance. *Surg Radiol Anat* 2009;31:357-362.
- Deepali D, Deshatty, Shubha R. Study of External Diameter of Crural Arteries and Their Clinical Significance. *Journal of Evolution of Medical and Dental Sciences.* Dec 2013;49(2):9539-9547.