

Morphometric analyses of atlas vertebrae- A cross sectional study

Lalitha B^{1,*}, Ephraim Vikram Rao², Shiny Vinila BH³

^{1,2}Assistant Professor, Deccan College of Medical Sciences, Hyderabad, Telangana, ³Senior Lecturer, Dept. of Anatomy, Panineeya Mahavidyalaya Institute of Dental Sciences & Research Centre, Hyderabad, Telangana

***Corresponding Author:**

Lalitha B

Assistant Professor, Dept. of Anatomy, Deccan College of Medical Sciences, Telangana

Email: lalitha.anat@gmail.com

Abstract

Introduction: Knowledge about morphometric measurements related to atlas vertebra are important for neurologists, neurosurgeons and head and neck surgeons who deal with traumatic or non-traumatic conditions which may lead to atlanto-axial and atlanto- occipital instability. The aim of the present study was to assess the various parameters on the atlas vertebra which can help to determine the safe sites for the different surgical approaches.

Materials and Methods: Study was carried out on 50 dry south Indian adult human atlas vertebrae of unknown sex which were collected from the department of anatomy. Eleven parameters were measured for each atlas using a digital vernier caliper.

Results: Range, mean and standard deviations were measured and recorded and bilateral symmetry was observed.

Conclusion: The parameters measured in the present study may help surgeons in avoiding and reducing complications such as vertebral artery injury, spinal cord injury during the surgical corrections of atlanto axial or atlanto occipital instability.

Keywords: Atlas, vertebrae, Atlanto-axial, Atlanto-occipital, Interlaminar clamps.

Access this article online	
Quick Response Code:	Website: www.innovativepublication.com
	DOI: 10.5958/2394-2126.2016.00070.0

Introduction

The atlas is the first cervical vertebra. It consists of two lateral masses which are connected by anterior arch and posterior arch. The two lateral masses consisting of a pair of superior articular facets which articulate with the occipital condyles, and a pair of inferior articular facets which articulate with the superior articular facets of axis vertebra, and transverse processes with foramen transversarium.¹

Atlas vertebra is closely related to the medulla oblongata, which can get compressed by a dislocation of the atlanto-axial complex or instability of atlanto-occipital joint. It is very important to reduce or rebuild the stability of this complex as the vital centers are present in medulla oblongata.^{2,3} Interlaminar clamp, interspinous wiring, plate, screw fixation have been employed as surgical procedures to correct the instability of the atlanto-axial complex or occipito-cervical junction. The instability of this complex may be traumatic or nontraumatic.⁴ Care should be taken to avoid injury to the vertebral artery in its groove. The parameters measured in the present study are useful for the neurosurgeons while performing various procedures in atlanto-axial joint fixation. The parameters on

posterior arch will be guiding to avoid injury to vertebral artery while performing posterior interlaminar clamps and Gallie fusion.⁵ Parametres in relation to lateral mass may help in avoiding injury to vertebral artery in foramen transversarium while performing lateral mass fixation of atlas.⁶ The present study was aimed to find out the incidence of variations in atlas vertebra and to assess the various parameters on the atlas vertebra which can help to determine the safe sites for the different surgical approaches.

Materials and Methods

Study was carried out on 50 dry south Indian adult human atlas vertebrae of unknown sex which were collected from the department of anatomy. Atlases with pathological features and damaged vertebrae were excluded. The following parameters were measured for each atlas using a digital vernier caliper that provides accurate resolution up to 0.01mm.

- A- Width of the atlas (Distance between tips of both transverse processes),
- B- Outer distance of foramen transversarium (Distance between both lateral most edge of the transverse foramen),
- C- Inner distance of foramen transversarium (Distance between both medial most edge of the transverse foramen),
- D- Maximum antero-posterior diameter of vertebral canal,
- E- Maximum Transverse diameter of vertebral canal,
- F- Outer distance of vertebral artery groove, (Distance from mid-point on posterior tubercle to lateral most edge of vertebral artery groove)
- G- Inner distance of vertebral artery groove, (Distance

from mid-point on posterior tubercle to medial most edge of vertebral artery groove)

- H- Length of superior articular facet,
- I- Width of superior articular facet,
- J- Length of inferior articular facet,
- K- Width of inferior articular facet.

Fig. 1A shows the description of parameters

measured on atlas vertebra from the superior aspect. Fig. 1B shows the description of parameters measured on atlas vertebra from the inferior aspect. Three readings were taken for each bone and their average was recorded as the final reading. To control for inter-examiner and intra examiner reliability, each step was performed by a single examiner.

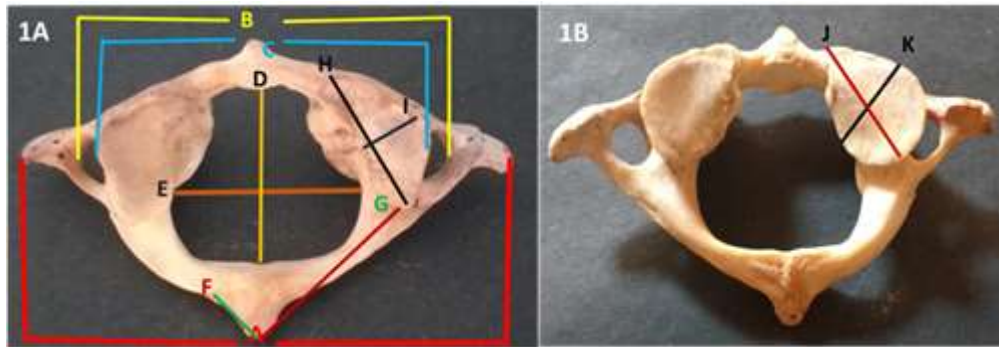


Fig. 1: Showing the parameters –Superior view (1A) Inferior view (1B)

Results

The range, mean and standard deviations of all the parameters were calculated. Data was processed for student t test to check the level of significant difference in right and left sides of parameters F to K. there was no significant difference between right and left sides which shows bilateral symmetry. The range, mean and standard deviations of all the parameters were shown in Table 1.

Table 1: Showing Range, Mean and standard deviations of all the parameters

Letter on illustration	Description of parameter	Range (mm)	Mean & SD (mm)
A	Width of Atlas Vertebra	57.76-87.17	70.25±6.86
B	Outer distance of foramen transversarium	46.74-67.31	54.39±4.73
C	Inner distance of foramen transversarium	37.53-57.88	44.50±4.57
D	Maximum A-P dimension of vertebral canal	23.96-33.83	28.71±2.43
E	Maximum transverse dimension of vertebral canal	17.62-33.40	25.51±2.93
F _R	Outer distance of vertebral artery groove (Right)	20.2-29.23	24.42±1.99
F _L	Outer distance of vertebral artery groove (Left)	19.98-29.61	25.30±2.09
G _R	Inner distance of vertebral artery groove (Right)	7.25-22.61	12.01±3.40
G _L	Inner distance of vertebral artery groove (Left)	8.52-22.51	12.69±3.03
H _R	Length of the superior articular facet (Right)	17.75-27.71	22.47±2.40
H _L	Length of the superior articular facet (Left)	17.9-28.82	22.81±2.44
I _R	Width of superior articular facet (Right)	6.06-12.67	10.10±1.70
I _L	Width of superior articular facet (Left)	5.94-13.97	9.95±3.17
J _R	Length of inferior articular facet (Right)	15.25-22.91	17.99±1.55
J _L	Length of inferior articular facet (Left)	13.85-21.52	17.75±2.07
K _R	Width of inferior articular facet (Right)	11.60-18.49	15.15±1.48
K _L	Width of inferior articular facet (Left)	12.04-17.68	15.01±1.43

Discussion

Occipito-cervical instability may manifest as disabling pain, cranial nerve dysfunction, paralysis, or even sudden death. Stabilization and fusion is required to prevent the complications.⁷ Atlantoaxial complex instability surgically corrected by posterior clamps, posterior wiring techniques, C1-C2 transarticular screw fixation, posterior

C1 lateral mass screw with C2 pedicle screw fixation, and anterior transoral C1 lateral mass to C2 vertebral body fixation.⁸

Table 2: Showing the comparison of present study with other studies

Letter on illustration	Gupta C ⁴ et al., India	Sengül G. and Kadioglu HH ⁹ Turki	Shilpa N G & Vatsalawamy P ³ India	Mohd Salahuddin Ansari et al., ¹⁰ India	Present study South India
A	72.5	74.6±9.7	69.37±6.47	71.98±4.6	70.25±6.86
B	57.6	59.5±3.7	55.66±5.01	58.18±4.26	54.39±4.73
C	45.2	48.6±2.9	45.93±4.22	45.38±3.25	44.50±4.57
D	30.4	46.2±6.0	27.89±2.59	29.44±2.54	28.71±2.43
E	27.7	28.7±1.8	26.89±1.93	27.31±2.74	25.51±2.93
F _R	23.0	16.2±2.5	-	24.85±2.78	24.42±1.99
F _L	22.0	15.8±2.4	-	24.39±2.06	25.30±2.09
G _R	12.8	10.3±1.6	-	10.73±2.92	12.01±3.40
G _L	13.8	10.4±2.0	-	9.72±2.56	12.69±3.03
H _R	21.5	19.9±3.4	21.24±2.39	22.13±2.26	22.47±2.40
H _L	21.8	18.6±3.2	21.02±2.52	21.84±2.11	22.81±2.44
I _R	11.8	9.6±1.9	10.36±1.72	11.82±1.79	10.10±1.70
I _L	11.5	9.8±1.5	10.47±1.61	12.19±1.58	9.95±3.17
J _R	18.0	17.1±2.6	16.57±1.91	16.24±1.44	17.99±1.55
J _L	17.9	17.5±2.4	16.50±1.67	16.67±1.84	17.75±2.07
K _R	14.6	8.8±1.5	14.01±1.93	15.84±1.83	15.15±1.48
K _L	15.2	8.5±1.5	14.42±1.67	16.39±1.93	15.01±1.43

The results of present study show similarity with Gupta C et al., Shilpa N Gosavi & Vatsalawamy P, and Mohd Salahuddin Ansari et al., but differ with Sengül G and Kadioglu HH.^{3,4,9,10} This shows that the vertebral canal is larger in Turkish population than the Indian population. Sengül G and Kadioglu HH reported the mean antero-posterior diameter of vertebral canal (D) as 46.2±6.0 mm, whereas in the present study it was 28.71±2.43 mm. Sengül G and Kadioglu HH reported the mean outer distance of vertebral artery groove (F_R & F_L) as 16.2±2.5 mm on right side and 15.8±2.4 mm on left side which is much smaller than compared to the result of present study where it was 24.42±1.99 mm on right side and 25.30±2.09 mm on left side. The length of superior articular facet and the width of inferior articular facet were smaller in Turkish population compared to Indian population. Sengül G and Kadioglu HH reported the length of superior articular facet as 19.9±3.4 mm on right side and 18.6±3.2 mm on left side where as the present study shows it as 22.47±2.40 mm on right side and 22.81±2.44 mm on left side. Sengül G and Kadioglu HH reported the width of inferior articular facet as 8.8±1.5 mm on right side and 8.5±1.5 mm on left side, whereas in the present study it was 15.15±1.48 mm on right side and 15.01±1.43 mm on left side. These findings show that the morphometry of atlas is ethnic specific.⁷

Conclusion

The different parameters measured in the present study in south Indian adult atlases maybe helpful for the neurosurgeons while dealing with surgical procedures of traumatic neck conditions with interlaminar clamp, interspinous wiring, interspinous plate or screw fixation to avoid injury to vertebral artery and spinal cord.

References

- Williams PL, Warwick R, Dyson M, Bannister LH. Skeletal System. In: Standring S, ed. Gray's Anatomy. 40th Ed., Edinburgh, Churchill Livingstone. 2008;425-736.
- Hanson PB, Montesano PX, Sharkey NA. Anatomic and biochemical assessment of transarticular screw fixation for the atlantoaxial instability. Spine. 1991;16:1141-1145.
- Shilpa N Gosavi, Vatsalawamy P. Morphometric study of the atlas using manual Method. Malaysian Orthopaedic Journal. 2012;6(3):18-20.
- Gupta C, Radhakrishnan P, Palimar V, D' souza AS and Kiruba NL. A quantitative analysis of atlas vertebrae and its abnormalities. J. Morphol. Sci., 2013;30(2):77-81.
- Piplani M L, Singla R K, J S K. Bilateral Arcuate Foramen in a Human Atlas Vertebra - A Case Report. International Journal of Anatomy, Radiology and Surgery. 2013;2(3):3.
- Joaquim AF, Ghizoni E, Rubino PA, Anderle DV, Tedeschi H, Rhoton AL Jr, de Oliveira E. Lateral mass screw fixation of the atlas: surgical technique and anatomy. World Neurosurg. 2010 Aug-Sep;74(2-3):359-62.
- Ihab Zidan, Wael Fouad. Occipitocervical fixation in the management of craniocervical instabilities. Alexandria journal of medicine. 2011;47:185-192.

8. Praveen V. Mummaneni, Regis W. Haid. Atlantoaxial fixation: Overview of all techniques. *Neurology India*. December 2005;53(4):408-415.
9. Sengül G. and Kadioglu HH. Morphometric Anatomy of the Atlas and Axis Vertebrae. *Turkish Neurosurgery*, 2006;16(2):69-76.
10. Mohd Salahuddin Ansari, Mukesh Singla, Kumar Satish Ravi, Prabhat Goel, Raj Kumar. Morphometric Analysis of Atlas and Its Clinical Significance: An Anatomical Study of Indian Human Atlas Vertebrae. *Indian Journal of Neurosurgery*. 2015;4(2):92-97.