

## Diagnosis and treatment of cutaneous sinus of endodontic origin using Cone-beam computed tomography as a confirmatory diagnostic aid

Pallav Mahesh Patni<sup>1,\*</sup>, Pradeep Jain<sup>2</sup>, Hemalatha Hiremath<sup>3</sup>, Rolly Agarwal<sup>4</sup>, Swadheen Raghuwanshi<sup>5</sup>,  
Mona Jain Patni<sup>6</sup>

<sup>1,4</sup>Professor, <sup>2</sup>Professor & Head, <sup>3</sup>Associate Professor, <sup>5</sup>Senior Lecturer, Dept. of Conservative Dentistry & Endodontics, Sri Aurobindo College of Dentistry(SAIMS) & Hospital, Devi Ahilya University, Madhya Pradesh, <sup>6</sup>Consultant Dentist, Dr. Mahesh Chandra Patni Memorial Dental Clinic, Indore, Madhya Pradesh

**\*Corresponding Author:**

Email: pallavpatni@yahoo.com

### Abstract

The cutaneous sinus tract of maxillary dental origin is a rare but, a well-documented condition. However, several non-odontogenic disorders may also produce an extra-oral sinus tract. The diagnosis is a perplexity unless the treating operator considers the occurrence of its dental origin. Such patients may undergo multiple surgical excisions and antibiotic therapy, but the treatment fails with the recurrence of the lesion, because the primary etiology is misdiagnosed. This case report describes a non-surgical endodontic therapy performed in relation with right maxillary first molar (# 16) which was misdiagnosed earlier. The confirmatory diagnosis was made by injection of radio-opaque contrast followed by Cone-beam computed tomography (CBCT) scan. The condition was diagnosed as chronic periradicular abscess with # 16 draining to an extra oral cutaneous sinus tract opening in right malar region. A successful outcome is observed after non-surgical endodontic treatment during follow-up of five years.

**Keywords:** Cone-Beam Computed tomography; Cutaneous Sinus Tract; Non-surgical Endodontics.

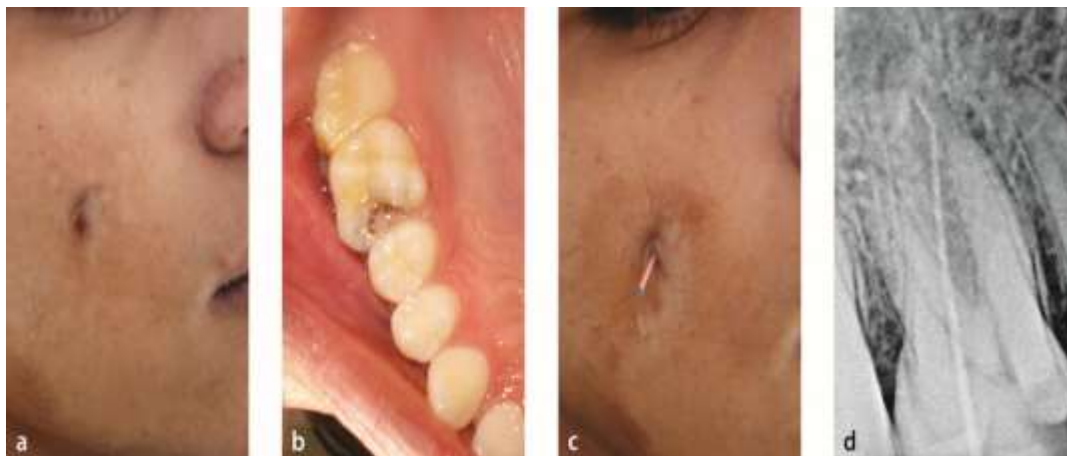### Case Presentation

A 24-year-old male patient was referred to department of endodontics from department of general surgery for an endodontic opinion. His chief complaint was pus discharge from an opening located on right cheek area since past five months. Patient had undergone two surgical excisions and multiple broad antibiotic therapies. Usually such patients are often misdiagnosed and treated by multiple excisional surgeries and broad spectrum antibiotic therapies.<sup>1</sup> Dental history revealed mild discomfort & food lodgment with #16 since past 6 months. Extra oral examination revealed a cutaneous opening of size 4 x 5

mm with a purulent discharge below the right malar region (Fig. 1a).

Intra-orally #16 had deep carious lesion involving the pulp (Fig. 1b). The tooth was non-tender on percussion and had mild pain on palpation with buccal mucosa adjacent to the concerned tooth. Pulp testing (Electric pulp test and heat test using temporary stoppings of gutta-percha) elicited non-responsiveness from the suspected teeth.

A 30 no. standard gutta-percha cone was introduced to trace the sinus tract from the cutaneous opening to confirm radio-graphically if the lesion was odontogenic in origin (Fig. 1c). The tract led to the apex of the palatal root of #16 (Fig. 1d).

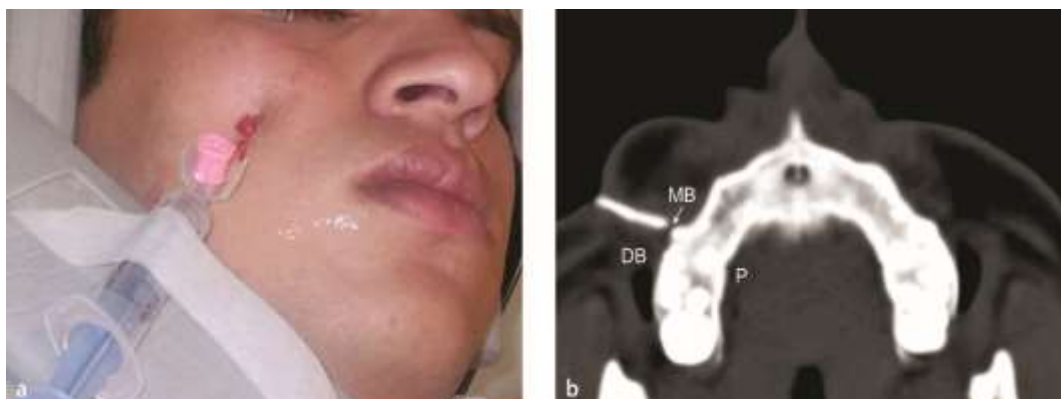


**Fig. 1: Pre-operative photographs and radiographs**

**a. Preoperative photograph revealing a cutaneous opening of size 4 x 5 mm with a purulent discharge below the right malar region**

- b. Intra-oral photograph showing # 16 had deep carious lesion involving the pulp
- c. Photograph showing a 30 no. standard gutta-percha cone introduced to trace the sinus tract from the cutaneous opening
- d. Intra-oral peri apical radiograph (IOPA) revealing that the tract led to the apex of the palatal root of #16

This observation was a bit perplexing as the drainage was from the buccal aspect.<sup>2</sup> There was a possibility that lesion might be because of a different origin and a non-vital tooth was lying in the same region. Hence, a CBCT was planned for a confirmatory diagnosis. A radiopaque contrast 350mg Iodine/ml (Iohexol, GE-Healthcare) was injected in the opening of cutaneous sinus tract after inserting 24 gauge plastic cannula (Wenflon) up-to 5mm into the tract (Fig. 2a). Then a full volume CBCT of maxillary region was taken. Images of CBCT revealed that the contrast was traversing from the external cutaneous surface up-to the alveolus at the site of mesio-buccal root apex of #16 (Fig. 2b). Hence, a confirmatory diagnosis was made of as chronic periradicular abscess with #16 draining to an extra oral cutaneous sinus tract opening in right malar region.



**Fig. 2: CBCT with injection of radio-opaque contrast**

- a. Photograph showing injection of a radiopaque contrast 350mg Iodine/ml in the opening of cutaneous sinus tract after inserting 24 gauge plastic cannula up-to 5mm into the tract
- b. Image of CBCT revealed that the contrast was traversing from the external cutaneous surface up-to the alveolus at the site of mesio-buccal (MB) root apex of #16 (arrow). Disto-buccal (DB) and palatal (P) roots are labelled

Following isolation using a rubber dam, an endodontic access opening was made under magnification and illumination of dental operating microscope (Global Surgical Corporation St. Louis MO, USA) 8x, using an endo-access bur (Dentsply Maillefer, USA) conventional access was prepared with tooth #16. Then, patency was checked using 10 no. K files (Kerr USA), and the working length was determined by using electronic apex locator Root ZX mini (J. Morita MFG. Corporation, Kyoto, Japan) and file in-radiograph (Fig. 3a). The root canals were cleaned and shaped by Rotary Ni- Ti Protaper System (Dentsply Maillefer, USA) along with Glyde (Dentsply Maillefer, USA) using crown down technique. The root canals were copiously irrigated with 5.2% sodium hypochlorite and 17% EDTA solution during the preparation. Following this after irrigating with normal saline final irrigation was done with 2% Chlorhexidine solution (V-concept, Vishal Dentocare, India). Calcium

Hydroxide (Dento Sure Cal, Satendra Polyfrobs, Nashik (MS) India) was placed as an intra-canal medicament and access cavity was temporized with Cavit-G (3M ESPE, USA).<sup>3</sup> Patient was recalled after two weeks. On recall visit, the tooth was asymptomatic and the sinus tract healed completely. Root canals were irrigated again with normal saline & 2% chlorhexidine and dried by using paper points. Tooth #16 was obturated with selected master gutta-percha cones F3 (Protaper, Dentsply Maillefer) and sealer (AH-Plus, Dentsply, Maillefer, USA) (Fig. 3b). The coronal gutta-percha cones were seared off using heated instrument and vertical compaction was done using the heated pluggers at the individual canal orifices. Temporary restoration with Cavit-G was placed. The patient was recalled after one week for post endodontic restorations. Permanent composite restorations were done in the following visit. At the five year follow-up, the patient was comfortable without any symptoms (Fig. 3c).

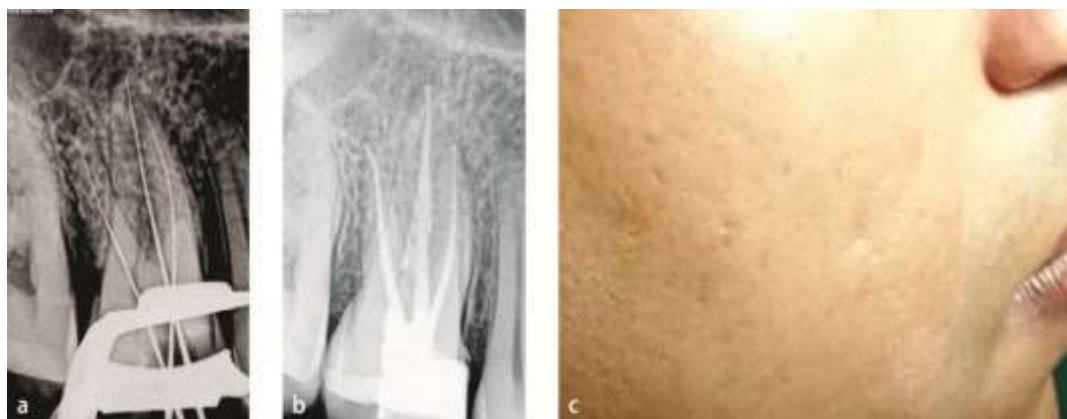

Fig. 3:

- a. Radiograph showing working length determination  
 b. Radiograph showing obturation with tooth #16  
 c. Follow-up photograph after five years showing complete healing of cutaneous lesion

### Discussion

The extra oral cutaneous sinus tract of endodontic origin is frequently misdiagnosed due to wide differential diagnosis. The clinical differential diagnosis includes pustule, actinomycoses, osteomyelitis, oro-cutaneous fistula, neoplasms, carbuncle, infected epidermoid cyst, pyogenic granuloma, chronic tuberculosis, and gumma of tertiary syphilis. Other causes are salivary gland fistula, thyroglossal duct cyst, branchial sinus and suppurative lymph-adenitis. The correct diagnosis of such lesions should be suspected by gross appearance of lesion. They present as erythematous, smooth and non-tender lesions of 1 mm to 20 mm in diameter, with crusty and periodic drainage in most cases. Patient may present with history of dental pain or trauma few years back. Of all such cases, approximately, 80% are mandibular and 20% are maxillary in origin.<sup>4</sup> CBCT is widely used for its better imaging for the confirmatory diagnosis of various lesions of endodontic origin. Hence, CBCT of the involved tooth with injection of radiopaque contrast was planned as done in several medical conditions. This technique can be used as an additional diagnostic aid by all operators. A cross referral between dentist, physician, surgeon and dermatologist should be considered before initiating such cases.<sup>5</sup>

### References

1. Wilson SW, Ward DJ, Burns A. Dental infections masquerading as skin lesions. *Br J Plast Surg* 2001;54(4):358-60.
2. Witherow H, Washan P, Blenkinsopp P. Midline odontogenic infections: a continuing diagnostic problem. *Br J Plast Surg* 2003;56(2):173-75.
3. Sotiropoulos GG, Farmakis ET. Diagnosis and conservative treatment of extraoral submental sinus tract of endodontic origin: a case report. *J Clin Diagn Res* 2014;8(10):10-11.
4. Mittal N, Gupta P. Management of extra oral sinus cases: a clinical dilemma. *J Endod* 2004;30(7):541-47.

5. Patni PM, Jain P, Prashanth MB, Jain N, Patni JM. Non-surgical management of an extraoral cutaneous sinus tract of odontogenic origin: An endodontic challenge. *Endo (Lond Engl)* 2010;4(4):285-91.

How to cite article:

Patni PM, Jain P, Hiremath H, Agarwal R, Raghuvanshi S, Patni MJ. Diagnosis and treatment of cutaneous sinus of endodontic origin using Cone-beam computed tomography as a confirmatory diagnostic aid. *Ind J Conserv Endod* 2016;1(1): 29-31.