

## Variations in the branching pattern of femoral artery in full term human fetuses

Shiny Vinila BH<sup>1</sup>, Lalitha B<sup>2\*</sup>, Sridevi NS<sup>3</sup>, Swetha N<sup>4</sup>

<sup>1</sup>Senior Lecturer, Panineeya Mahavidyalaya Institute of Dental Sciences & Research Centre, Hyderabad, Telangana, <sup>2</sup>Assistant Professor, Deccan College of Medical Sciences, Hyderabad, Telangana, <sup>3</sup>Associate Professor, Sri Devaraj Urs Medical College, Kolar, Karnataka, <sup>4</sup>Tutor, Dept. of Anatomy, Malla Reddy Institute of Medical Sciences, Hyderabad, Telangana

**\*Corresponding Author:**

**Lalitha B**

Assistant Professor, Dept. of Anatomy, Deccan College of Medical Sciences, Telangana

Email: lalitha.anat@gmail.com

### Abstract

**Introduction:** Femoral vessel catheterization is used in neonatal intensive care units for various neonatal health conditions. The present study is to find out the variations in the branching pattern of femoral artery in new born babies which could increase the risk of complications.

**Materials and Methods:** 10 full term dead embalmed fetuses were collected from the Department of Anatomy. Total 20 lower limbs were dissected.

**Results:** Out of 20 extremities 9 showed variations and 11 were normal. Variations observed were – common trunk for superficial circumflex femoral and superficial external pudendal arteries, medial; circumflex femoral artery from femoral artery, common point of origin of medial and lateral circumflex femoral and profunda femoris artery and double femoral artery.

**Conclusion:** The variations found in this study may be helpful to the neonatal and pediatric surgeons while dealing with femoral vessel catheterization.

**Keywords:** Femoral artery, Variations, Catheterization, Profunda femoris, Ischemia

Access this article online	
Quick Response Code:	Website: www.innovativepublication.com
	DOI: 10.5958/2394-2126.2016.00069.4

### Introduction

Femoral vessel catheterization is generally avoided in the neonatal period because of technical difficulties and the fear of complications. Complications from femoral vessel catheterization include transient lower limb ischemia and catheter related bloodstream infection.<sup>1</sup> Femoral artery is a continuation of the external iliac artery. It is a chief artery of the lower limb. It begins at the level of mid inguinal point, passes antero-medially in the thigh and continues as popliteal artery after passing through the adductor hiatus. It gives off 3 superficial branches namely superficial epigastric artery, superficial external pudendal artery, superficial circumflex iliac artery. Deep branches of femoral artery are deep external pudendal artery, profunda femoris artery, descending genicular artery. Profunda femoris further gives off medial and lateral circumflex femoral arteries and perforating arteries.<sup>2</sup> Variations in the branching pattern of femoral artery are commonly observed in adult cadavers.<sup>3-7</sup> Very few studies were carried out in fetuses and new born cadavers.<sup>8,9,10</sup> The proper knowledge of the course and

ramification of femoral artery is very important in full term fetuses because femoral artery catheterization is used while performing various intensive care procedures in neonates and infants.<sup>11,12</sup>

### Materials & Methods

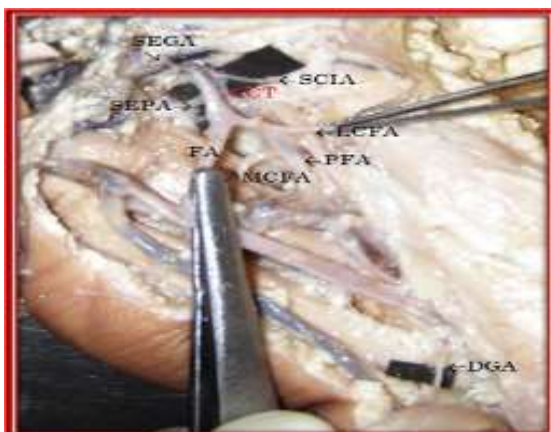
Study sample consisting of 10 full term dead embalmed fetuses which were collected from the department of Obstetrics and gynecology and stored in the Department of Anatomy. Total 20 femoral triangles were dissected and the branches of femoral artery were carefully traced and observed for any variations in the branching pattern of femoral artery. The observed variations were noted and photographs were taken.

### Observations & Results

Among 20 fetal extremities in 9 extremities variations were observed and in 11 extremities normal anatomy was observed.

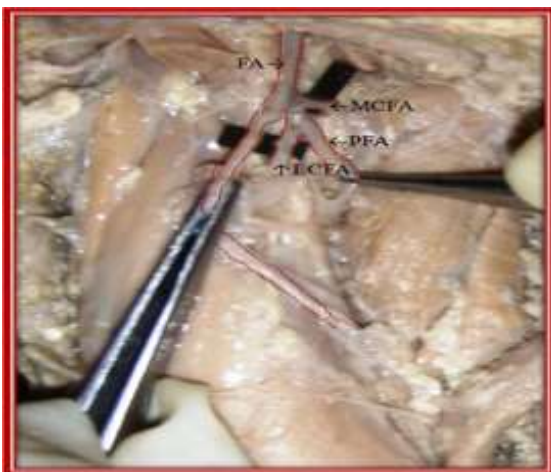
- A common trunk for superficial circumflex iliac and superficial external pudendal arteries were observed in one extremity (5%).(Fig. 1)
- Medial circumflex femoral artery arising directly from femoral artery proximal to the origin of profunda femoris artery was observed in 3 extremities (15%).(Fig. 2)
- Profunda femoris artery, medial and lateral circumflex femoral arteries were arising from a common point on the femoral artery in 3 extremities (15%).(Fig. 3)
- Double femoral artery was in 2 extremities (10%). In 2 extremities medial circumflex femoral and

lateral circumflex femoral arteries were arising from femoral artery and superficial circumflex iliac artery was arising from profunda femoris artery. It was looking like double femoral artery. (Fig. 4)



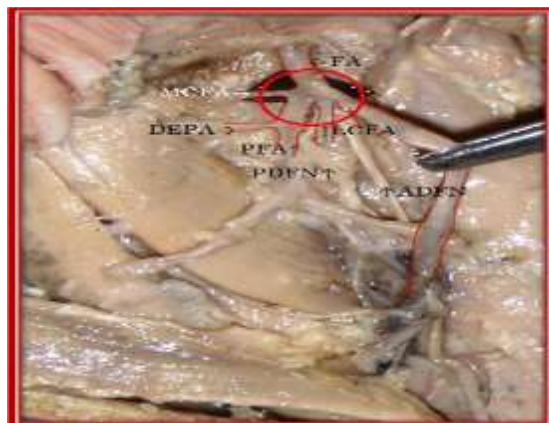
**Fig. 1: Showing SCIA & SEPA arising from a common trunk**

FA – Femoral artery; CT – Common trunk; SEPA– Superficial external pudendal artery; SCIA- Superficial circumflex iliac artery; SEGA–Superficial epigastric artery; DEA - Deep external pudendal artery; PFA – Profund femoris artery; LCFA – Lateral circumflex femoral artery; MCFA – Medial circumflex femoral artery.



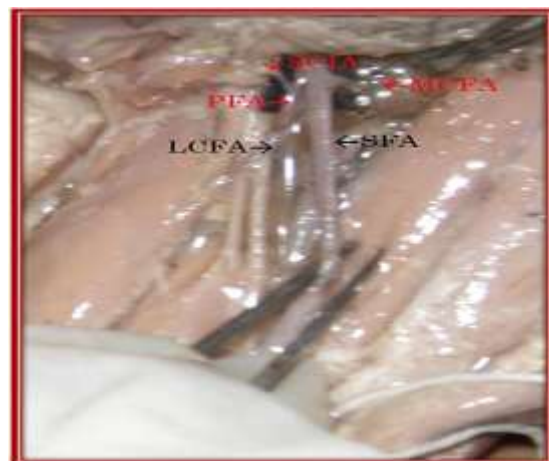**Fig. 2: Showing MCFA arising directly from FA**

FA – Femoral artery; CT – Common trunk; SEPA– Superficial external pudendal artery; SCIA- Superficial circumflex iliac artery; SEGA–Superficial epigastric artery; DEA - Deep external pudendal artery; PFA – Profunda femoris artery; LCFA – Lateral circumflex femoral artery; MCFA – Medial circumflex femoral artery.



**Fig. 3: Common point of origin of MCFA, LCFA & PFA from FA**

FA – Femoral artery; SEPA– Superficial external pudendal artery; SCIA- Superficial circumflex iliac artery; SEGA–Superficial epigastric artery; DEPA - Deep external pudendal artery; PFA – Profunda femoris artery; LCFA – Lateral circumflex femoral artery; MCFA – Medial circumflex femoral artery; PS – Pubic symphysis; ASIS – Anterior superior iliac spine.



**Fig. 4: Showing double FA**

FA – Femoral artery; SEPA– Superficial external pudendal artery; SCIA- Superficial circumflex iliac artery; SEGA–Superficial epigastric artery; DEPA - Deep external pudendal artery; PFA – Profunda femoris artery; LCFA – Lateral circumflex femoral artery; MCFA – Medial circumflex femoral artery; PS – Pubic symphysis; ASIS – Anterior superior iliac spine; IG – Inguinal ligament.

## Discussion

The femoral artery is an end artery, and thromboembolic complications may produce distal ischaemia of the lower limb. Despite these theoretical concerns, the femoral vessels are often used during cardiac catheterization, even in neonates.<sup>13</sup> The present study was carried out to know the anatomical variations in branching pattern of femoral artery in fetuses which

could be one of the cause of post catheterization lower limb ischaemia.

Eswari AK et al., reported that in 80% of cases the branches of profunda femoris artery was normal and in 20% of cases they found the origin of lateral circumflex femoral and medial circumflex femoral artery from the femoral artery.<sup>8</sup>

Our results, which point out that the incidence of variations in the branching pattern of femoral artery was higher on the fetal material when compared with the available literature of adult studies. This may be because the lower extremities of the fetus receive blood via fetal blood circulation during prenatal period where they receive less oxygenated blood that is why they are weakly developed. Their development and elongation is more intensive in the postnatal life, therefore the FA is elongating and thus the beginning of DFA is declining lower in relation to the inguinal ligament. From the very birth until 12 years of age, the lower extremities grow faster than other parts of the body. Only in the 12th year of life the proportion of the parts of body is the same as with the adult person, and it has the particular importance for the clinical practice.<sup>9,14</sup>

Aleksandra et al studied the level of origin of deep femoral artery in fetal material and observed a deviation in high origin of deep femoral artery leading to variance in its lateral branches distribution as well as changes in its caliber, but they have not mentioned about the variations in the branching pattern.<sup>9</sup> Duplication of femoral artery was observed by Sahin et al, according to his observations in one case the proximal femoral artery gave off the medial and lateral circumflex femoral arteries and the distal femoral artery gave off the perforating arteries and in another case the deep femoral artery passing in front of the femoral vein.<sup>10</sup> We observed high origin of medial circumflex femoral artery directly from femoral artery. Medial circumflex femoral artery is the chief artery supplying blood to the head of the femur, the variation we observed in Fig. 2, 3 & 4 shows the origin directly from femoral artery in a higher level. Therefore during cannulation there are chances of damage to medial circumflex femoral artery leading to avascular necrosis of the head of the femur.

### Conclusion

Knowledge of these variations may be helpful to the pediatric, cardiothoracic surgeons to prevent postoperative complications. This study comprised of small sample size but found new variation patterns, so further studies can be carried out with large sample size to find out new branching patterns in full term fetuses.

**Conflict of interest:** None

**Source of fund:** None

### References

1. S P Wardle, A W R Kelsall, C W Yoxall, N V Subhedar. Percutaneous femoral arterial and venous catheterization during neonatal intensive care. Arch Dis Child Fetal Neonatal. 2001;85(2):119-122.
2. Bannister, L.H; Berry, M.M; Collins, P. Gray's Anatomy. In: Cardiovascular system. 38<sup>th</sup> edition. Churchill Livingstone, Medical Division of Longman Group, UK Ltd. 1995:1566-8.
3. Rajani SJ, Ravat MK, Rajani JK, Bhedi AN. Cadaveric Study of Profunda femoris artery with some unique variations. J Clin Diagn Res. 2015;9(5):AC01-3.
4. Waseem Al-Talalwah. The medial circumflex femoral artery origin variability and its radiological and surgical intervention significance. Springer plus. 2015;28(4):149.
5. Manjappa T, Prasanna LC. Anatomical variations of the profunda femoris artery and its branches-a cadaveric study in South Indian population. Indian J Surg. 2014;76(4):288-92.
6. Shiny Vinila BH, Suseelamma D, Sridevi NS, Gayatri N, Sangeeta M. A study on the origins of medial circumflex femoral artery. Journal of dental and medical sciences. 2013;4(5):28-31.
7. Nasr AY, Badawoud MH, Al-Hayani AA, Hussein AM. Origin of profunda femoris artery and its circumflex femoral branches: anatomical variations and clinical significance. Folia Morphol (Warsz). 2014;73(1):58-67.
8. Eswari AK, Hemanth Kommuru, Satyalakshimi V, Swayam Jothi S. Profunda femoris artery and its branching pattern and variations. International Journal of Anatomical Sciences, 2013;4(1):03-08.
9. Aleksandra Vuksanovic Bozanic, Natalija Stefanovic, Snezana Pavlovic, Ratomic Duraskovic, Jovan Ramdelovic. Analysis of deep femoral artery origin variances on fetal material. 2007;14(3):112-116.
10. B Sahi, S Bilgic. Two rare arterial variations of the deep femoral artery in the new born. Surgical Radiological Anatomy. 1998;20:233-235.
11. Dumond AA, da Cruz E, Almodovar MC, Friesen RH. Femoral artery catheterization in neonates and infants. Pediatr Crit Care Med. 2012;13(1):39-41.
12. Asnes RS, Arender GM. Septic arthritis of the hip: a complication of femoral venipuncture. Pediatrics 1966;38:837-41.
13. Rosenthal A, Anderson M, Thomson SJ, et al. Superficial femoral artery cannulation. American Journal of Disease of Children 1972;124:240-2.
14. Natale A, Belcastro M, Palleschi A, Baldi I: The Mid - Distal Deep Femoral Artery: Few Important Centimeters in Vascular Surgery. Annals of Vascular Surgery 2007;21(1):111-6.