

Anatomical correlation of undescended testes

Shubha Srivastava^{1,*}, Kuldeep Singh²

¹Associate Professor, Muzaffarnagar Medical College, Uttar Pradesh, ²Professor, Dept. of Anatomy, Govt. Medical College, Azamgarh

***Corresponding Author:**

Shubha Srivastava

Associate Professor, Dept. of Anatomy, Muzaffarnagar Medical College, Uttar Pradesh

Email: dr_kuldeep68@yahoo.com

Abstract

Undescended testes are a very common congenital anomaly in India. It is clinical as well as psychological problem for the boys. For the study of location of undescended testes, anatomy of descent of testes is necessary. Ultrasonography is important tool for this study. Patients above the age of six months with history of absent testes in the scrotum either unilateral or bilateral were included in the study. The descent is depends on many factors with gubernaculum playing major role. Ultrasound is the standard imaging technique of choice in children with a non-palpable testis as it is non-invasive and does not use ionizing radiation. Location of testis is also important in deciding whether patient will need abdominal or inguinal surgery. The aim of study, the position of undescended testis by high frequency ultrasound and its anatomical explanation. Total 212 boys with undescended testis were examined by high frequency ultrasound the prevalence was more on right side (104 out of 212), where testis was found located in the inguinal canal. In present study we find that the undescended testes more prevalent on right side and in inguinal region.

Keywords: Testes, Undescended, Gubernaculum.

Access this article online	
Quick Response Code:	Website: www.innovativepublication.com
	DOI: 10.5958/2394-2126.2016.00084.0

Introduction

Undescended testis is very prone to the low fertility and high rate of occurrence of neoplasm locating them at the earliest is important. Incidence is around 0.8- 2% in full term new born and around 18-30% in premature births (Güvenç et al; 2005)¹. About two thirds of cases without other abnormalities are unilateral; one third involves both testes.

The term cryptorchidism, described from the Greek words 'Kryptos' meaning 'hidden' and 'orchis' meaning testicle, it is the absence of one or both testis from the scrotum².

Undescended testes are associated with and psychological problems when the boy is grown. Wooddescribedan undescended testicle will usually descend during the first year of life, but to reduce these risks, undescended testes can be brought into the scrotum by a surgical procedure³.

The descent of the testes consists of the opening of a connection from the testis from abdomen to its final location in scrotum with the development of the gubernaculum, which subsequently pulls and translocates the testis down into the developing

scrotum. Ultimately, the passageway closes behind the testis.

Material & Method

Total 212 boys above the age 6 month referred from clinical diagnosis of undescended testes were subjected to high frequency ultrasound by linear broadband transducer of frequency 7.5-10 MHz on GE Voluson 8 Core vision ultrasound machine in Dr. O.P. Gupta Imaging Center, Baccha Park, Meerut, Uttar Pradesh. The aim of examination was to locate undescended testis in inguinal region and/or pelvis. The location of testis was noted followed by its size, texture & vascularity. If necessary palpable examination was conducted.

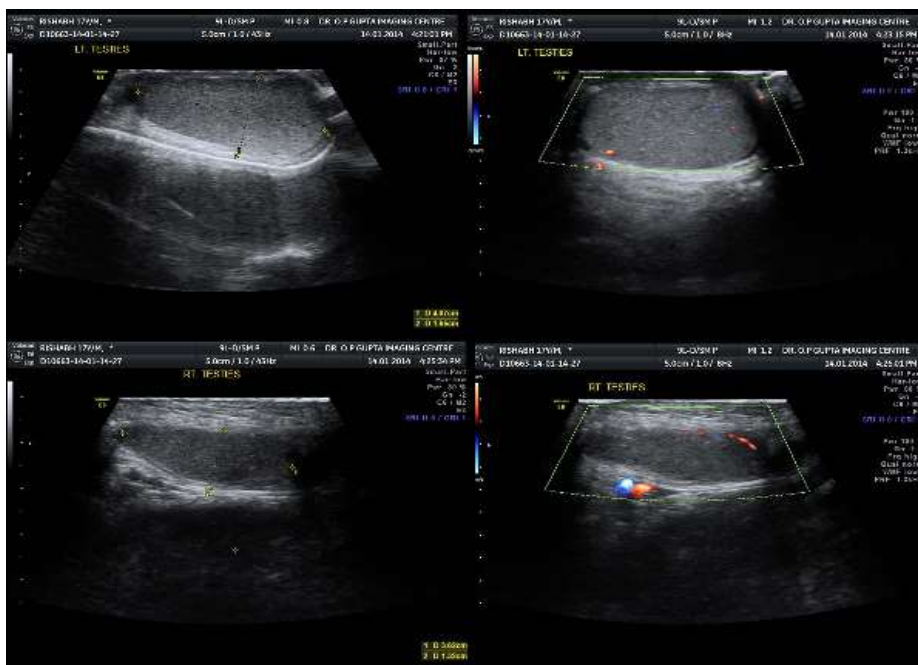
Results

Total 212 patients were studied the age group above 06 months. In 212 patients 176 (83%) patients had unilateral undescended testes and 36 bilateral. In unilateral undescended testes prevalence was observed more on right side i.e. 104 (58%) and 72 (42%) on left side. Ultrasound localized the position of testes more in the inguinal canal some in abdomen and few testes were not be localized. Out of 212 undescended testes 192 (90%) in the inguinal canal, 08 in abdomen and 12 was not localized.

Most of undescended testes between the age of 04 year were smaller and size and with low vascularity in comparison to normal testis. In one undescended testes which was present in inguinal canal having carcinoma on lower pole. Table 1 is showing the results of prevalence of undescended testes.

Table 1: Side of undescended testes

Side	No. of Patients	Percentage
Right	104	49
Left	72	34
Bilateral	36	17
Total	212	100

**Loft testes normal in size & vascularity. Right undescended testes smaller in size and less vascular**

Discussion

Schoen wolf describes⁴ descent of the testis require two phases trans-abdominal and inguinal phase. During the descent of testes Gubernaculum plays important role. Gubernaculum is a mesenchymal bend attached from lower pole of testes to the scrotum. Gubernaculum starts condenses during 7th week during trans-abdominal phase between 7th and 12th week the gubernaculum shortens and pulls the testis down to the proximally to deep inguinal ring. Inguino-scrotal phase starts during the 3rd to 7th month and testes remains near the inguinal canal and then enters the inguinal canal. During 9th month of intra uterine life testis have completely entered the scrotal sac⁴. During the growth of the fetus Leydig cells secrete insulin 3 stimulate gubernaculum enlargement augmented by MIS (mullerian inhibiting substance) and T (testosterone) which also causes regression of cranial suspensory ligament (CSL)⁵.

Genitofemoral nerve (GFN) and calcitonin-Gen Related-peptide (CGRP) are also important factors for gubernaculum through androgen in the inguinoscrotal phase. Insufficient testosterone during development may result in failure to produce enough nerve cells in the genitofemoral nerve; then at the time of testicular migration too little CGRP is produced than required to

stimulate contractions in the gubernaculum and assist testicular descent (Park & Hutson)⁶. The gubernaculum gives rise to both smooth and striated muscles. Failure of descent is associated with the diminution of smooth muscle content and decrease in sympathetic tone that depends on androgens⁷. Normal testicular descent is dependent on the intact hypothalamus-pituitary axis. Malformations of CNS and congenital hypogonadotropic hypogonadism may be associated with cryptorchidism⁸. So the descent of testes is a complex process which also requires optimum temperature and HCG of mother.

In 2007 according to Sinha *et al*⁹ of the 250 cases under study 202 (80.8%) were unilateral in that cases of right sided undescended testis were 110 (54.5%) and 92 (45.5%) cases of left sided undescended testis and 48 (19.2%) cases of bilateral undescended testis were present.

According to Christofer (2008)¹⁰, the right testis is affected in 50% of cases, the left testis is affected in 30% of cases, and double arrest occurs in 20% of cases.

According to Ajmer (1989)¹¹, he studied 313 cases of undescended testis the right testis is affected in 119 (39%) of cases, the left testis is affected in 92 (30%) of cases, and double arrest occurs in 51 (31%) cases In all the above studies right sided undescended testes is more

common than left sided undescended testes and bilateral undescended testes are less in number. In the present study also maximum cases were of right sided undescended testes.

Onkar et al (2012)¹² out of 41, 25 had unilateral and 8 had bilateral undescended testis. Incidence was observed more on right side. (60%). Unilateral undescended testis is more likely to occur because androgens act independently on each side via the ipsilateral genitofemoral nerve and defects in neuronal development of CGRP action could lead to unilateral undescended testis (Hutson & Hasthorpe)⁵.

Agrawal et al (2013)¹³ studied, the side on which undescended testis get arrested during its descent, more frequently on right side. In 43 undescended testis 21 (48.8%) cases of right sided undescended testis, 16 (37.2%) cases of left sided undescended testis and 6 (14%) cases of bilateral undescended testis.

Nijs et al. (2007)¹⁴ studied 103 non-palpable testes by high frequency ultrasound and out of 87, 85 (97%) inguinal.

Onkaret al¹¹ studied that out of 46 testes located by ultrasound 5(10%) were retractile, out of remaining 41, 26 (63%) were in inguinal canal, 15 (37%) were located in abdomen. Luciano (2003)¹⁵ studied 133 cryptorchid testes and found 17 (12%) abdominal, 92 (69%) inguinal, 24 (18%) high scrotal.

In our study out of 212 undescended testis 104 (49%) on right side and 72 (34%) on left side and 36 (17%) bilateral. Out of 212, 192 was in inguinal canal (90%) and 8 in abdomen and 12 not located. As shown in figure the undescended testis is smaller in size and less vascular as compare to normal testes.

In this study the most of cases were recorded above six months of age. In the present study we concluded that the knowledge of descent of testes is needed because arrest of descent may be at any place. So surgeons and pediatricians require anatomy of descent of testes for surgery. Right sided undescended testis is more common then left and location of undescended testes mostly in inguinal canal.

References

1. Güvenç, B. H.; Sözübir, S.; Ekingen, G. & Senel, U. Advantages of video-assisted approach in detecting epididymal anomalies and treatment of non palpable testis. *Urol. Int.*,74(2):127-34,2005.
2. Tomiyama, H.; Sasaki, Y.; Huynh, J.; Yong, E.; Ting, A. & Hutson, J. M. Testicular descent, cryptorchidism and inguinal hernia: the Melbourne perspective. *J. Pediatr. Urol.*,1(1):11-25,2005.
3. Wood, HM, Elder JS (February 2009). "Cryptorchidism and testicular cancer: separating fact from fiction" *The Journal of urology*181(2):452-61.
4. Schoenwolf, G. C.; Bleyl, S. B.; Brauer, P. R. & Francis-West, P. H. *Larsen's Human Embryology*. 4th ed. New York, Churchill Livingstone, 2009. Pp.26-530.
5. Hutson, J. M. & Hasthorpe, S. Testicular descent and cryptorchidism: the state of the art in 2004. *J. Pediatr. Surg.*,40(2):297-302,2005.

6. Park, W. H. & Hutson, J. M. The gubernaculum shows rhythmic contractility and active movement during testicular descent. *J. Pediatr. Surg.*,26(5):615-7,1991.
7. Tanyel, F. C. The descent of testis and reason for failed descent. *Turk. J. Pediatr.*, 46(Suppl.):7-17, 2004.
8. Virtanen, H. E.; Bjerknes, R.; Cortes, D.; Jorgensen, N.; Rajpert- De Meyts, E.; Thorsson, A. V.; Thorup, J. & Main, K. M. Cryptorchidism: classification, prevalence and long-term consequences. *Acta Paediatr.*,96(5):611-6,2007.
9. C K Sinha, et al, Delayed diagnosis for undescended testis. *Indian Pediatrics* 2008;45.
10. Christopher G Fowler Testis and Scrotum. Bailey and love's Short Practice of Surgery. 2008;25(75):1377-1380
11. Ajmer Singh. Undescended testis. *Ann R Coll Surg.* 1989;80(1):69-71.
12. Onkar et al, study of undescended testes by high frequency ultrasound Int. J. Morphol,30(3):1085-1089,2012.
13. Agrawal et al, study and management of undescended testes. *IJBAR* (2013) 04 (11).
14. Nijs, S. M.; Eijsbouts, S. W.; Madern, G. C.; Leyman, P. M.; Lequin, M. H. & Hazebroek, F. W. Nonpalpable testes: is there a relationship between ultrasonographic and operative findings? *Pediatr. Radiol.*,37(4):374-9,2007.
15. Favorito, L. A.; Klojda, C. A.; Costa, W. S. & Sampaio, F. J. Is there a relationship with anomalous insertions of the distal gubernaculum testis and testicular ectopia? Analysis in human fetuses and patients with cryptorchidism. *J. Urol.*, 170(2 Pt1):554-7, 2003.