



# Indian Journal of Pathology and Oncology

ISSN 2394-6784(Print)  
e-ISSN 2394-6792(Online)

# IJPO

## SARCOIDOSIS OF BILATERAL PAROTID GLAND - DIAGNOSED ON FINE NEEDLE ASPIRATION CYTOLOGY

Vartak Shailesh<sup>1</sup>, Anitha Padmanabhan<sup>2</sup>, Ranbir Singh<sup>3,\*</sup>, Urmi Chakravarty Vartak<sup>4</sup>

<sup>1,4</sup>Associate Professor, <sup>2</sup>Assistant Professor, <sup>3</sup>MD Pathology, Department Of Pathology, Lokamanya Tikal Municipal Medical College and Municipal General Hospital, SION, Mumbai - 400022, India.

**\*Corresponding Author:**

E-mail: ranbir.s.chawla86@gmail.com

**Abstract:** A case of Sarcoidosis, presented initially as bilateral parotid gland enlargement and diagnosed on FNAC is discussed here. Smears showed noncaseating epithelioid cell granulomas and few atrophic salivary gland acini. AFB staining of the aspirate smears were negative and no caseous necrosis was seen. After excluding other granulomatous lesions, a differential diagnosis of Tuberculosis and sarcoidosis was suggested. The Serum ACE levels were elevated and x ray chest showed hilar lymphadenopathy. The patient also had xerostomia and xerophthalmia of right eye. The diagnosis of Sarcoidosis was confirmed based on these findings. FNAC, therefore, may be considered a useful diagnostic modality in cases of sarcoidosis presenting primarily with parotid involvement.

**Key words:** Bilateral parotid gland, FNAC, Sarcoidosis.

### Introduction

Sarcoidosis is a systemic noncaseating granulomatous disease of unknown cause that may involve virtually any organ, including the parotid gland. Involvement of the parotid gland has been reported in 6 to 30% of patients with systemic sarcoidosis.<sup>1</sup> A diagnosis of sarcoidosis is based on the radiologic identification of both a distinctive lung infiltrate and a hilar lymphadenopathy. A final diagnosis requires pathologic evidence of noncaseating granulomas that are typically non-necrotic, hyalinized, and small.<sup>2</sup> In addition, laboratory studies--such as measurement of the serum angiotensin-converting enzyme level, which is elevated in as many as 80% of patients support the diagnosis.<sup>3</sup>

### Case Report

A 40 year old male presented to the ENT OPD with history of painless bilateral parotid enlargement since 3 weeks. Patient was referred to us for FNAC. He also gave history of xerostomia and xerophthalmia in the right eye. There was no significant past medical history. O/e both the parotids were

enlarged and firm (fig1). There was no peripheral lymphadenopathy or skin rashes.

FNA was performed using 22 gauge needle attached to a 10 cc plastic syringe. Smears were stained with Papanicolou, Giemsa and Zeil Neilson stains. The smears showed plenty of noncaseating epithelioid cell granulomas,(fig3a&b) few atrophic salivary gland acini and few lymphocytes. Few Giant cells were seen,(fig 3c) occasional ones showing asteroid body.(fig 3d) Schaumann bodies were not seen. The smears were negative for Acid fast bacilli. No fungal elements or foreign bodies were seen. The diagnosis of Granulomatous Parotitis was offered with the differential of Tuberculosis and Sarcoidosis. The complete blood counts and biochemical investigations including S. Calcium were within normal limits. The Serum ACE level was 72 micrograms/litre. Xray chest showed bilateral hilar lymphnode enlargement.(fig 2)

On the basis of the above, the diagnosis of Sarcoid was given.

## Discussion

Sarcoidosis most commonly affects lungs, followed by lymph nodes and spleen. The salivary glands are rarely involved and usually manifests in a variety of clinical patterns.<sup>5</sup> They commonly presents as major salivary gland enlargement with only histopathological involvement of the minor salivary glands. The second clinical pattern is characterized by the absence of clinical salivary gland swelling with only histopathological involvement of minor salivary glands. Heerfordt's syndrome or uveoparotid fever is the third pattern, which consists of a triad of symptoms including parotid swelling, uveitis and facialpalsy.<sup>5</sup>Xerostomia is a frequent finding and might point to minor salivary gland involvement. Xerophthalmia was also a relatively frequent clinical feature due to lacrimal gland involvement

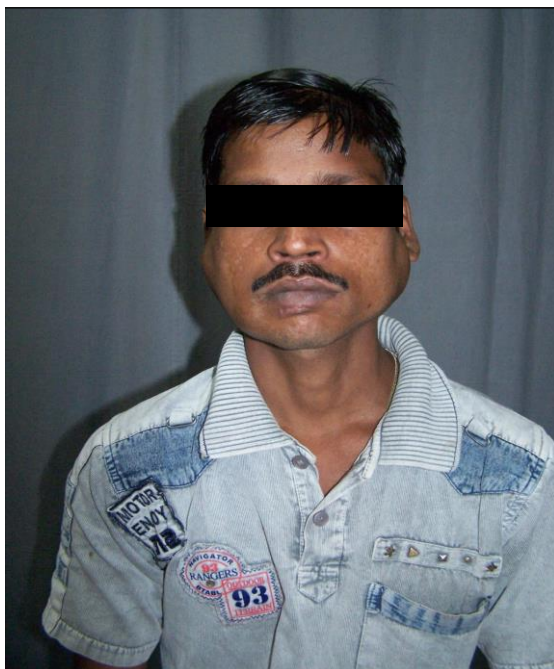Parotid gland involvement occurs in 6 to 30% of patients of sarcoidosis and may manifest as unilateral or bilateral painless swelling.<sup>1</sup> Xerostomia may be associated depending upon the extent of granulomatous infiltration of the gland.<sup>2</sup>Diagnosis is confirmed by the presence of non-caseating

epithelioid cell granulomas of the affected parotid gland either on histology or cytology. Since non-caseating granulomas are also seen in tuberculosis, Ziehl-Neelsen stain should be done to rule out the above condition<sup>5</sup>. Salivary gland acini showing either atrophic or degenerative changes or lymphocytes are seen. Multinucleated giant cells are also frequently seen with or without the presence of asteroid bodies, calcium oxalate crystals and Schaumann bodies.<sup>4</sup>

## Conclusion:

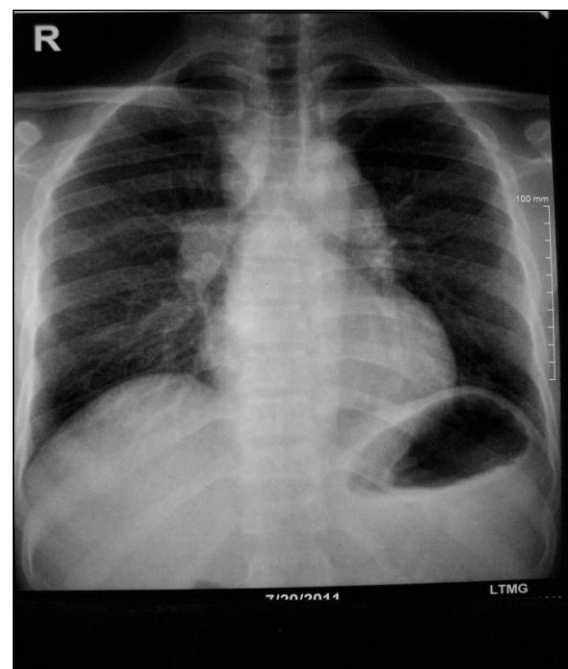
FNAC is the most preferred diagnostic procedure for parotid gland enlargements. Sometimes rarely as in our case, parotid enlargement might be the initial manifestation of sarcoidosis Early diagnosis of Sarcoidosis of the parotids and differentiating it from the more common Tuberculous inflammation of intraglandular or periglandular lymph nodes is very important from the treatment point of view. Although rare, Sarcoidosis of the parotids should be considered in the differential diagnosis of bilateral parotid swelling. After excluding Tuberculosis, clinico-radiological findings of multi-organ involvement suggest the diagnosis in such cases.

## Captions:



**Fig1**

Clinical photograph of the patient with bilateral parotid enlargement.



**Fig 2**

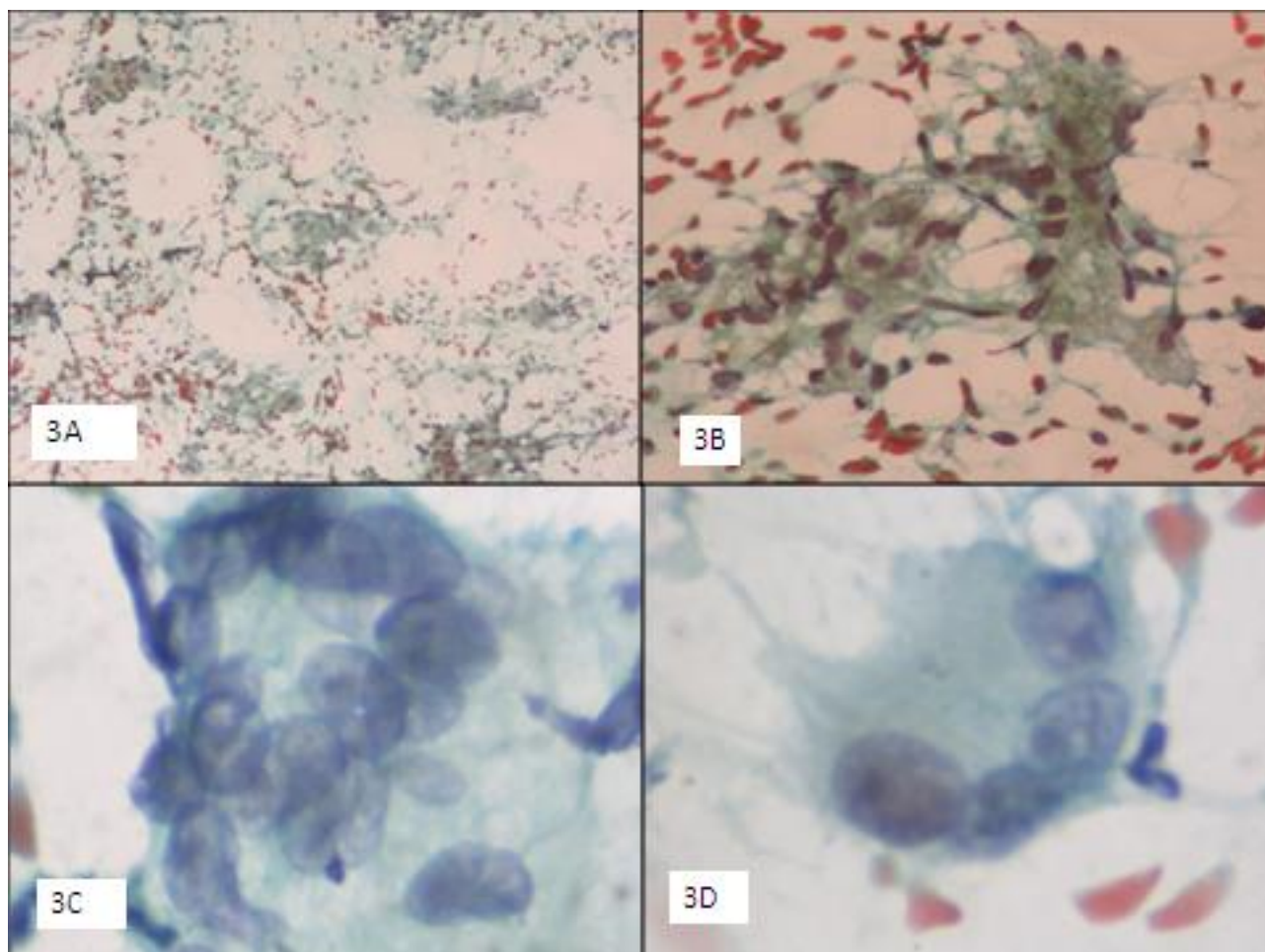
X ray chest showing bilateral hilar lymphadenopathy

Papinicoulou stained aspirate smears showing noncaseating epithelioid granulomas

**Fig 3a** 100x **Fig 3b** 400x

**Fig 3c** Smears showing multinucleated giant cells along with epithelioid cell pap stain 1000x

**Fig 3d** Giant cell pap stain 1000x



## References

1. Aggarwal AP, Jayaram G, Mandal AK. Sarcoidosis diagnosed on fine-needle aspiration cytology of salivary glands: a report of three cases. *Diagn Cytopathol.* 1989;5(3):289-92.
2. Sinha R, Gaur SN. Sarcoidosis presenting as acute bilateral parotid swelling. *Asian Pac J Allergy Immunol.* 2004 Jun-Sep;22(2-3):171-4.
3. Mair S, Leiman G, Levinsohn D. Fine needle aspiration cytology of parotid sarcoidosis. *Acta Cytol.* 1989 Mar-Apr;33(2):169-72.
4. Tamme T, Leibur E, Kulla A. Sarcoidosis (Heerfordt syndrome): a case report. *Stomatologija.* 2007;9(2):61-4.
5. Gayathri B, Kalyani R, Manjula K. Primary tuberculous parotitis. *J Cytol.* 2011 Jul;28(3):144-5.
6. Pérez-Guillermo M, Sola Pérez J, Espinosa Parra FJ. Asteroid bodies and calcium oxalate crystals: two infrequent findings in fine-needle aspirates of parotid sarcoidosis. *Diagn Cytopathol.* 1992;8(3):248-52.