

## “Evaluation and comparison of alveolar bone loss of maxilla and mandible in completely edentulous patients on digital panoramic radiographs”

Samiksha Acharya<sup>1,\*</sup>, VK Lohe<sup>2</sup>, RR Bhowate<sup>3</sup>

<sup>1</sup>Senior Resident, <sup>2</sup>Associate Professor, <sup>3</sup>Professor & HOD, Dept. of Oral Medicine & Radiology, Sharad Pawar Dental College & Hospital, Wardha, Maharashtra

**\*Corresponding Author:**

Email: smkacharya@gmail.com

### Abstract

**Aim:** Evaluation and comparison of alveolar bone loss of maxilla and mandible in completely edentulous patients on digital panoramic radiographs.

**Methods:** Alveolar bone loss was evaluated on digital panoramic radiograph. In maxilla, alveolar bone height was evaluated by a horizontal line joining both inferior margins of the infraorbital margin (Lz) was drawn. The midline was determined by vertical line joining the Lz to the nasal septum. Another vertical line joining from premolar region and molar region represented vertical distances from line Lz to the alveolar crest. In the mandible, a line was drawn tangential to the most inferior points at angle of mandible and the lower border of the mandible. The measurement of the midline to alveolar crest, for premolar and molar region the line vertically drawn at the mental foramen region for premolar region and another vertical line drawn from the molar region to alveolar crest.

**Results:** The mandible showed significant bone loss ( $p < 0.05$ ) as compared to maxilla. There was significantly ( $p < 0.05$ ) more bone loss in females as compared with males and denture wearers showed significant ( $p < 0.05$ ) amount of bone loss as compared with non-denture wearers.

**Conclusions:** The total alveolar bone loss was greater in mandible as compared with maxilla. The denture wearer has more bone loss as compared with the non-denture wearers and females had more bone loss as compared to male.

**Keywords:** Alveolar bone loss (ABL), Alveolar bone height (ABH), Total alveolar bone loss (T-ABL), Denture wearer (DW), Non-denture wearer (NDW).

### Access this article online

**Website:**

[www.innovativepublication.com](http://www.innovativepublication.com)

**DOI:**

10.5958/2395-6194.2016.00030.8

### Introduction

Alveolar ridge resorption after teeth extraction is a chronic, progressive and cumulative disease of bone reconstruction. Extensive alveolar bone loss shows many problems in prosthetic dentistry rehabilitation.<sup>1</sup>

In many phases of prosthetic dentistry, healthy alveolar bone with normal regenerative capacity is essential for a successful treatment outcome.<sup>2</sup> Alveolar bone loss is widely recognized as one of the most important factors affecting denture support, retention, strength, and masticatory function in edentulous patients.<sup>3</sup>

The aim of modern dentistry is to restore the edentulous patients to normal contour, function, comfort, aesthetic, speech and health, regardless of the atrophy, disease or injury of the stomatognathic system.<sup>4</sup>

Alveolar bone loss (ABL) and remodelling directly affect the function of removable prostheses, which relies greatly on the quantity and architecture of the jaw bones.<sup>5</sup> ABL may progress without apparent symptoms

until the patient's dentures become loose. Therefore, the ability to predict which patients are likely to lose a greater amount of bone is important both for prevention purposes and for subsequent making proper prosthetic treatment planning.<sup>6</sup> Besides that, to improve the outcome of denture retention, ridge preservation is very significant, even if implant therapy is required, sufficient alveolar bone volume and favourable ridge architecture.<sup>5</sup>

Panoramic radiography is a readily accessible diagnostic modality in many dental offices and provides broad anatomical coverage of the maxillofacial region and thus is often used as an initial screening tool for patients. Advantages include low patient dose, high patient acceptability, and short imaging time.<sup>7</sup> The image quality of the panoramic radiography is increased by the digital panoramic radiography. It is a fact that panoramic imaging is widely used for evaluation of the jaws for planning implant surgery and the other purposes.<sup>8</sup>

Although CBCT is a gold standard for the assessment of alveolar bone loss, but it is expensive, not feasible and has more exposure as compared to digital panoramic radiograph. So, to evaluate alveolar bone loss digital panoramic radiography was used in this study.

## Materials & Methods

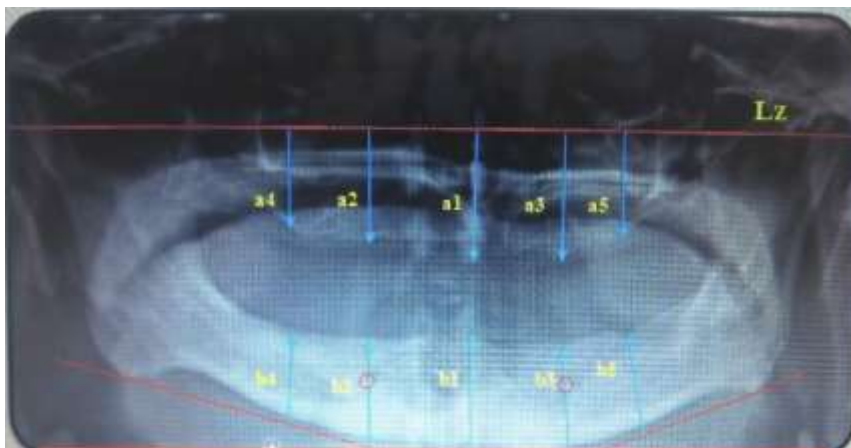
After obtaining the approval from the Institutional Ethics Committee (DMIMS (DU)/IEC/2013-14/131), this study was carried out on a total of 60 completely edentulous subjects (30 men and 30 women), who attended the Out Patient Department of Oral Medicine and Radiology. Inclusion criteria were that of 60 completely edentulous subjects who were further divided into two groups: GROUP A: 30 completely edentulous and denture wearers; GROUP B: 30 completely edentulous and non-denture wearers. Individuals with a history of hyperparathyroidism, osteoporosis, hypo and hyper-thyroidism, diabetes, chronic renal disease, malignancy of bone and any history of extraction of last tooth of the oral cavity between 1- 6 months before study were excluded from the study.

Digital Panoramic radiographs were taken with particular attention to the horizontal and sagittal positioning of the head with a 12 mA, 15 sec and 70–80 KvP panoramic machine (Planmeca Proline CC Panoramic X-ray, Planmeca OY Helsinki, Finland, 2002 with annotation software).

## Measurements

The reference lines and measurement points were marked on the digital panoramic radiographs with annotation in following manners:

1. In maxilla, alveolar bone height was evaluated for knowing the amount of alveolar bone loss. To evaluate alveolar bone height, a horizontal line joining both inferior margins of the infraorbital margin (Lz) was drawn. The midline was determined by images of the nasal septum, anterior nasal spine and nasopalatine foramen. The measurements a1 (midline), a2-a3 (Right and left premolar region), a4-a5 (Right and left molar region) represented vertical distances from line Lz to the alveolar crest (Fig. 1).
2. In the mandible, a line was drawn tangential to the most inferior points at the mandibular angle and the lower border of the mandible. The measurement b1 (midline), b2-b3 (at mental foramen region for right and left premolar region) and b4-b5 (right and left molar region) was recorded (Fig. 1).



**Fig. 1: Radiographic view shows alveolar bone height measurements of maxilla and mandible (yellow line) and reference line (redline)**

## Reliability

Reliability was assessed using repeated measurements. An oral radiologist served as the main observer, and intra-observer reliability was estimated between measures performed 1 month apart.

## Statistical analysis

The data were analysed with SPSS. The data were expressed as the mean (Standard deviation). Measurements were evaluated with Student t-test and Chi-square test. For the analysis of the correlation the Pearson's correlation test was performed. The level of significance was set as  $p < 0.05$ . Repeatability of the measurements was assessed by analysing the difference between measurements made one month apart on the radiograph of the all patients and again was repeated on second time 1 month apart by using Cronbach's Alpha test.

## Observations and Results

All observations were readable and were included in the present study. For the present study, total 60 patients were selected which were equally divided into 2 groups, Group A, denture wearer (DW) and group B, non-denture wearer (NDW). In each group A and B there were 15 (50%) males and 15 (50%) females. The mean age ranged from 35 to 85 years; the mean age in Group A was  $63.30 \pm 11.03$  years and in Group B was  $60.50 \pm 8.20$  years.

The period of edentulism of the maximum numbers of patients were between the 0.5- 5 years of POE in both the groups A and B, and minimum number of patients were seen above 10 years of POE in both the groups A and B (Table 1). The period of denture wearing in males and females both were seen maximum in the period 0.1 to 5.5 years (Table 2).

**Table 1: Distribution of 60 patients according to period of edentulism**

Period of edentulism	Group A	Group B	$\chi^2$ -value	p-value
0.5-5 yrs	18(60%)	21(70%)	1.51	0.46 NS, p>0.05
6-10 yrs	7(23.33%)	7(23.33%)		
>10 yrs	5(16.67%)	2(6.67%)		
Total	30(100%)	30(100%)		
Mean	7.00	3.77		
SD	6.65	4.22		

DW- Denture wearer, NDW- Non- Denture wearer, SD – Standard Deviation

**Table 2: Gender wise distribution of duration of denture wearing**

Duration (Yrs)	Male (N=15)	Female (N=15)	t-value	p-value
0.1-5.5	6(20%)	12(40%)	5.28	0.15, NS
6-10	5(16.67%)	2(6.67%)		
11-15	1(3.33%)	0(0%)		
>15	3(10%)	1(3.33%)		
Mean Duration	8.43	4.26		
SD	6.31	6.04		

N- Total number, Yrs- years, SD- Standard Deviation

### Measurements in Maxilla

The alveolar bone height is considered inversely proportional to alveolar bone loss. Region wise alveolar bone height was measured in maxilla and following observations were made: The mean alveolar bone height in anterior region of group A ( $3.52 \pm 0.51$  mm) and group B ( $4.07 \pm 0.68$  mm), in premolar region, group A ( $3.58 \pm 0.44$  mm) and group B ( $4.06 \pm 0.61$  mm) and in molar region, group A ( $2.04 \pm 0.52$  mm) and group B ( $2.50 \pm 0.59$  mm). The alveolar bone height was compared between group A (DW) and group B (NDW) in anterior, premolar and molar region this showed statistically significant difference in both the groups (Table 3).

**Table 3: Region wise comparison of maxillary alveolar bone height (ABH) between group A and group B**

ABH Evaluation	Group	N	Mean	Std. Deviation	Std. Error Mean	t-value	p-value
AR	A	30	3.52	0.51	0.09	3.52	0.001 S, p<0.05
	B	30	4.07	0.68	0.12		
PMR	A	30	3.58	0.44	0.08	3.42	0.001 S, p<0.05
	B	30	4.06	0.61	0.11		
MR	A	30	2.04	0.52	0.09	3.17	0.002 S, p<0.05
	B	30	2.50	0.59	0.10		

ABH- Alveolar bone height, AR- Anterior Region, PMR- Premolar Region, MR- Molar Region, S- Significant, N- Total number, Std- standard

Gender wise alveolar bone height was measured in maxilla and following observations were made: The mean alveolar bone height in anterior region, males ( $4.28 \pm 0.46$  mm) and females ( $3.30 \pm 0.42$  mm), in premolar regions, males ( $4.27 \pm 0.43$  mm) and females ( $3.38 \pm 0.32$  mm) and in molar regions, males ( $2.73 \pm 0.40$  mm) and females ( $1.82 \pm 0.38$  mm). The maxillary alveolar bone height was compared between the male and female in anterior, premolar and molar region which was statistically highly significant difference in both genders (Table 4).

**Table 4: Gender wise comparison of ABH in maxillary region**

ABH Evaluation	Gender	N	Mean	Std. Deviation	Std. Error Mean	t-value	p-value
AR	Male	30	4.28	0.46	0.08	8.41	0.000 S, p<0.05
	Female	30	3.30	0.42	0.07		
PMR	Male	30	4.27	0.43	0.07	9.04	0.000 S, p<0.05
	Female	30	3.38	0.32	0.05		
MR	Male	30	2.73	0.40	0.07	8.00	0.000 S, p<0.05
	Female	30	1.82	0.38	0.07		

ABH- Alveolar bone height, AR- Anterior Region, PMR- Premolar Region, MR- Molar Region, S- Significant, N- Total number, Std- standard

### Measurements in Mandibular

The mandibular alveolar bone height was compared between group A and B in mandibular anterior, premolar and molar regions. Following observations were made: The mean alveolar bone height in anterior region, group A ( $3.02\pm 0.75$  mm) and group B ( $3.70\pm 0.51$  mm), in premolar region, group A ( $1.54\pm 0.34$ mm) and group B ( $2.53\pm 0.53$ mm) and in molar region, group A ( $1.33\pm 0.25$ mm) and group B ( $2.03\pm 0.47$ mm). This indicates statistically highly significant difference in both the groups (Table 5).

**Table 5: Region wise comparison of mandibular alveolar bone height (ABH) between group A and group B**

ABH Evaluation	Group	N	Mean	Std. Deviation	Std. Error Mean	t-value	p-value
AR	A	30	3.02	0.75	0.13	4.08	0.000 S, p<0.05
	B	30	3.70	0.51	0.09		
PMR	A	30	1.54	0.34	0.06	8.45	0.000 S, p<0.05
	B	30	2.53	0.53	0.09		
MR	A	30	1.33	0.25	0.04	7.12	0.000 S, p<0.05
	B	30	2.03	0.47	0.08		

ABH- Alveolar bone height, AR- Anterior Region, PMR- Premolar Region, MR- Molar Region, Group A- Denture wearer, Group B- Non- Denture wearer, S- Significant, N- Total number, Std- standard

The mandibular alveolar bone height was compared between genders in mandibular anterior, premolar and molar regions. Following observations were made: The mean alveolar bone height in anterior region, males ( $3.58\pm 0.61$ mm) and females ( $3.14\pm 0.76$  mm), in premolar region, males ( $2.38\pm 0.63$  mm) and females ( $1.70\pm 0.52$  mm) and in molar region, males was ( $1.96\pm 0.53$  mm) and females ( $1.41\pm 0.31$  mm). This indicates statistically highly significant difference in both genders (Table 6).

**Table 6: Gender wise comparison of ABH in mandibular region**

ABH Evaluation	Gender	N	Mean	Std. Deviation	Std. Error Mean	t-value	p-value
AR	Male	30	3.58	0.61	0.11	3.43	0.018 S, p<0.05
	Female	30	3.14	0.76	0.14		
PMR	Male	30	2.38	0.63	0.11	4.51	0.000 S, p<0.05
	Female	30	1.70	0.52	0.09		
MR	Male	30	1.96	0.53	0.09	4.86	0.000 S, p<0.05
	Female	30	1.41	0.31	0.05		

ABH- Alveolar bone height, AR- Anterior Region, PMR- Premolar Region, MR- Molar Region, S- Significant, N- Total number, Std- standard

### Total ABH

The alveolar bone height was compared between the maxillary and mandibular region in anterior, premolar and molar regions. Following observations were made: In anterior region, the mean alveolar bone height in maxilla was

4.61±0.43 mm and in mandible was 3.36±0.72 mm. In premolar region, the mean alveolar bone height in maxilla was 3.82±0.58 mm and in mandible was 2.04±0.67 mm. In molar region, the mean alveolar bone height in maxilla was 2.27±0.60 mm and in mandible was 1.68±0.51 mm. These indicate statistically significant difference and showed more bone loss in mandible as compared with the maxilla. The bone loss was seen more in posterior region, followed by premolar and anterior region (Table 7).

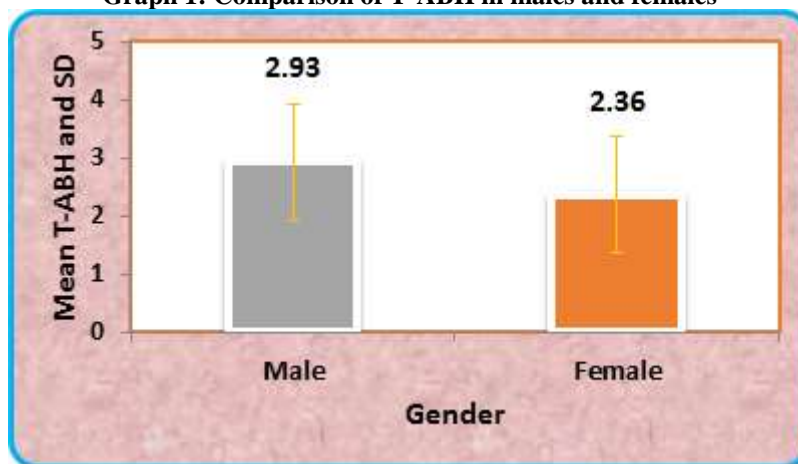
**Table 7: Comparison of alveolar bone height (ABH) between maxilla and mandible in AR, PMR and MR**

ABH Evaluation	Jaw	N	Mean	Std. Deviation	Std. Error Mean	t-value	p-value
AR	Maxilla	60	4.61	0.43	0.05	11.46	0.000 S, p<0.05
	Mandible	60	3.36	0.72	0.09		
PMR	Maxilla	60	3.82	0.58	0.07	15.54	0.000 S, p<0.05
	Mandible	60	2.04	0.67	0.08		
MR	Maxilla	60	2.27	0.60	0.07	5.78	0.000 S, p<0.05
	Mandible	60	1.68	0.51	0.06		

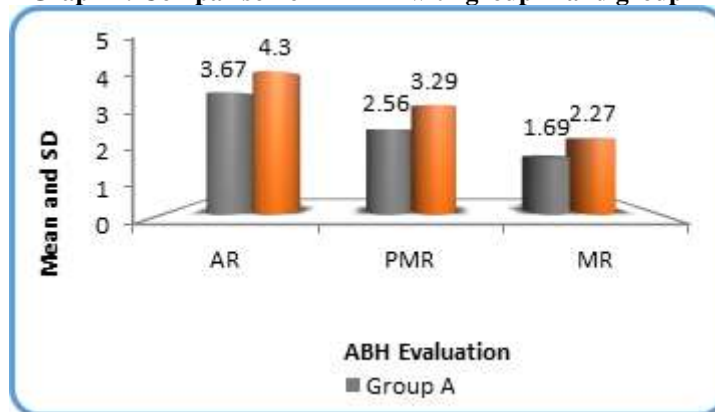
ABH- Alveolar bone height, AR- Anterior Region, PMR- Premolar Region, MR- Molar Region, S- Significant, N- Total number, Std- standard

The total alveolar bone height (maxilla and mandible) was compared between the male and female. Following observations were made; the mean of total alveolar bone height in male was 2.93±0.20 mm and in female was 2.36±0.17 mm. These indicate statistically significant difference in both genders. The bone loss is seen more in the females as compared to males (Graph 1).

**Graph 1: Comparison of T-ABH in males and females**



The total alveolar bone height was compared between the groups A and B in anterior, premolar and molar region. Following observations were made: In anterior region, the mean of T-ABH in group A was 3.67±0.90 mm and in group B was 4.30±0.70 mm. In premolar region, the mean of T-ABH in group A was 2.56±1.10 mm and in group B was 3.29±0.96 mm. In molar region, the mean of T-ABH in group A was 1.69±0.54 mm and in group B was 2.27±0.58 mm. These indicate statistically highly significant difference in both the groups. The denture wearers showed more bone loss as compared to non-denture wearers. In the molar region the bone loss was more as compared to premolar and anterior region (Graph 2).

**Graph 2: Comparison of T-ABH with group A and group B**

### Correlation

The duration of denture wearing was negatively correlated with the total alveolar bone height according to gender. In males, the mean duration of denture wearing was  $8.43 \pm 6.31$  years and the mean alveolar bone height was  $2.93 \pm 0.20$  mm. The r-value was  $-0.029$  and p-value was  $0.91$ , which was statistically non-significant. In females, the mean duration of denture wearing was  $4.26 \pm 6.04$  years and the mean alveolar bone height was  $2.36 \pm 0.17$  mm. The r-value was  $-0.36$  and p-value was  $0.18$ , which was statistically non-significant. In both male and female there was negative correlation with the duration of denture wearing. As the duration of denture wearing increased the bone loss also increased.

### Reliability

The intra-observer reliability analysis of Alveolar bone height (ABH) showed intra-observer agreement  $0.999$  and  $1.000$ , respectively. This shows excellent agreement.

### Discussion

Panoramic radiography is a readily available diagnostic modality in many dental offices and provides broad anatomical coverage of the maxillofacial region and thus is often used as an initial screening tool for patients. Although CBCT is a gold standard for the evaluation of alveolar bone loss, but it is expensive, not feasible and has more exposure as compared to panoramic radiograph. So, to evaluate alveolar bone loss digital panoramic radiography was used in this study.

In the present study, a total of 60 subjects were selected from the OPD of Oral Medicine and Radiology, Sharad Pawar Dental College, Sawangi (Meghe), Wardha in the year 2013 - 2015 were selected. The study group represented a typical range of edentulism in OPD, who had attended hospital for prosthetic rehabilitation.

Among 60 patients 50% were males and 50% were females, in group A (denture wearer) and in group B

(non-denture wearer) also there were 50% males and 50% females. Which was in accordance with Jabrah<sup>9</sup> and Saglam.<sup>10</sup>

The patients were divided in two groups, group A (denture wearer) and group B (non-denture wearer). Their age ranged from 35 years to 80 years with the mean age was  $63.30 \pm 11.03$  years in Group A and in Group B was  $60.50 \pm 8.20$  years. The differences were statistically non-significant in both the groups, which were similar to the study of Tallgren<sup>11</sup>, in their study the mean age was  $63.7 \pm 13.5$  years in denture wearer and  $72.1 \pm 25$  year (age range 59 to 88 years) in non-denture wearer.

In the present study, all the patients were distributed according to their period of edentulism both in group A (DW) and B (NDW). The maximum number of patients in both the group A 18(60%) and B 21(70%) were seen in between the period of 0.5 to 5 years of period of edentulism. This distribution was in accordance with Jagadeesh MS, Patil RA and Kattimani PT.<sup>12</sup>

In the present study, the duration of denture wearing was distributed according to gender. The distribution of denture wearing was not significant. But according to the distribution of denture wearing, males and females both were seen maximum in the period of 0.1 to 5.5 years. Whereas, Sennerby L, Carlsson GE, Bergman B et. al<sup>13</sup> reported that the mean period of edentulism ranged between 2.4 and 23.9 years of wearing complete dentures and according to Jabrah<sup>9</sup> the maximum duration of denture wearing was seen below 5 years in which, 13 were males and 15 were females.

In the present study, the mean alveolar bone height was evaluated in the entire three regions (anterior, premolar and molar region) of the maxilla and compared in group A (DW) and B (NDW). Among all the regions the alveolar bone loss was significantly measured maximum in molar region of denture wearers and minimum bone loss was measured in the anterior region of non-denture wearer. The explanation could be that the number of dentures worn and duration of complete denture wearing is very often related with

alveolar ridge resorption. The individual who wear their complete dentures continuously day and night, have more resorptive changes in the jaws compared to those who wear dentures only in day time. The alveolar bone loss was seen more in posterior region as compared to the anterior region because of masticatory forces, this finding was similar to the study of Zlataric DK, Celebic A and Lazic B<sup>1</sup>, Ural C, Bereket C and Şener I<sup>8</sup>, Jabrah<sup>9</sup>, Canger EM and Celenk P<sup>14</sup>, Jagadeesh MS, Patil RA and Kattimani PT.<sup>12</sup>

But, Few studies reported no association between RRR and duration of complete denture wearing.<sup>15,16</sup> According to Canger EM and Celenk P<sup>14</sup> found in their study that the maxilla has no significant differences between the vertical height in non-denture wearer and denture wearer groups. It can be suggested that the maxilla may protect itself since it is wider than mandible, and its composition helps the maxilla to accomplish the forces being applied on it.

In the present study, the alveolar bone loss, analysis was compared according to gender in the all the three regions of maxilla. In the maxilla the females were having more bone loss as compared to the males in all the three regions, in the molar region the alveolar bone loss was seen more in all three regions of maxilla. This was in accordance with Canger EM and Celenk P<sup>14</sup> who also observed the significant difference between women and men in every part of the jaw in both edentulous groups. Although the exact adverse effects of gender alveolar bone loss have not yet been established, the greater rate of alveolar bone loss within women is attributed to the accelerator effect of oestrogen deficiency on generalised mineral loss from the skeleton during and after menopause. Which is differed from Abdulhadi<sup>5</sup>, Ural C, Bereket C and Şener I<sup>8</sup>, Liang XH, Kim YM and Cho IH<sup>17</sup> who observed that the maxilla in both men and women have nearly the same amount of bone resorption.

In this study, mandible alveolar bone height was evaluated in all the three regions (anterior, premolar and molar region) between group A (DW) and group B (NDW). There was statistically highly significant difference in both the groups. These findings were supported by Liang XH, Kim YM and Cho IH<sup>17</sup> that the resorption rate of the mandible is four times that of the maxilla. As the mandibular residual ridge receives more pressure, the degree of residual bone resorption is more in the mandible than in the maxilla. The duration of complete removable dental prosthesis use is an important factor, because the longer the duration of use, the greater is the degree of resorption. Canger EM and Celenk P<sup>14</sup> also evaluated that the alveolar bone loss observed in denture wearers may be an inevitable consequence of the loss of natural teeth, tissue remodelling, and prolonged denture wear.

The mandibular alveolar bone height was compared between the gender (male and female) in mandibular anterior, premolar and molar region. This is

indicating statistically highly significant difference in both genders, in which the bone loss seen more in female than male in all the regions. This study was in accordance to Jabrah OA and Shumailan YA<sup>18</sup> in which the gender-related differences were recorded in both groups. Women had significantly greater amount of mandibular alveolar bone loss compared with men (24% and 16.3%; respectively).

The alveolar bone height was compared between the maxillary and mandible in anterior, premolar and molar regions. This showed statistically highly significant difference between both jaws. The alveolar bone loss was seen more in the mandible as compared to the maxilla. This was in accordance with Liang XH, Kim YM and Cho IH<sup>17</sup> in their study they interpreted that the mandibular residual ridge receives more pressure, so the degree of residual bone resorption is more in the mandible than in the maxilla. Ural C, Bereket C and Şener I<sup>8</sup> explained that there is difference in bone quantities between the mandible and maxilla; trabecular bone is more often looser in the edentulous maxilla than mandible.

The total alveolar bone height (maxilla and mandible) was compared between the males and females. This might be because in the present study elderly subjects were in usual age for menopause, and this may explain the gender-related difference observed in this study, which was in accordance with Engel MB, Rosenberg HM, Jordan SL et. al<sup>19</sup> and Jabrah.<sup>9</sup> Furthermore, experimental evidence has shown that estrogen depletion leads to a significant loss of bone mass in the edentulous mandible of female. Xie Q, Wolf J and Ainamo A<sup>15</sup> have found that females have more alveolar RRR than males, while Atwood DA and Coy WA<sup>20</sup> has presented a slightly higher rate in males.

In the present study, the total alveolar bone height was compared between the two groups A (DW) and B (NDW) in anterior, premolar and molar region. This showed statistically highly significant difference in both the groups. The bone loss was more in denture wearers as compared with non-denture wearers. This was in accordance with Zlataric DK, Celebic A and Lazic B<sup>1</sup>, Tallgren<sup>11</sup>, Jabrah<sup>9</sup> did a follow-up study of two groups of complete denture wearers to the 15 year and 25 year stages of denture wear revealed a continuing reduction of the residual ridges, particularly marked on the lower ridge. Canger EM and Celenk P<sup>14</sup> also concluded that the vertical heights of the non-denture wearer group were greater than the denture wearer group, especially in the mandible. In the maxilla, there were no significant differences between the vertical heights of non-denture and denture wearer groups. It can be suggested that the maxilla may protect itself since it is wider than mandible, and its composition helps the maxilla to accomplish the forces being applied on it. Whereas, according to Kordatzis K, Wright PS and Meijer HJA<sup>16</sup> did not get any significant difference between denture wearers and non-denture wearers.

In the present study the mean duration of denture wearer was correlated with the total alveolar bone height according to gender wise. Which showed statistically non-significant. But, ABH in male and female showed negative correlation with the duration of denture wearer. As the duration of denture wearing increases the bone loss is also increases. ABL is directly proportional duration of denture wearing. To our knowledge there is no study conducted for correlation of gender with duration of denture wearer.

### Conclusion

In many phases of prosthetic dentistry, healthy alveolar bone with normal regenerative capacity is essential for a successful treatment outcome.<sup>2</sup> Residual ridge resorption is widely recognized as one of the most important factors affecting denture support, retention, stability, and masticatory function in edentulous patients.<sup>3</sup>

The aim of modern dentistry is to restore the patient's normal contour, function, comfort, aesthetics, speech, and health, regardless of the atrophy, disease, or injury of the stomatognathic system.<sup>9</sup> Panoramic radiographs were developed as a fast, efficient and a simple method for recording the oral and associated structures for the screening of edentulous patients, especially to evaluate the vertical bone loss.<sup>19</sup>

In the present study, the ABL of maxilla was compared with ABL of mandible in completely edentulous patients on digital panoramic radiographs. The comparison revealed that the total alveolar bone loss was greater in mandible as compared with maxilla. The comparison of total alveolar bone loss according to region wise revealed that the T-ABL was greater in molar region as compared to premolar and anterior regions.

According to gender wise comparison the alveolar bone loss evaluation revealed that the bone loss was seen more in females as compared to males. The comparison of the alveolar bone loss in the denture wearer and non-denture wearers revealed that the alveolar bone loss was more in denture wearer as compared with non-denture wearer.

### References

- Zlataric DK, Celebic A, Lazic B. Resorptive Changes of Maxillary and Mandibular Bone Structures in Removable Denture Wearers. *Acta Stomatol Croat.* 2002;36(2):261-265.
- Zlataric DK, Celebic A. Clinical bone densitometric evaluation of the mandible in removable denture wearers dependent on the morphology of the mandibular cortex. *J Prosthet Dent.* 2003;90:86-91.
- Hirai T, Ishijima T, Hashikawa Y, Yajima T. Osteoporosis and reduction of residual ridge in edentulous patients. *J Prosthet Dent.* 1993;69:49-56.
- Guler AU, Sumer M, Sumer P, Bicer I. The evaluation of vertical heights of maxillary and mandibular bones and the location of anatomic landmarks in panoramic radiographs of edentulous patients for implant dentistry. *J Oral Rehabil.* 2005;32(10):741-6.
- Abdulhadi LM. Residual alveolar ridge resorption in completely edentulous patients influenced by pathophysiologic factors. *Dentika Den J.* 2009;14(1):29-36.
- Xie Q, Aimano A, Tilvis R. Association of residual ridge resorption with systemic factors in home-living elderly subjects. *Acta Odontol Scand.* 1997;55:299-305.
- White SC, Pharoah MJ. *Oral Radiology: Principles and Interpretation*, 3<sup>rd</sup> Ed. St Louis: Mosby. 2003.
- Ural C, Bereket C, Şener I. Bone height measurement of maxillary and mandibular bones in panoramic radiographs of edentulous patients. *J Clin Exp Dent.* 2011;3(1):5-9.
- Jabrah OA. Association of type 2 diabetes mellitus with the reduction of mandibular residual ridge among edentulous patients using panoramic radiographs. *Open Journal of Stomatology.* 2011;1:61-68.
- Saglam AA. The vertical heights of maxillary and mandibular bones in panoramic radiographs of dentate and edentulous subjects. *Quintessence Int.* 2002;33:433-138.
- Tallgren A. The continuing reduction of the residual alveolar ridges in complete denture wearers: A mixed-longitudinal study covering 25 years. *J Prosthet Dent.* 1972;27:120-32.
- Jagadeesh MS, Patil RA, Kattimani PT. Clinical Evaluation of Mandibular Ridge Height In Relation To Aging and Length of Edentulism. *JDMS.* 2013;3(4):44-47.
- Sennerby L, Carlsson GE, Bergman B, Warfvinge J. Mandibular bone resorption in patients treated with tissue-integrated prostheses and in complete-denture wearers. *Acta Odontol Scand.* 1988;46(3):135-40.
- Canger EM, Celenk P. Radiographic evaluation of alveolar ridge heights of dentate and edentulous patients. *Gerodontology.* 2012;29:17-23.
- Xie Q, Wolf J, Ainamo A. Quantitative assessment of vertical heights of maxillary and mandibular bones in panoramic radiographs of elderly dentate and edentulous subjects. *Acta Odontol Scand.* 1997;55(3):155-61.
- Kordatzis K, Wright PS, Meijer HJA. Posterior mandibular ridge resorption in patients with conventional dentures and implant overdentures. *Int J Oral Maxillofac Implants* 2003;18:447-452.
- Liang XH, Kim YM, Cho IH. Residual bone height measured by panoramic radiography in older edentulous Korean patients. *J Adv Prosthodont.* 2014;6:53-9.
- Jabrah OA, Shumailan YA. Association of complete denture wearing with the rate of reduction of mandibular residual ridge using digital panoramic radiography. *International Journal of Dental Research.* 2014;2(1):20-25.
- Engel MB, Rosenberg HM, Jordan SL, Holm K. Radiological evaluation of bone status in the jaw and in the column in a group of women. *Gerodontology.* 1994;11:86-92.
- Atwood DA, Coy WA. Clinical, cepha-lometric, and densitometric study of reduction of residual ridges. *Journal of Prosthetic Dentistry.* 1971;26:280-295.