

Haemangioma of buccal mucosa with multile phleboliths- report of 2 rare cases and literature review

Akhilanand Chaurasia^{1,*}, Vaibhav², Gaurav Katheriya³

¹Assistant Professor, ^{2,3}Resident, Dept. of Oral Medicine & Radiology, Faculty of Dental Sciences, King George's Medical University, Lucknow

***Corresponding Author:**

Email: chaurasiaakhilanand49@gmail.com

Abstract

Haemangioma is the most common vessel malformation tumour of infancy and childhood. They generally occur in the first month of life. They have a rapid proliferative phase followed by involution. Haemangioma is classified as cutaneous type involving skin, lips and deeper structures, mucosal type involving the lining of the oral cavity, intramuscular type involving masticator and perioral muscles or intraosseous type involving mandible or maxilla. Phleboliths are calcified thrombi that occur in veins, venules and sinusoidal vessels of hemangiomas. Usually they occur as round or oval radio-opacity having single or multiple foci of calcification. We are reporting two cases of haemangioma of buccal mucosa having multiple phleboliths.

Keywords: Hemangiomas, Vascular malformation, Phlebolith, Buccal mucosa

Access this article online
Website: www.innovativepublication.com
DOI: 10.5958/2395-6194.2016.00033.3

Introduction

The term hemangioma is used to describe a large number of vaso-formative tumors¹. These lesions represent the most common growths in infancy and childhood, and may vary from small innocent birthmarks to large disfiguring tumors^{2,3}. Hemangiomas usually appear 2-4 weeks after birth, grow rapidly till the age of 6-8 months. By age 5-8 years, they start to involute and regress spontaneously in 70% of the cases⁴. Though haemangiomas involve the head and neck, they are rare in the oral cavity and usually occurs on tongue, lips, buccal mucosa, gingiva, palatal mucosa, salivary glands, alveolar ridge, and jaw bones^{1,5,6}. Females appear to have a slightly higher incidence than males⁷. Changes in blood flow dynamic within hemangiomas result in thrombus and phleboliths. Phleboliths are calcified nodules that can be regarded as a characteristic property of venous or cavernous hemangiomas⁸. Phlebolith formation is characteristic feature of hemangiomas. It was first described in the splenic vein. Although hemangioma is a relatively common lesion in the head and neck region, it is rarely associated with phlebolith in the region⁹. They may occur as single or multiple calcifications. They are usually small radiopacities, round or oval in shape. They should also be differentiated from salivary gland calculi, tonsilloliths, calcified lymph nodes, soft tissue tumors, calcification of arteries, antrolith, multiple military osteomas of skin, myositis ossificans,

calcified acne and cysticercosis¹⁰. Phleboliths are most commonly found in pelvic veins followed by head and neck region¹¹. In head and neck region masseter and/or buccinator muscles are the most common site. Only 23 cases of head and neck hemangiomas with phleboliths are well documented till date. Seven cases have been reported in buccal mucosa or cheek¹²⁻¹⁷, ten cases in the parotid, submandibular glands and submental region¹⁸⁻²⁵, one case was in the floor of the mouth⁸, one case was in the hypopharynx²⁶, three cases were on masseter²⁷⁻²⁹ and one case was in the parapharyngeal space³⁰. Phlebolith formation involves thrombi produced by sluggish blood flow in peripheral vessels. These thrombi slowly gets organized and mineralized to form radio-opaque calcified phlebolith. The calcification in thrombi starts from centre which form the core of phleboliths. The fibrinous component of thrombi then undergoes secondary calcification and becomes attached. Repetition of this process causes enlargement of the phlebolith³¹.

Case Report-1

A 21 year old female patient (**Fig. 1**) reported to us with presenting complaint of bluish red swelling involving right side of oral cavity since 5 years. The swelling was progressively increasing in size and causing disfigurement and difficulty in eating food as it was frequently coming in between the teeth while chewing. There was no significant past dental and medical history. The patient had normal gait and posture. She had normal intelligence and well oriented to surroundings. Her vitals were normal. There was no history of pain or bleeding associated with the swelling. On extra-oral examination there was mild disfigurement involving right side of face involving right angle of mouth (**Fig. 1**). The skin overlying the swelling has normal color and texture. All other structures were

normal. On intra-oral examination a bluish red swelling of 3x3 cm noted which was extending anteriorly from angle of mouth to occlusal line in maxillary 1st molar region posteriorly (**Fig. 2**). The overlying mucosa was smooth and bluish red in color. No ulceration/ breach in mucosa are noted. The swelling was non-tender and soft to firm in consistency. The adjacent oral structures were essentially normal. On the basis of clinical findings a provisional diagnosis of arteriovenous malformations has been reached. The patient was advised for contrast enhanced computed tomography and CT angiography. The contrast enhanced computed tomography showed a well-defined minimally enhancing heterogenous lesion measuring 2.3x1.2x3.0cm in size with few hyperdense foci (calcifications) in submucosal plane of right buccal mucosa. Few serpiginous enhancing channels are noted within the lesion. The lesion is seen abutting overlying skin and ipsilateral orbicularis oris muscle (**Fig. 3 & Fig. 4**) however the CT angiography showed a well-defined minimally enhancing soft tissue attenuation lesion (approx 2.8x2.7x1.5cm) with few foci of calcification (Phleboliths) in subcutaneous right buccal fat. The lesion is seen involving adjacent orbicularis oris muscle and reaching up to the skin surface. Few serpiginous enhancing vascular channels are noted within the lesion in venous phase (**Fig. 5 & Fig. 6**). The 3D CT reconstruction shows well defined phleboliths (**Fig. 7 & Fig. 8**). On the basis of radiographic findings final diagnosis of Haemangioma with phlebolith has been made. The patient is advised for routine blood investigations which was found to be normal. The patient is referred to department of oral and maxillofacial surgery for treatment where she is treated with perilesional 1 ml of 1% Sodium tetra-decyl sulfate monthly and lesion is receded 80% in size. The patient is again injected with 2 ml of 1% Sodium tetradecyl sulfate and lesion is vanished completely (**Fig. 9**).



Fig. 1: Photograph of patient having mild disfigurement involving right side of face involving right angle of mouth

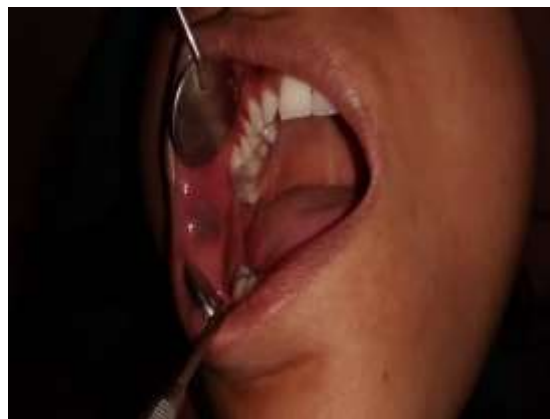

Fig. 2: Intra-oral photograph showing a bluish red swelling of 3x3 cm noted which was extending anteriorly from angle of mouth to occlusal line in maxillary 1st molar region posteriorly

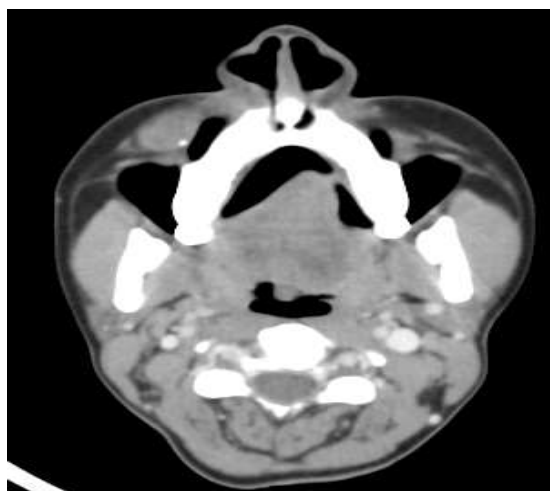


Fig. 3

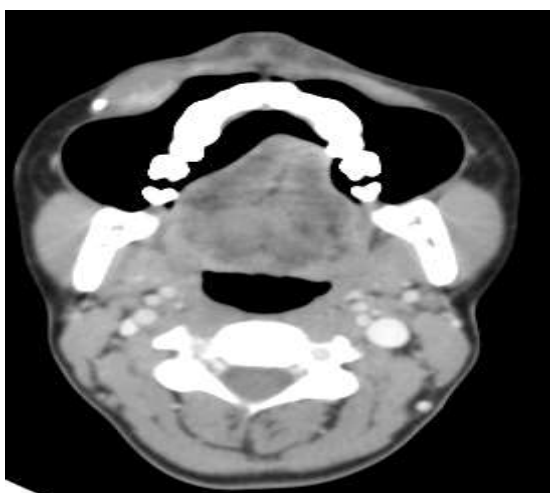


Fig. 4

Fig. 3 & 4: CECT image showing a well-defined minimally enhancing heterogenous lesion measuring 2.3x1.2x3.0cm in size with few hyperdense foci (calcifications) in submucosal plane of right buccal mucosa

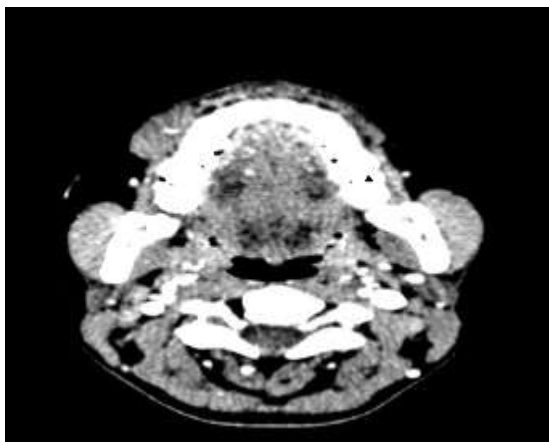


Fig. 5

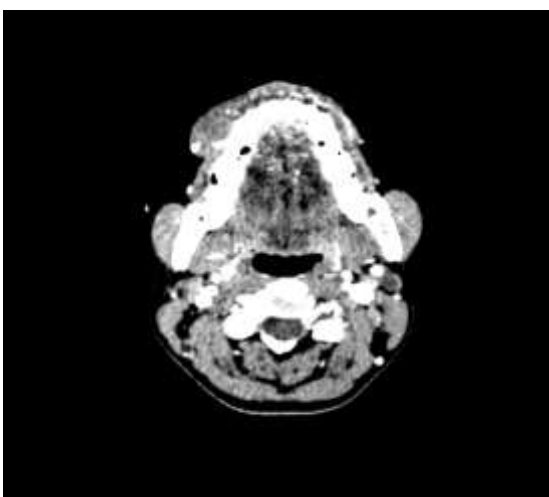


Fig. 6

Fig. 5 & 6: CT angiography showed a well-defined minimally enhancing soft tissue attenuation lesion (approx 2.8x2.7x1.5cm) with few foci of calcification (Phleboliths) in subcutaneous right buccal fat

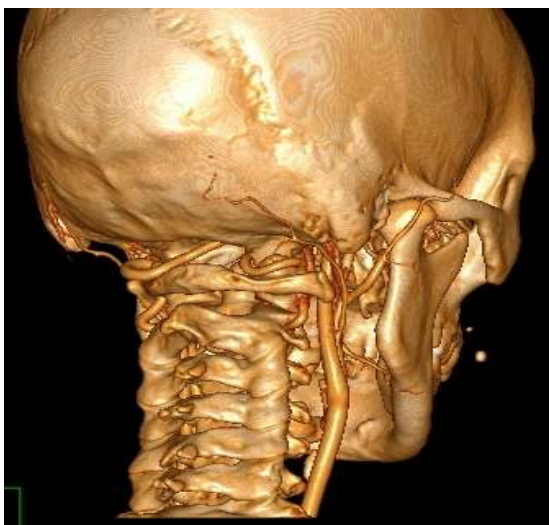


Fig. 7

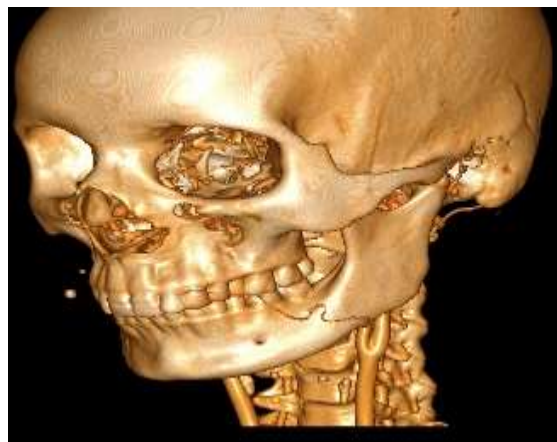

Fig. 8

Fig. 7 & 8: 3D CT reconstruction shows well defined phleboliths

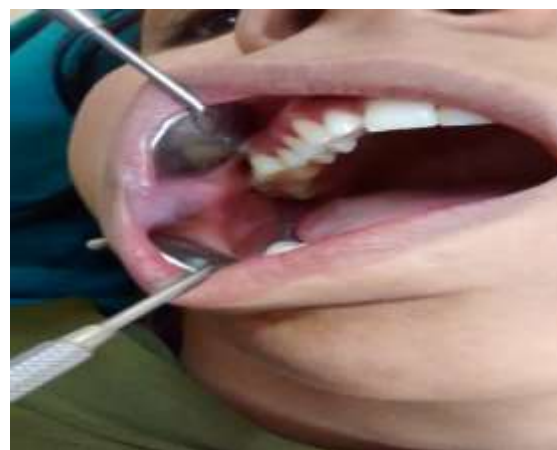

Fig. 9: Intra-oral photograph showing recession of lesion after injection of .2 ml of 1% Sodium tetradecyl sulphate

Case Report-2

A 33 year old male (Fig. 1) patient reported with chief complaint of swelling in left side of oral cavity since 10 years. The swelling was progressively increasing in size and causing difficulty in chewing food. He had no significant past medical and dental history. The patient had normal built and had normal gait and posture. He was well oriented and had normal intelligence. Mild facial asymmetry is noted in left side on extra-oral examination. On intra-oral examination a bluish red swelling of 10x6 cm having cobblestone appearance was noted which was extending 2cm lateral to left angle of mouth anteriorly to retro-molar area posteriorly involving the body of mandible, buccal alveolus, mandibular trigone and posterior part of floor of oral cavity(Fig. 2). The swelling has also involved the maxillary buccal alveolus and hard palate and posterior part of maxilla. There was no bleeding and pain associated with swelling. The mucosa overlying the swelling was deep purple in color. The swelling was non-tender and firm in consistency. There was no

cervical lymphadenopathy noted. The patient was advised for panoramic radiograph (Fig. 3) which shows 21 radiopacities measuring from 2 mm to 10mm in area of swelling. A periapical radiolucency of 3x3 cm is noted in apical area of left mandibular 2nd premolar and left mandibular 1st molar (Fig. 3). The left mandibular 2nd and 3rd molars were unerupted with stunted root. An irregular radiolucency of 3x3 cm involving left maxilla was noted with irregular borders. The left maxillary first molar has floating tooth appearance. The left glenoid fossa, articular eminence cannot be appreciated on panoramic radiograph. The width of ramus was lesser in left side comparatively (Fig. 3). The patient was advised for CT angiography which shows ill-defined isodense soft tissue lesion with network of multiple vascular channels enhancing in venous phase within noted in submandibular space extending into the left buccal mucosa. The lesion is contiguous extending into the masticator space involving infratemporal fossa, temporal fossa and all muscles of mastication, parotid space and the parapharyngeal space abutting and displacing the carotid vessels laterally. The lesion is abutting and displacing base of tongue and is extending towards right side of midline (Fig. 4). The lesion is distorting the pharyngeal lumen. Multiple calcified foci are noted within the lesion (Fig. 5). The lesion is causing erosion and remodeling of squamous part of left temporal bone, the left condylar fossa, lateral pterygoid plate, postero-laterally wall of left maxillary sinus, adjacent part of upper alveolus and adjacent part of body and ramus of mandible on left side and lateral wall of left orbit. The left maxillary sinus is small as compared to right (Fig. 6). Mildly prominent left retromandibular vessels is noted. Non visualization of left external carotid artery is seen distal to origin of superior thyroid artery for approx length of 6.7mm. Bilateral vertebral arteries are normal with normal branches and filling no evidence of dilatation or narrowing. The bilateral common carotid, visualized internal and right external carotid arteries are normal in caliber with normal contrast related enhancement. Visualized arch of aorta, right innominate and bilateral subclavian arteries are normal. No obvious extravasations of contrast agent are noted (Fig. 7a, 7b, 7c). Major veins are normal. These findings were highly suggestive of venous malformation. On the basis of clinical and radiological findings final diagnosis of haemangioma is reached.



Fig. 1: Photograph of patient

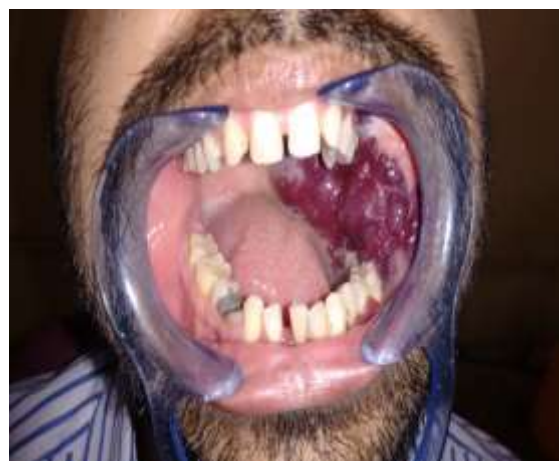

Fig. 2: On intra-oral photograph showing a bluish red swelling of 10x6 cm having cobblestone appearance was noted which was extending 2cm lateral to left angle of mouth anteriorly to retro-molar area posteriorly involving the body of mandible, buccal alveolus, mandibular trigone and posterior part of floor of oral cavity

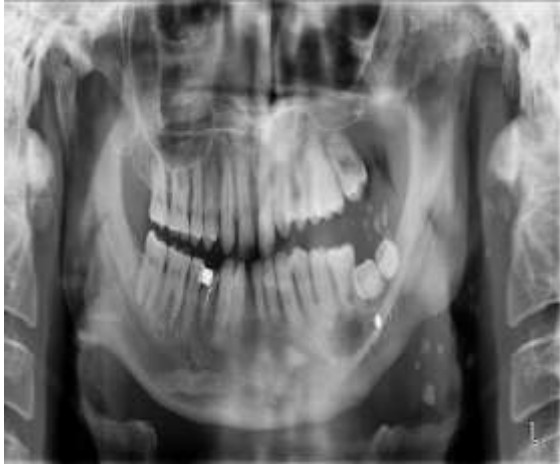

Fig. 3: Panoramic radiograph showing 21 radiopacities measuring from 2 mm to 10mm in area of swelling. A periapical radiolucency of 3x3 cm is noted in apical area of left mandibular 2nd premolar and left mandibular 1st molar

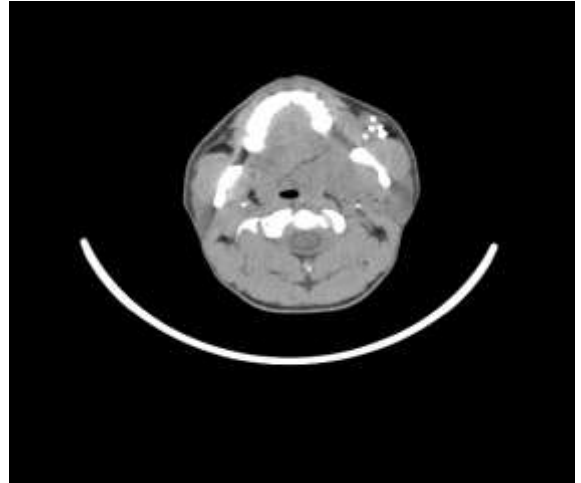


Fig. 5: CT angiography showing multiple phleboliths

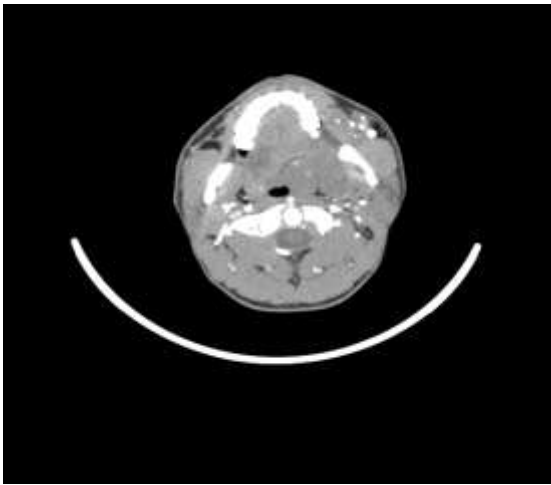


Fig. 4: CT angiography showing Ill-defined isodense soft tissue lesion with network of multiple vascular channels enhancing in venous phase within noted in submandibular space extending into the left buccal mucosa

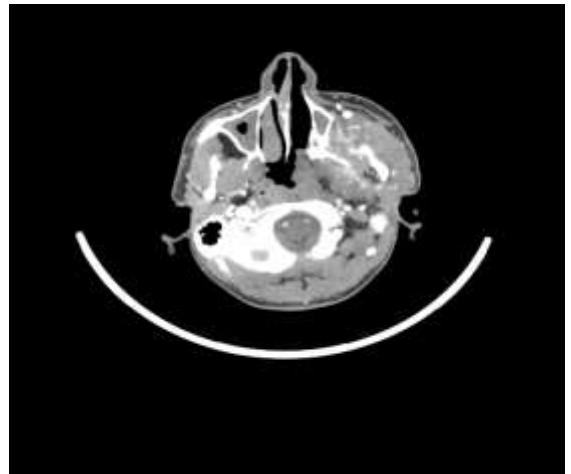
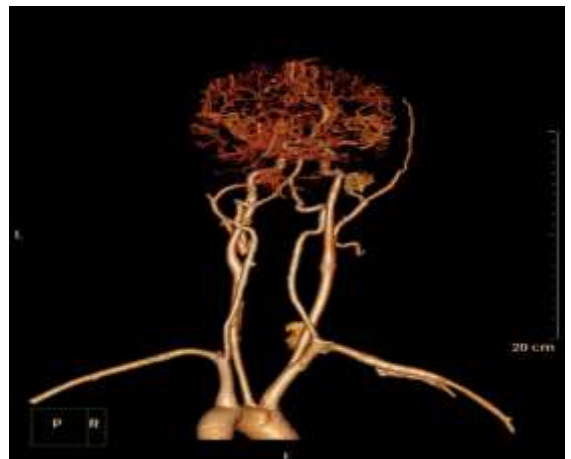

Fig. 6: CT showing the lesion is causing erosion and remodeling of squamous part of left temporal bone, the left condylar fossa, lateral pterygoid plate, postero-laterally wall of left maxillary sinus, adjacent part of upper alveolus and adjacent part of body and ramus of mandible



a

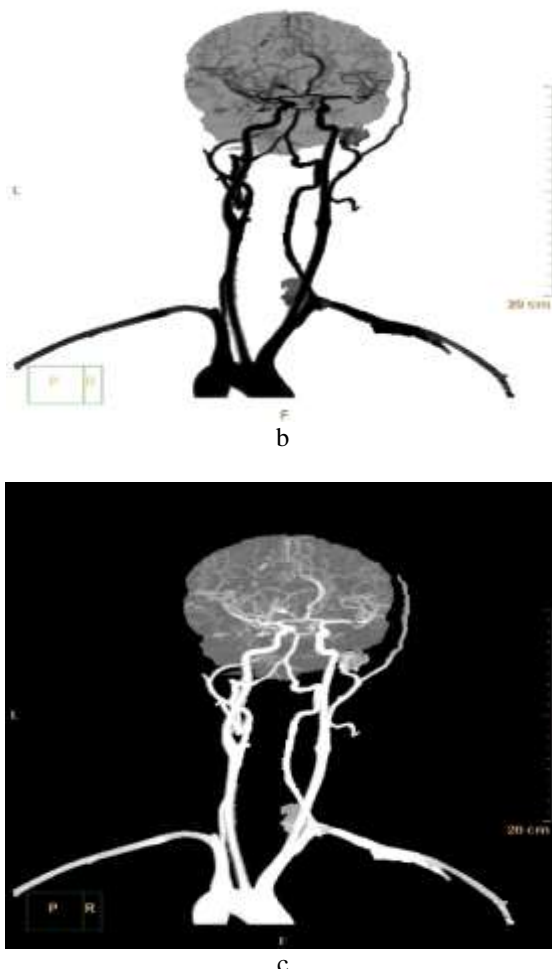


Fig.7a, 7b, 7c: Substraction 3D angiography showing mildly prominent left retro-mandibular vessels. Non visualization of left external carotid artery is seen distal to origin of superior thyroid artery for approx length of 6.7mm

Discussion

Bormann first used the term hemangioendothelioma in 1899³². Mallory used the term malignant vascular tumor for this lesion in 1908³³. Stout described the histological features of hemangiomas in 1944³⁴. Hemangiomas are the most common soft tissue tumor of childhood^{35,36,37} and head and neck region is the most common site for hemangiomas (about 60% of cases)³. The term hemangioma was originally used to describe any vascular tumor-like structure, whether it was present at or around birth or appeared later in life. The term is comprised of the Greek words “haema” which means blood, “angio” meaning vessel and “oma” meaning tumor. Histologically hemangiomas are composed of hyperplastic endothelial cells, which are line the inner surface of the blood vessels in the human body, with the capacity for intensive proliferation. The diameter of the blood vesels is important in classification of

hemangiomas to capillary and cavernous types³⁸. The capillary type, also known as the strawberry hemangioma is composed of small thin-walled vessels of capillary size that are lined by a single layer of flattened or plump endothelial cells and surrounded by a discontinuous layer of pericytes and reticular fibers^{38,39}. It was first described in the literature in 1973 by Sznajder et al⁴⁰, under the term "Hemorrhagic hemangioma"³⁹. Haemangioma usually occurs in the skin, subcutaneous tissue or muscle. Haemangioma of soft tissue can be divided into intramuscular and extramuscular. The most common sites for intramuscular haemangioma are the trunk and lower limbs. Only 10 to 20% of all intramuscular haemangioma present in the head and neck, and 60% are in the masseter and trapezius. Other possible sites are periorbital muscle, sternomastoid, temporalis muscle, geniohyoid and medial pterygoid⁴¹. Haemangiomas appear mainly in soft tissue although they also appear in hard tissue tissues more commonly in the head and neck, in approximately 50% of cases⁴². Hemangiomas are vascular abnormalities that are characterized by increased proliferation and renewal of endothelial cells. They are classified as cavernous, capillary and mixed hemangiomas. The 65% of the hemangiomas are located in the head and neck and they principally affect the salivary glands⁶. Lingual/buccal hemangiomas pose distressing problems to the patients, producing cosmetic deformity, recurrent hemorrhage, and functional problems with speaking, deglutition and mastication⁴⁰. The clinical appearance of this tumor is similar to that of many other vascular tumors. Clinically, hemangiomas are characterized as a soft, smooth or lobulated, sessile or pedunculated mass and may be seen in any size from a few millimeters to several centimeters⁴³. The color of the lesion ranges from pink to red or purple and blanches on the application of pressure; hemorrhage may occur either spontaneously or after minor trauma⁴⁴. Hemangiomas are benign tumours that are characterized by a rapid growth phase with endothelial cell proliferations followed by gradual involution⁴⁵. More than 80% of hemangiomas are solitary lesions⁴⁶. In 60% percent of cases hemangiomas are localized in the head and neck region with the distribution of the trigeminal nerve^{44,47,48}. They can be localized even in the infraorbital nerve canal⁴⁹. Hemangioma is characterized by increased number of normal or abnormal vessels filled with blood and connected to an artery or vein. Malignant transformation is not reported⁶. They may rarely enlarge rapidly causing local deformity and loss of function. Haemangiomas are usually painless but there are several reports of pain associated with vascular tumors^{43,44}. The diagnosis of a hemangioma is based on clinical history, physical, radiographic, laboratory and pathohistological examinations. Radiographic examinations are usually performed in cases of deeply positioned hemangiomas. The

examinations include conventional radiography with panoramic radiographs, angiography, computed tomography (CT), magnetic resonance imaging (MRI) and Doppler ultrasonography. Conventional radiography is used mostly for diagnosis of bone hemangiomas. Findings are multicystic “soap bubble” appearances. On CT the changes are in bone trabeculae. In diagnosis of soft tissue hemangiomas CT, MRI and Doppler ultrasonography are performed. Vascular lesions are characteristically much brighter on T2-weighted images than T1 weighted images due to the increased free water present within stagnant blood in the vessels. Ultrasound and color Doppler studies can also suggest a vascular lesion⁵⁰. MR imaging can be used to classify vascular malformations as either low flow or high-flow lesions especially when combined with dynamic contrast-enhanced MR angiography. Also evaluation of extraosseous extension can be diagnosed by MRI⁵¹. MRI is the ideal tool for diagnosis of soft tissue tumors, especially hemangiomas because they are able to delineate the vascular lesion from fatty tissue and muscle⁵². Characteristically hemangiomas in MRI shows a light bulb pattern. Laboratory examinations are important in differential diagnosis of hemangiomas to the other arteriovenous malformations and pathologies. Glucose transporter-1 (GLUT-1), vascular endothelial growth factor (VEGF), insulin-like growth factor-2 (IGF-2) and tissue growth factor beta (TGF-beta) are just some of the examined factors. The positive staining for GLUT-1 is considered highly specific and diagnostic for hemangioma, and it is useful for making differential diagnosis between hemangioma and other vascular lesions clinically related to it⁶. Differential diagnosis of the head and neck hemangiomas include several lesions such as pyogenic granuloma, chronic inflammatory gingival hyperplasia, epulis granulomatosa, telangiectasia, angiosarcoma, squamous cell carcinoma and other vascular appearing lesions such as Sturge Weber syndrome. The differentiation between hemangioma and vascular malformations is made on the basis of clinical appearance, histopathology, and biological behavior⁶. Aspiration and biopsy is contraindicated for diagnosis of hemangiomas as it can lead to excessive bleeding. A phlebolith is usually laminated with a radiopaque center, although the center is sometimes radiolucent, a small phlebolith is uniformly radiopaque⁵³. Moreover, there are often multiple phleboliths when associated with a hemangioma. There is masticatory trauma to the buccal mucosa leading to thrombus formation⁵⁵. Therefore, phleboliths are most frequently found in the buccal region. Phleboliths associated with vascular lesions are the most frequent^{31,53}. Cankaya et al. reported a hemangioma with phleboliths in the sublingual gland¹⁹. Baba and Kato reported a case of hemangioma with phleboliths in the floor of the mouth and Doppler ultrasonography, CT, magnetic resonance imaging (MRI) and biopsy was used to diagnose the

lesion²⁶. Intra oral hemangiomas associated with phlebolith are rare to occur. But practitioners should include this lesion in the differential diagnosis of intra oral swellings as it can occur on rare locations. Hemangioma with phleboliths should be identified from the differential diagnosis for lesion appearing as swellings like sialolithiasis, based on the clinical examination, imaging, histopathological and Immunohistochemical methods as the treatment of hemangioma is crucial. The presence of radiological phleboliths is very suggestive of hemangioma or vascular malformation, however these only occur in 2-3% of cases and it should be differentiated from sialoliths by a sialography. Due to spontaneous involution and regression, Haemangioma is managed conservatively observation and follow up. Intervention in management of haemangioma is recommended in case of bleeding, ulceration or associated dysfunction. Several treatment modalities are suggested for management of haemangioma including surgery, cryosurgery, intralesional administration of corticosteroids, Intralesional sclerosant (sodium tetradecyl), radiotherapy, and embolization with steel coil, gel foam, silicone beads or cyanoacrylate. In contrast to vascular malformations, most hemangiomas regress in response to medical treatment or with conservative managements^{54,55}.

Conclusion

Haemangioma is rare tumor of head and neck region. Very few cases of haemangioma with phleboliths have been reported in literature. Radiographically whenever radio-opacities (Phleboliths) are encountered in haemangioma, CT angiography and 3D CT is imaging modality of choice.

References

1. Lanza A, Gombos F. A case of multiple oral vascular tumours: the diagnostic challenge on haemangioma still remains open. *The Journal of Stomatological Investigation* 2008;2(1):67-71.
2. Mulliken JB, Glowacki J. Hemangiomas and vascular malformations in infants and children: a classification based on endothelial characteristics. *Plast Reconstr Surg* 1982;69(3):412-22.
3. Kaban LB, Mulliken JB. Vascular anomalies of the maxillofacial region. *J Oral Maxillo fac Surg* 1986;44(3):203-13.
4. Apfelberg DP. Treatment of hemangiomas. In: Georgiade GS, Georgiade NG, editors. *Textbook of Plastic, Maxillofacial and Reconstructive Surgery*. 2nd ed. Philadelphia, PA: Williams & Wilkins; 1992.
5. Enzinger FM, Weiss SW. *Soft Tissue Tumors*. 5th ed. St. Louis: CV Mosby.; 2001
6. Gill JS, Gill S, Bhardwaj A, Grover HS. Oral Haemangioma. *Case Report Med* 2012;2012:347939.
7. Shklar G, Meyer I. Vascular Tumors of the Mouth and Jaws. *Oral Surg Oral Med Oral Pathol* 1965;19:335-58.
8. Baba Y, Kato Y. Hemangioma with Phleboliths in the Floor of the Mouth Presenting as a Submental Swelling:

- A Case Report. *Journal of Medical Cases* 2011;2(1):28-30.
9. Dempsey EF, Murley RS. Vascular malformations simulating salivary disease. *Br J Plast Surg* 1970;23(1):77-84.
 10. Zachariades N, Rallis G, Papademetriou J, Konsolaki E, Markaki S, Mezitis M. Phleboliths. A report of three unusual cases. *Br J Oral Maxillo fac Surg* 1991;29(2):117-9.
 11. Rossiter JL, Hendrix RA, Tom LW, et al. Intramuscular hemangioma of the head and neck. *Otolaryngol Head Neck Surg.* 1993;108:18-26.
 12. Kutluhan A, Bozdemir K, Ugras S. The treatment of tongue haemangioma by plasma knife surgery. *Singapore Med J* 2008; 49(11): e312-e314.
 13. Kanaya H, Saito Y, Gama N, Konno W, Hirabayashi H, Haruna S. Intramuscular hemangioma of masseter muscle with prominent formation of phleboliths: a case report. *Auris Nasus Larynx* 2008;35(4):587-91.
 14. Sano K, Ogawa A, Inokuchi T, Takahashi H, Hisatsune K. Buccal hemangioma with phleboliths. Report of two cases. *Oral Surg Oral Med Oral Pathol* 1988;65(2):151-6.
 15. Ikegami N, Nishijima K. Hemangioma of the buccal pad with phlebolithiasis: report of a case. *Acta Med Okayama* 1984;38(1):79-87.
 16. Hemmati A. Phleboliths in a Hemangioma of the left Cheek. *Fortschr Geb Rontgenstr Nuklearned* 1965;102:210-1.
 17. Krause D. Multiple Phleboliths in a Cavernous Hemangioma of the Cheek. *Z Laryngol Rhinol Otol* 1964;43:125-7.
 18. Altug HA, Buyuksoy V, Okcu KM, Dogan N. Hemangiomas of the head and neck with phleboliths: clinical features, diagnostic imaging, and treatment of 3 cases. *Oral Surg Oral Med Oral Pathol Oral Radiol Endod* 2007;103(3): e60-e64.
 19. Cankaya H, Unal O, Ugras S, Yuca K, Kiris M. Hemangioma with phleboliths in the sublingual gland: as a cause of submental opacity. *Tohoku J Exp Med* 2003;199(3):187-91.
 20. Chuang CC, Lin HC, Huang CW. Submandibular cavernous hemangiomas with multiple phleboliths masquerading as sialolithiasis. *J Chin Med Assoc* 2005;68(9):441-3.
 21. Brands T. Hemangioma of the parotid gland with multiple phleboliths. *Zentralbl Chir* 1969;94(32):1064-7.
 22. NEUSS O. Multiple phleboliths in an angioma of the parotid gland. *Z Laryngol Rhinol Otol* 1958;37(4):240-2.
 23. Bartak J. Phleboliths in a hemangioma in the parotidomasseteric region. *Cesk Stomatol* 1967;67(2):126-8.
 24. McMenamin M, Quinn A, Barry H, Sleeman D, Wilson G, Toner M. Cavernous hemangioma in the submandibular gland masquerading as sialadenitis: case report. *Oral Surg Oral Med Oral Pathol Oral Radiol Endod* 1997;84(2):1468.
 25. Sleiter R, Altermatt HJ, Buser D, Bornstein M. Cavernous hemangioma in the masseter muscle with multiple phlebolith formation: a case report. *Schweiz Monatsschr Zahnmed* 2002;112(6):617-23.
 26. Li X. Rare cavernous haemangioma of the hypopharynx with numerous phleboliths. *J Laryngol Otol* 1990;104(3):262-3.
 27. Bernadskii I, Khimich AI, Kucher GD. Racemose facial hemangioma with multiple phleboliths. *Stomatologiia (Mosk)* 1983;62(1): 9.
 28. Schwartz A, Salz N. Cavernous hemangioma associated with phleboliths in the masseter muscle. *Actaradiol* 1955;43(3):233-4.
 29. Mohan RPS, Dhillon M, Gill N. Intraoral venous malformation with phleboliths. *Saudi Dent J* 2011;23(3):161-3.
 30. Cho JH, Joo YH, Kim MS, Sun DI. Venous hemangioma of parapharyngeal space with calcification. *Clin Exp Otorhinolaryngol* 2011;4(4):207-9.
 31. Raymond AK, Batsakis JG. Angiolithiasis and sialolithiasis in the head and neck. *Ann Otol Rhinol Laryngol.* 1992;101:455-7.
 32. Borrmann R. Metastaserbildung bis histologisch gutartigigen Geschulsten (fall metastasierendem Anjou). *Beitr z Path Anat* 1907;40:372.
 33. Mallory FB. The Results of the Application of Special Histological Methods to the Study of Tumors. *J Exp Med* 1908;10(5):575-93.
 34. Stout AP. Hemangio-Endothelioma: A tumor of Blood Vessels Featuring Vascular Endothelial Cells. *Ann Surg* 1943;118(3):445-64.
 35. Kutluhan A, Bozdemir K, Ugras S. The treatment of tongue haemangioma by plasma knife surgery. *Singapore Med J* 2008; 49(11): e312-e314.
 36. Eivazi B, Ardelean M, Baumler W, Berlien HP, Cremer H, Elluru R, et al. Update on hemangiomas and vascular malformations of the head and neck. *Eur Arch Otorhinolaryngol* 2009;266(2):187-97.
 37. Werner JA, Dunne AA, Folz BJ, Rochels R, Bien S, Ramaswamy A, et al. Current concepts in the classification, diagnosis and treatment of hemangiomas and vascular malformations of the head and neck. *Eur Arch Otorhinolaryngol* 2001;258(3):141-9.
 38. Neville BW, Damm DD, Allen CM, Bouquot JE: *Oral and Maxillofacial Pathology*. 2nd edition. WB Saunders;2002:447-449.
 39. Chang LC, Haggstrom AN, Drolet BA, et al. Growth characteristics of infantile hemangiomas: implications for management. *Pediatrics* 2008;122:360-7.
 40. Sznajder N, Dominguez FV, Carraro JJ, Lis G: Hemorrhagic hemangioma of gingiva: report of a case. *J Periodontol* 1973, 44:579-582.
 41. Rossiter JL, Hendrix RA, Tom LWC, Potsic WP: intramuscular tumour of head and neck. *Otolaryngology – Head and Neck Surgery* 1993;108:18-26.
 42. Gampper TJ, Morgan RF. Vascular anomalies: hemangiomas. *Plast Reconstr Surg.* 2002;110:572-585; quiz 586; discussion 587-578.
 43. Dilsiz A, Aydin T, Gursan N. Capillary hemangioma as a rare benign tumor of the oral cavity: a case report. *Cases Journal* 2009, 2:8622. doi:10.4076/1757-1626-2-8622.
 44. Neville B W, Damm D D, Allen C M, Bouquot J E . *Oral and maxillofacial pathology* 2nd edition, 2002, Saunders, Philadelphia. 437-95.
 45. Margileth AM, Museles M. Cutaneous hemangiomas in children: Diagnosis and conservative management. *JAMA* 1965;194:523.8.
 46. Richter GT, Friedman AB. Hemangiomas and vascular malformations: current theory and management. *Int J Pediatr.* 2012;2012:645678. Epub 2012 May 7.
 47. Mulliken JB, Fishman SJ, Burrows PE. Vascular anomalies. *Curr Probl Surg* 2000;37:517-84.
 48. Walch C, Anderhuber W, Luxenberger W, Humer-Fuchs U. Cavernous haemangioma in the infraorbital nerve canal--an unusual expansion in the maxillary sinus *J Laryngol Otol.* 1998 Sep;112(9):872-4.
 49. Rai P, Setia S, Kalra N, Upreti L. Intramuscular vascular malformation of the masseter muscle presenting with

- turkey wattle sign. *Oral Surg Oral Med Oral Pathol Oral Radiol Endod* 2006;102:618.
50. Donnelly LF, Adams DM, Bisset GS 3rd. Vascular malformations and hemangiomas: a practical approach in a multidisciplinary clinic. *AJR Am J Roentgenol.* 2000 Mar;174(3):597-608.
 51. Tsang WM, Tong ACK. Cavernous hemangioma of the masseter muscle, *Oral surg oral med oral pathol.*1998;85:229-30.
 52. O'Riordan B. Phleboliths and salivary calculi. *Br J Oral Surg* 1974;12:119-31.
 53. Scolozzi P, Laurent F, Lombardi T, Richter M. Intraoral venous malformation presenting with multiple phleboliths. *Oral Surg Oral Med Oral Pathol Oral Radiol Endod* 2003;96:197-200.
 54. El Abdin H, Haidar Z. Hemangioma of the tongue: a conservative treatment with circumferential ligation. *Saudi Dental Journal* 2012;10(1):18-22.
 55. Zheng JW, Zhou Q, Yang XJ, Wang YA, Fan XD, Zhou GY, et al. Treatment guideline for hemangiomas and vascular malformations of the head and neck. *Head Neck* 2010;32(8):1088-98.