

An integrated technique for the fabrication of a custom made ocular prosthesis for rehabilitating a patient with an acquired eye defect

Srujana Zakkula¹, Geetha Bhavani Paluri^{2*}, Sneha Deepthi³, Suresh Pothu⁴

^{1,4}Associate Professor, ²PG Student, ³Senior Lecturer, Dept. of Prosthodontics, Sibar Institute of Dental Sciences, Guntur, Andhra Pradesh

***Corresponding Author:**

Email: geetha3vm@gmail.com

Abstract

Several ocular and orbital diseases require surgical intervention that may result in ocular defects. These defects affect psychological, functional and social aspects of the patient. Management and rehabilitation of an ocular defect patient is a challenging task both clinically and technically. Stock acrylic ocular shells may be trimmed and fitted as one of the treatment options, but the results are not entirely satisfactory. Custom made ocular prosthesis helps in attaining the exact color, contour, size, ocular orientation that provides realism, symmetry and also enhances the psychological and social well-being of the patient. The role of the maxillofacial prosthodontist in fabricating a customized ocular prosthesis with acceptable esthetics to restore facial symmetry and normal appearance for the anophthalmic patient is indispensable. This article describes a novel approach for fabrication of customized ocular prosthesis using the advantages of digital photography.

Keywords: Ocular prosthesis, Digital imaging

Introduction

Treatment of congenital anomalies, tumours or traumatic injuries of the eye most often requires surgical intervention. Enucleation may be required for malignant neoplasm, penetrating wounds causing ophthalmitis, damage to the eye in which restoration of vision is impossible, blindness associated with painful or unsightly appearance of eye.^{1,2} Cosmetic replacement of enucleated or eviscerated eyes was done with ocular prostheses. Prior to world war II 'Glass Eyes' were used. Later acrylic resin prostheses were fabricated to overcome the fragility of glass.^{2,3} Various techniques were described for fabrication of custom ocular prosthesis or modification of stock ocular prosthesis.^{4,7} This article describes an integrated technique for custom made ocular prosthesis to improve function and aesthetics for an ocular defect patient.

Case Presentation

A thirty year-old male patient, reported to Department of Prosthodontics with the chief complaint of the missing left eye (Fig. 1). The patient had given the history of traumatic injury to the left eye, subsequent infection and purulent discharge from the affected eye. Following the surgical enucleation of the infected eye the patient was advised to use stock ocular prosthesis. The patient was not satisfied with the stock ocular prosthesis due to ill fit of the prosthesis.



Fig. 1: Preoperative photograph

Treatment

Impression procedures: The patient was positioned upright in the chair and instructed to maintain a fixed gaze. The direct impression was made by injecting ophthalmic alginate through the hollow stem of a 5 ml syringe.⁵ To fabricate the injection tube, unscrew the tip of a 5-mL plastic syringe (Becton Dickinson and Co, Franklin Lakes, NJ), and cut approximately 7 mm from the end. Roughen the sides of the tip and wedge it into the pupil perforation hole. Secure it with cyanoacrylate resin (Zapit; Dental Ventures of America Inc, Corona, CA). Repolish the tray, check for rough spots and impression was made. Dental stone mould was obtained from the primary impression. The undercuts in the mould were blocked with modelling clay (Fig. 2). A custom tray was fabricated over it with autopolymerising clear

acrylic resin. Multiple escape vents were made all over the custom tray and a syringe needle cap was secured to the custom tray to act as handle and a channel to inject the final impression material.⁵ Custom tray was disinfected with 2% sodium hypochlorite and tried in patient and necessary corrections were made (Fig. 3). The final impression was recorded using light body polyvinyl siloxane elastomeric impression material dispensed from an auto mixing unit. The patient was instructed to perform functional movements of the eye while making the impression (Fig. 4).

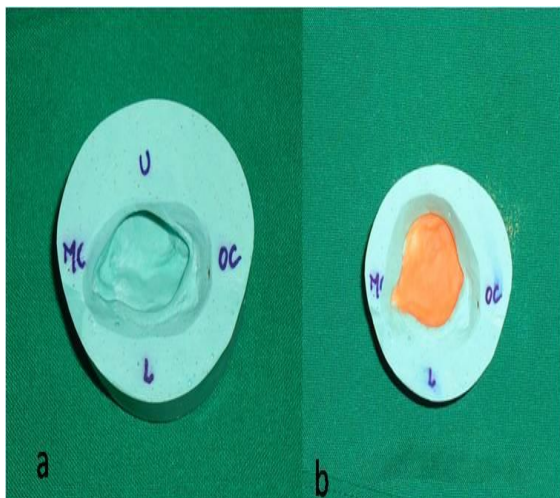


Fig. 2: a. Stone mould, b. Undercuts blocked out with modeling clay

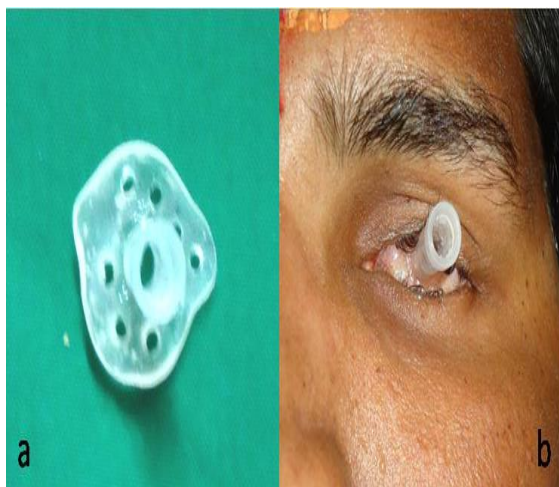


Fig. 3: a. Custom tray with stem, b. Try-in in patient

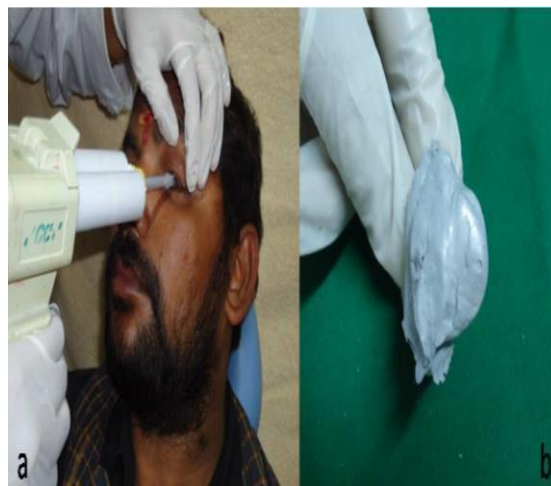

Fig. 4: a. Final impression making, b. Final impression

Wax pattern fabrication and Try-in: The final impression was invested in the putty matrix to obtain a mould for making wax pattern (Fig. 5). The obtained wax pattern was finished and tried in the patient. During the try-in appointment, the extension and fullness of the blank was evaluated and necessary corrections were done.

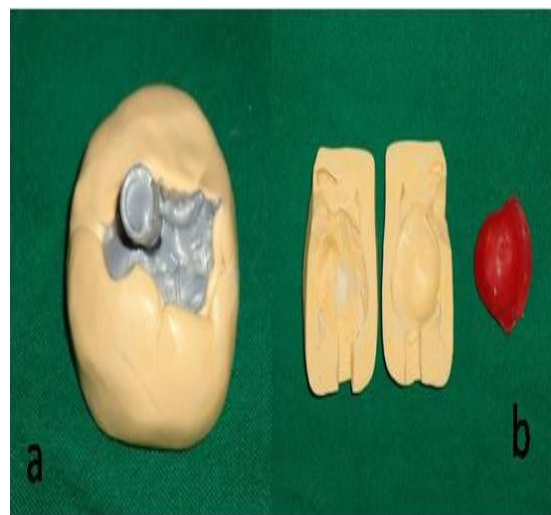


Fig. 5: a. Impression invested in putty matrix, b. Wax pattern

Sclera blank fabrication: After the desired contours were obtained the wax pattern is flaked and processed in sclera white acrylic resin. The processed resin sclera blank was retrieved from the flasking matrix so that it preserves the outer stone matrix and allows reseating of the modified sclera blank into this matrix for eventual reprocessing of the sclera blank's original contour.⁶ The polished sclera blank was disinfected with 10% providone-iodine aqueous solution and tried in the patient. The extensions and contours were reevaluated.

Iris orientation and positioning: The iris orientation was done by placing orientation marks on the patients face corresponding with the contralateral eye.³ The position of the iris was marked on the sclera blank. A trough was created in the marked position to place digital iris replica (Fig. 6). The sclera blank was reduced on the facial side⁶ by about 1.5 mm to create space for clear acrylic and was checked by coating the blank with alginate and packing it in the preserved flask. The alginate was separated from the blank and measured for uniform thickness with a round ended wax calliper (Essago SBC German stainless) (Fig. 7). A digital photographic image of the patient's right eye was taken and a photo print of the iris was taken on a glossy photo paper.⁷ The digital iris replica was cut and glued to the trough in the sclera blank. Characterization of the sclera blank was done based on the contralateral eye (Fig. 8) and a thin layer of self-cure clear acrylic was added over the sclera pattern and was packed in the preserved flask to obtain the correct contour (Fig. 9).⁶ The prosthesis was cured and highly finished and disinfected with 10% providone-iodine aqueous solution. The prosthesis was then inserted and examined for the contour, drape of eyelid, iris position and functional movements (Fig. 10). Final prosthesis was aesthetically pleasing and had good functional adaptability to the tissues in the recall checkups.

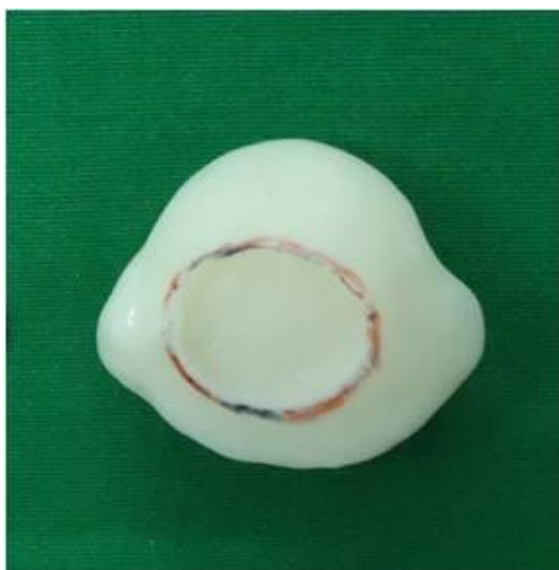

Fig. 6: Trough created to place iris replica

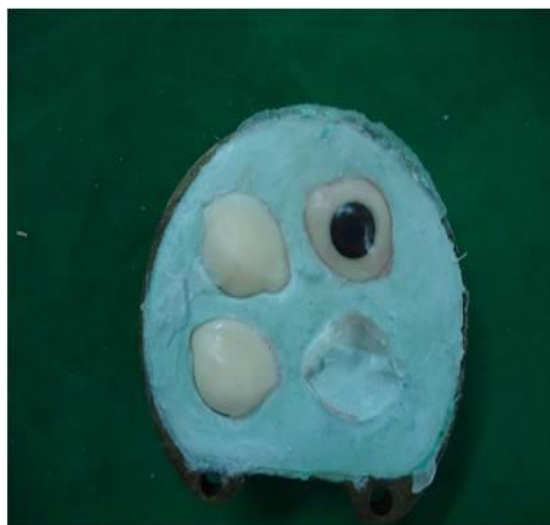

Fig. 7: Reduction of sclera blank and clearance verified with alginate

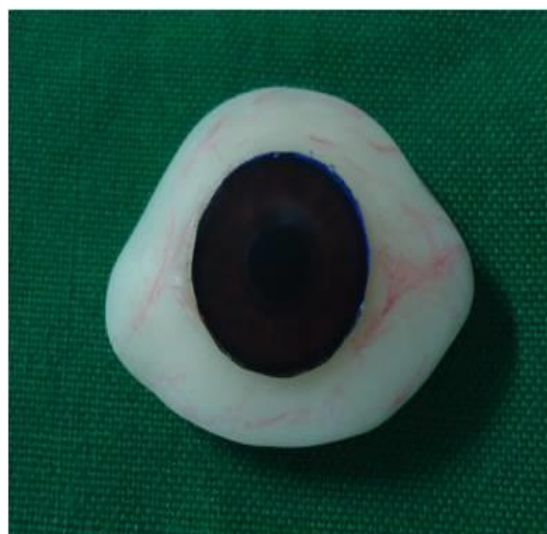

Fig. 8: Characterization of sclera



Fig. 9: Reflasking with clear acrylic resin



Fig. 10: Postoperative photograph

Post Insertion Instructions:

- Clean the prosthesis daily without removing from the socket, while removing it only occasionally for cleaning and disinfecting.
- To remove the prosthesis, take the prosthesis out from the lower lid first, and then pull it down from the upper lid. Never pull the prosthesis straight out.
- Insert the prosthesis through the upper portion first, and then pull down the lower lid while pushing up the prosthesis.
- Occasionally, you may want to disinfect and clean the surface of the prosthesis. It may be placed in a 3% hydrogen peroxide or a 10% providone-iodine aqueous solution (such as Betadine). The prosthesis should be immersed in the solution for no longer than 15 minutes and then rinsed thoroughly before reinsertion.
- Store the prosthesis in a sterile saline or balanced salt solution if it is removed for a period of time
- The prosthesis should be professionally cleaned and polished every six months.

Discussion

Rehabilitating an ocular defect patient with good esthetics and function needs more skill and is technique sensitive. Many authors have proposed different techniques right from modification of stock acrylic prostheses, impression techniques, iris positioning, iris duplication methods and final prosthesis fabrication. Customizing stock ocular prostheses immediately after surgery was advocated to preserve the size of the socket and to prevent scar tissue formation.^{4, 8} Bartlett⁹ had described a direct impression technique which was modified by directly injecting the alginate into the intraocular socket. Miller⁵ had described custom tray fabrication from making an impression with the stock ocular prosthesis.

Wax pattern is obtained either by investing the impression in stone⁹ or alginate⁵. The technique of

investing and processing wax sclera blank proposed by Brown has a distinct advantage like more accurate duplication of missing eye characteristics to reproduce the contours of the socket. Digital imaging technique^{7,10,11} has simplified the iris duplication. Advantages of digital imaging over conventional iris painting techniques in the fabrication of the ocular prosthesis presents acceptable esthetics, closely replicates patient's iris with minimal color adjustments, simple and less time consuming, requires minimal artistic skills. But this technique requires special computer software to produce a digital image.

Guttal et al¹² used transparent graph grid to position the iris. Visual judgment method was proposed by Benson for iris positioning. Roberts and Bulbulian proposed pupillometer method, Joneja et al has given window light or light reflection method that reflected light symmetrically in both the eyes, Brown proposed caliper measurements on the patients face, McArthur used fixed caliper and ocular locator to place ocular prosthesis in the socket. Nusinov et al have done inverted anatomic tracings to establish the contours of orbital tissue for ocular prosthesis¹³. Pai U Y et al¹³ mounted graph grid on eyewear to position the iris in comparison to the contralateral eye. This case report simplified the ocular prosthesis fabrication. As the impression was duplicated in a putty matrix it has given an advantage of making more than one wax patterns.

Conclusion

A simple procedure for fabrication of custom ocular prosthesis has been presented which reduces the time by minimizing the fabrication steps and at the same time enhancing the esthetic and functional values of the final prosthesis.

References

1. Taylor DT. Clinical maxillofacial prosthetics, 1st edn. Quintessence publishing Co., Inc, Chicago, IL 2000, pp156.
2. Kennedy JA: Fabrication of ocular prostheses, in Beumer J, Curtis TA, Marunick MT (eds): Maxillofacial Rehabilitation: Prosthodontic and Surgical Considerations. St Louis, MO, Ishiyaku Euro America, Inc, 1996, pp 348-352.
3. Benson P: The fitting and fabrication of a custom resin artificial eye. J Prosthet Dent 1977;38:532-538.
4. Welden RB, Niiranen JV: Ocular prosthesis. J Prosthet Dent 1956;6:272-278.
5. Mathews MF, Smith RM, Sutton AJ, Hudson R. The ocular impression: A review of the literature and presentation of an alternate technique. J Prosthodont 2000 9:210-6.
6. Brown KE: Fabrication of an ocular prosthesis. J Prosthet Dent 1970;24:225-235.
7. Artopoulou LL, Montgomery PC, Wesley PJ, Lemon JC. Digital imaging in the fabrication of ocular prosthesis. J Prosthet Dent 2006;95:325-30.
8. Kale E, Mese A, Izgi AD. A technique for fabrication of an interim ocular prosthesis. J Prosthodont 2008;17:654-61.

9. Bartlett SO, Moore DJ: Ocular prosthesis: A physiologic system. *J Prosthet Dent* 1973;29:450-459.
10. Jain S, Makkar S, Gupta S, Bhargava A. Prosthetic rehabilitation of ocular defect using digital photography: A case report. *J Indian Prosthodont Soc* 2010;10(3):190–193.
11. Jayaswal GP, Dange SP, Khalikar AN. Restoration of an atrophic eye socket with custom made eye prosthesis, utilizing digital photography. *Indian J Dent Res* 2011;22:482-5.
12. Guttal SS, Patil NP, Vernekar N, et al: A simple method of positioning the iris disk on a custom made ocular prosthesis. A clinical report. *J Prosthodont* 2008;17:223-227.
13. Pai UY, Ansari NA, Gandage DS. A technique to achieve predictable iris positioning and symmetry in ocular and orbital prostheses. *J Prosthodont* 2011;20:244-246.