

Determination of age from the appearance and fusion of medial clavicular epiphysis - An autopsy based study conducted at Govt. Stanley Medical College

S. Balasubramanian¹, K. Priyatharsini^{2,*}

¹Associate Professor, ²Assistant Professor, Dept. of Forensic Medicine, Govt. Stanley Medical College, Chennai

***Corresponding Author:**

Email: dr.priyatharsini@gmail.com

Abstract

Radiological assessment of ossification of medial clavicular epiphysis plays a vital part in age estimation of living adolescents and young adults. In the present study, skeletal maturity at the medial end of the clavicle for a known chronological age of the deceased of Tamilnadu population was analysed. Out of 155 clavicles that were collected from the autopsy samples, 117 belonged to male and 38 clavicles belonged to females. Based on radiological examination, ossification process was divided into 4 stages: stage I: Centre not appeared; stage II: Centre appeared but no union; stage III: Union started but incomplete; stage IV: Complete union. Majority of cases showed appearance of ossification centre at 17–18 years in females and 19–20 years in males. Earliest age of fusion was 20 years in females and 22 years in males. Majority of cases showed complete fusion at 25–26 years in both gender. No significant difference was observed in ossification activities in both sexes for the right and left clavicle.

Keywords: Radiological assessment, Clavicle, Tamil Nadu population, Age of fusion

Access this article online

Website:

www.innovativepublication.com

DOI:

10.5958/2394-6776.2016.00042.4

Introduction

Identification means determination of individuality of a person. Fixing up of the individuality of a person in civil cases like inheritance of property, passport, missing persons, disputed sex, marriage or in criminal cases like identification of accused in criminal offences of murder, dacoity, sexual offences etc has got its own importance.

Different anthropological observations have been noted in populations belonging to various geographical regions due to several factors. Generally, the formula used for estimating age, sex or stature of one population cannot be evenly applied to all other population¹. Hence, specific data of particular population are required to be analysed and formula for each population is to be derived. Due to various changes that occur in the population parameters over time, the formula so derived need to be analysed periodically to observe for any modification.

During a person's life span, their bones would constantly undergo changes and those changes that occur in the skeleton would follow a chronological pattern. Knowledge on those changes occurring in the bones would help in estimating age from the skeleton. The timing of appearance of the ossification centres and the process of fusion of the epiphysis with the diaphysis have a sequence and time period, which is utilized

In forensic age diagnosis of living adolescents and young adults, radiological assessment of the degree of ossification of the medial clavicle epiphysis plays a vital role. Based on various studies it was analyzed that commencement of union of the ossification centres can be detected significantly earlier with radiographs and computed tomography when compared with dry bone observations.

The main objective of the study was to estimate the age of an individual from the appearance and fusion of secondary ossification centre of medial end of the clavicle and to find out sexual variations in the appearance and fusion of secondary ossification centre of medial end of the clavicle.

Materials and Methods

The present study "Determination of age from the appearance and fusion of medial clavicular epiphysis" had been carried out in the department of Forensic Medicine, Govt Stanley Medical College, Chennai, during the period of 2015 to 2016. For this prospective study, 155 cases in the age group between 15–30 years were selected randomly among those cases subjected for Medico legal autopsy. Age of the deceased was noted as per given by the Investigating Officer and was verified with identify proof of the deceased like voter ID, ration card or driving license. Informed consent of the relatives of the deceased had been obtained. Permission of the ethical committee on the use of human material for research purpose was obtained.

Dissection techniques

An 'I' – shaped incision is made from the chin straight down to the pubic symphysis. The muscles of the chest are dissected away and ribs are cut at the upper border of the second cartilage along the

costochondral junction till the 7th rib. The medial two third of both the clavicles are cut by using handsaw, taking due care not to damage the medial end of the clavicle. The medial two third of both the clavicle along with portions of manubrium sternum were removed.

The adherent soft tissues are removed and a specific numbered tag was tied to the clavicle specimen (Fig. 5). The postmortem number, age and sex were noted separately and the specimen was preserved in 10 % formalin solution. X Rays of the collected clavicles were taken. An individual separate token number made of lead was placed above the individual clavicle specimen (for better visualization in X-ray film). A group of 16 clavicles were taken by a single exposure of the X-ray beam.

As per the observations and analysis of previous studies based on radiological assessment of degree of fusion of medial end of the clavicle, in this study, X ray antero-posterior view was taken to study the ossification of medial clavicular epiphysis.

Ossification process at the medial end of the clavicle was divided into the following four stages:

Stage 1: Centre not appeared

Stage 2: Centre appeared but no union

Stage 3: Union started but incomplete

Stage 4: Complete union.

Inclusion criteria: All bodies subjected for medicolegal autopsy in the age group between 15–30 years.

Exclusion criteria:

1. All bodies subjected for autopsy in the age group of less than 15 and more than 30 years.
2. All unknown cases subjected for autopsy.
3. Decomposed bodies.
4. Fracture of the Clavicle

Criteria for fusion:

1. There should be no gap or defect in the epiphyseal diaphyseal region of the bone.
2. There should be no discontinuity in the outline of the bone.
3. Presence of epiphyseal scar is considered as fused.

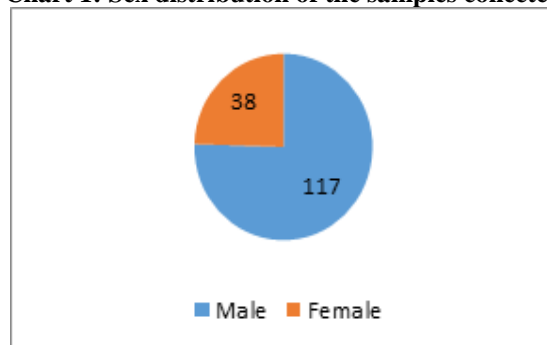
Criteria for non fusion:

1. There should be a clear gap or defect which resembles a fracture line between epiphysis and diaphysis of the bone.
2. Even a small defect in any of the two sides of the bone is considered as 'not fused'.

Results

In the present study 155 clavicles were collected from the autopsy cases submitted to the Department of Forensic Medicine, Stanley Medical College during the period of 2015-2016. The samples were collected by Simple Random Technique. Out of 155 clavicles that were collected, 117 belonged to males (75.4%) and 38 clavicles belonged to females (24.5%) as in (Chart 1).

Chart 1: Sex distribution of the samples collected



Samples that were collected between the age group 15–30 years were categorized into 8 classes for statistical analysis. In the age group of 15–16 years, a total of 7 clavicles were collected; out of which 4 clavicles belonged to male and 3 clavicles belonged to female. In the age group of 17–18 years, 24 clavicles were collected of which 15 were male and 9 were female. 24 clavicles belonged to the age group of 19–20 years, out of which 20 were male and 4 were female. In the age group 21–22 years, 25 clavicle samples were analyzed, out of which 21 samples were male and 4 samples were female.

26 samples in the age group 23–24 years were analysed, of which 4 clavicles were female and 22 were male. In the age group 25–26, 21 clavicles were collected, out of which 6 belonged to female and 15 were male. 15 samples were analyzed in the age group 27–28 years of which 9 were male and 6 were female. A total of 13 samples were analyzed in the age group 29–30 years, of which 11 samples belonged to male and 2 samples belonged to female as in (Table 1).

Table 1: Sample distribution among male and female

Age group in yrs	Male	Female	Total
15–16	4	3	7
17–18	15	9	24
19–20	20	4	24
21–22	21	4	25
23–24	22	4	26
25–26	15	6	21
27–28	9	6	15
29–30	11	2	13
Total	117	38	155

Observations in male samples

Secondary ossification centre was not appeared in all the 4 cases in the age group 15–16 years i.e. all the 4 cases were in stage I (Fig. 1) In 17–18 years age group, 13 cases (86.7%) were in stage I and 2 cases (13.3%) were in stage II (Ossification centre appeared but no union) (Fig. 2)

In the age group 19–20 years, 7 cases (35% were in stage I, 11 cases (55%) were in stage II and 2 cases

(10%) were in stage III (union started but incomplete). In 21–22 age group, 3 cases (14.3%) showed stage I, 12 cases (57.5%) showed stage II, 5 cases (23.8%) were in stage III and 1 case showed complete union i.e. Stage IV.

None of the case was in stage I at the age group 23–24 years, 4 cases (18.2%) showed stage II, 12 cases (54.5%) were in stage III and 6 (27.3%) cases showed stage IV. In age group 25–26 years, no case was in stage

I, 2 cases (13.3%) were in stage II, 6 cases (40%) were in stage III and 7 (46.7%) showed stage IV.

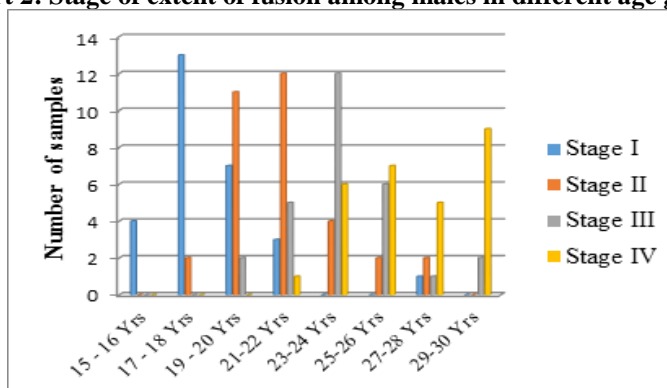
In the age group 27–28 years, 1 (11.1%) case was in stage I, 2 (22.2%) showed stage II, stage III was found in one case (11.1%) and stage IV was noted in 5 (55.6%) cases as depicted in (Table 2 and Chart 2).

In the last age group, 29–30 years, no cases were in stage I and stage II, 2 cases (18.2%) showed Stage III and 9 cases (81.8%) showed stage IV.

Table 2: Stage of fusion of medial end of the clavicle among males

Age group in years	Stage I Cases (%)	Stage II Cases (%)	Stage III Cases (%)	Stage IV Cases (%)
15-16	4 (100%)	0	0	0
17-18	13 (86.7%)	2 (13.3%)	0	0
19-20	7 (35%)	11 (55%)	2 (10%)	0
21-22	3 (14.3%)	12 (57.1%)	5 (23.8%)	1 (4.8%)
23-24	0	4 (18.2%)	12 (54.5%)	6 (27.3%)
25-26	0	2 (13.3%)	6 (40%)	7 (46.7%)
27-28	1 (11.1%)	2 (22.2%)	1 (11.1%)	5 (55.6%)
29-30	0	0	2 (18.2%)	9 (81.8%)

Chart 2: Stage of extent of fusion among males in different age groups



Observation in female samples

In the age group 15–16 years, 3 (100%) cases showed stage I. 3 cases (33.3%) were in stage I and 6 cases (66.7%) were in stage II in the age group 17–18 years.

In the age group 19–20 years, 2 cases (50%) showed stage I and 1 case (25%) was in stage II and one case showed complete union as in stage IV (25%). In the age group 21–22 years, 3 cases (75%) were in stage II and 1 case (25%) showed stage III (Fig. 3) None of the case was in stage I and stage IV.

Out of 4 cases, three cases in the group 23–24 were in stage II and one case was in stage IV. None of the case showed stage I and III. Out of 6 cases in the age group 25–26 years, 1 case (16.7%) was in grade III and 5 cases (83.3%) showed stage IV. Out of 6 cases in the age group 27–28 years all the cases was in grade IV. In the age group 29–30 years, all 2 cases showed complete fusion (Fig. 4)(Table 3 and Chart 3).

Table 3: Stage of fusion of medial end of clavicle among Females

Age group in years	Stage I Cases (%)	Stage II Cases (%)	Stage III Cases (%)	Stage IV Cases (%)
15-16	3 (100%)	0	0	0
17-18	3 (33.3%)	6 (66.7%)	0	0
19-20	2 (50%)	1 (25%)	0	1 (25%)
21-22	0	3 (75%)	1 (25%)	0
23-24	0	3 (75%)	0	1 (25%)
25-26	0	0	1 (16.6%)	5 (83.3%)

27-28	0	0	0	6 (100%)
29-30	0	0	0	2 (100%)

Chart 3: Stage of extent of fusion among females in different age groups

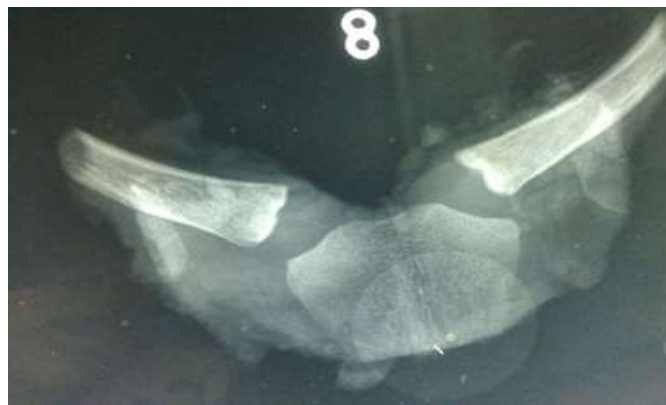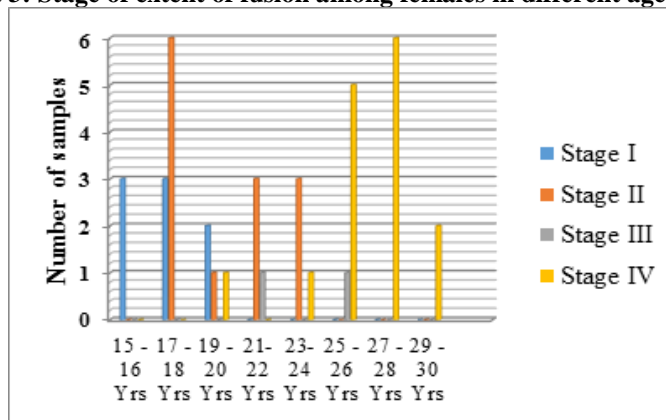


Fig. 1: Photoradiograph showing non-appearance of secondary ossification centre at the medial end of the clavicle – Stage I

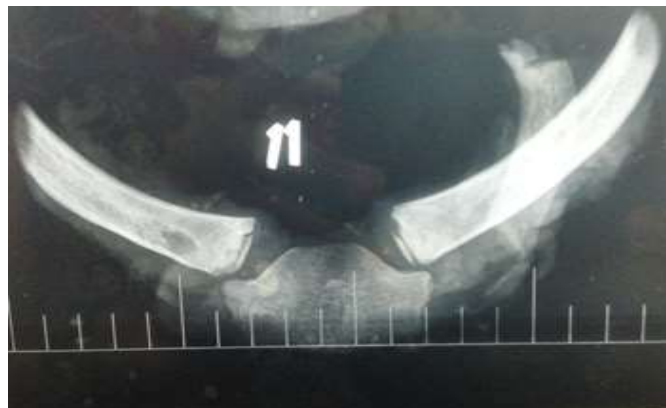

Fig. 2: Photoradiograph showing appearance of secondary ossification centre with no union – Stage II

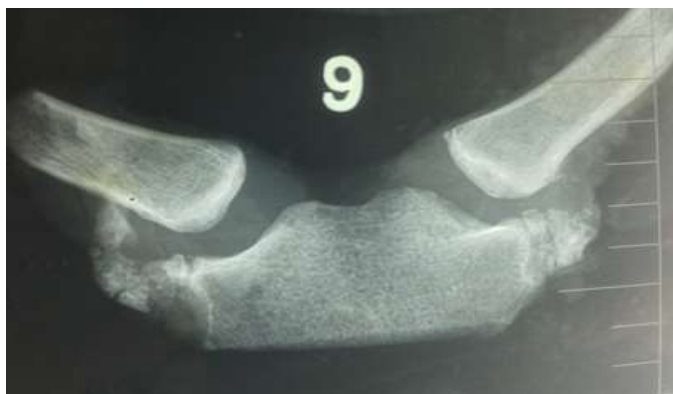

Fig. 3: Photoradiograph showing incomplete union – Stage III

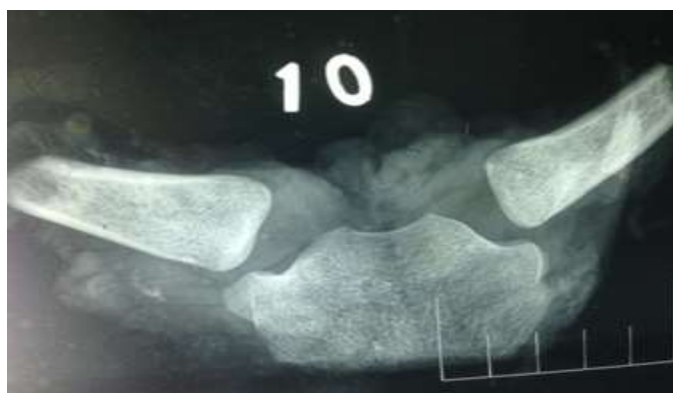

Fig. 4: Photoradiograph showing complete union – Stage IV

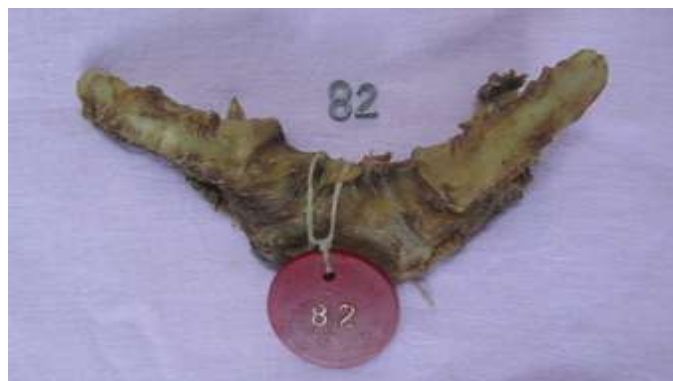

Fig. 5: Medial one third of both the Clavicles along with numbered token and lead number

Discussion

The human clavicle has the longest period of growth related activity when compared to other long bones. Thus it retains its predictive value as a useful and reliable indicator of age in the first three decades of life as sexual maturity, ossification of hand and mineralization of third molars may have completed by this age. Ossification activities at the medial end of the clavicle have been studied by various methods like digital radiography, computed tomography, MRI scan and digital ultrasonic system. In the present study, an attempt was made to determine the age of appearance and fusion of secondary ossification centre of medial end of the clavicle using digital radiography as done by

Singh Pardeep et al². Skeletal maturity at the medial end of the clavicle for a known chronological age of the deceased of Tamil Nadu population was analysed.

According to Flecker³ (1933) majority of cases showed epiphyseal appearance at 21 years and complete fusion at 22 years in both the sexes. According to Parikh⁴ (1990) and Chaurassia⁵ (1980), complete fusion occurred at 21–22 years. Webb and Suchey⁶ studied the ossification activities based on dry bone observations. They showed complete union at 31 years in males and 34 years in females. According to Krogman and Iscan, results of dry bone studies should not be taken as reference standard for radiological assessment.

Chavali et al⁷ studied clavicular ossification in Northwest Indian Population of Chandigarh region. He stated that osteological study of the clavicle was preferred over radiological study because of its reliability and accuracy. In their study, females showed complete union at 31 years and male at 32 years. Singh Pardeep et al² conducted study in Punjab population and observed that complete union occurred in both male and female by 22–23 years. S.S. Bhise⁸ et al conducted a study on the age determination based on radiological examination of the medial end of the clavicle in Mumbai population. The result of their study was medial clavicular epiphysis appeared at 15–16 years in both males and females and complete fusion occurred at 23–24 years in males and 21–22 years in females.

The characteristics of the study population in the present study was:

Out of 155 samples, 117(75.4%) belonged to male and 38 (24.5%) belonged to female.

Female samples contribute only one fourth of the study population. The reason for the low number of female samples was the total number of female cases subjected for medicolegal autopsy in the Institution was less than males and moreover death in the age group of 15–30 years was comparatively low. Statistical analysis was performed using SPSS Software.

The median age in the study population was 22 years and interquartile range was 19–25 years.

The minimum age of appearance of ossification centre in both genders was 18 years. But majority of cases showed appearance of ossification centre by 17–18 years in females and 19–20 years in males. Both male and female showed complete epiphyseal union at the age of 25–26 years. The earliest union occurred at the age of 22 years in males and 20 years in females. All female samples showed complete union at 27–28 years. 81.8% male samples showed complete union at 29–30 years and remaining 18.2% male samples in the age group of 29–30 years showed incomplete union.

The findings of the present study coincide with the study done by Davies and Parson, Stevenson's, Krogman⁹, Stewart¹⁰ and Inderbir.

The findings of the present study were different from those of Parikh, Krishan Vij, Chaurassia and Singh Pardeep. Generally, ossification activities occur earlier in Indian population when compared to Western population. Even in the Indian population there exists difference in the ossification activities between various states across the country. The present study which was conducted in Tamilnadu population show delay in the appearance and fusion of secondary ossification centre of medial end of the clavicle when compared to other Indian studies. Diet, nutritional status and different geographical distribution may be the factors that influence the ossification process. As observed in previous studies, majority of females showed earlier appearance of ossification centre than males. Also, the

earliest age of fusion occurred 2 years ahead in females than the males.

In the present study There might be possibility of inter observer variation which was not ruled out. As only the clavicle samples were radiographed, the possibility of overlapping of the first rib in the chest X ray of the living individuals was not considered. Nutritional, developmental and endocrine abnormalities which affect the skeletal growth were not ruled out.

Conclusion

Radiological examination of the ossification activities of the bones helps to determine the approximate age of an individual. Age can be determined only in terms of range of two to five years based on the appearance and fusion of the ossification centres. On radiological examination of the medial end of 155 clavicles, it was observed that medial clavicular epiphysis appeared in majority of cases at the age of 19–20 years in males and 17–18 years in females. The age of complete fusion for both males and females are 25–26 years. Minimum age of appearance of ossification centre in both sexes was 18 years and earliest union occurred at the age of 20 years in females and 22 years in males.

In the present study, the age group of complete fusion is higher than the previous studies. The reason for this difference may be the geographical, nutritional and endocrine factors which influence the skeletal maturity. Age estimation from teeth, skull and pelvis has been done conventionally but each method has its own limitations and they are influenced by endocrine, racial, dietary and sex factors.

These methods can be used to categorize age into broad age groups. Estimation of age based on fusion of medial clavicular epiphysis plays a vital role in forensic age diagnosis of living adolescents and young adults. With reference to appearance of ossification centre at the medial end of the clavicle, majority of females showed earlier ossification activity than males. But no sex difference is noted in the age of fusion in majority of cases. However, earliest age of fusion occurred 2 years ahead in females than males. No significant difference was observed in ossification activities in both the sexes for the right and left clavicle.

References

1. Singh J, Chavali KH. Age estimation from clavicular epiphyseal union sequencing in a Northwest Indian population of the Chandigarh region. *J Forensic Leg Med*. Volume 18 (2), Elsevier Feb 1,2011:82–7.
2. Singh Pardeep, Gorea R.K, Oberoi S.S, Kapila A.K. Age estimation from Medial end of clavicle by X Ray Examination. *J Indian Academic Forensic Medicine*, Vol. 32, No 1 Jan–March 2010.
3. H. Flecker. 'Roentgenographic observations of the times of appearance of epiphyses and their fusion with the diaphyses. *J.Anat*. 67 (1993), pp 118–164.
4. Parikh C.K. identification, violent asphyxia deaths. In: "Parikh CK, editor. Parikh' textbook of medical

- jurisprudence, Forensic Medicine and Toxicology". New Delhi CBS publishers and distributors; 1999.p. 2.10,3.43-3.55.
5. B.D. Chaurassia. Upper limb and thorax; volume one; Human Anatomy C.B.S. Publisher and Distributors. Fourth edition; p.7.
 6. Patricia A, Owings Webb and Judy Myers Suchey. Epiphyseal union of the anterior iliac crest and medial clavicle in a modern multiracial sample of American Males and Females. American Journal of Physical Anthropology.68:457-466.
 7. Singh J, Chavali KH. Age estimation from clavicular epiphyseal union sequencing in a Northwest Indian population of the Chandigarh region. J Forensic Leg Med. Volume 18 (2), Elsevier Feb 1,2011:82-7.
 8. S.S. Bhise, G.S Chavan, B.G. Chikhalkar, S.D. Nananskar. Age determination from Clavicle: A Radiological study in Mumbai Region. J Indian Acad Forensic Med. Jan-March 2012, Vol.34, No.1.
 9. Krogman WM, Iscan, MY. The human skeleton in Forensic Medicine, Charles C. Thomas Publisher, Illinois, USA, II edition, 1986.
 10. McKern T, and Stewart T. 1957. Skeletal age changes in young American males. Analysed from the standpoint of age identification. Natick, MA: Quartermaster Research and Development Center, Environmental Protection Research Division. 89-97 p.