

Spindle Cell Carcinoma of the Tongue: A Case Report and Review of Literature

Deepti Sharma^{1,*}, Garima Singh²

^{1,2}Assistant Professor, Dept. of Radiation Oncology, VMMC & Safdarjung Hospital, New Delhi

***Corresponding Author:**

Email: drdeeptisharma16@gmail.com

Abstract

Spindle cell carcinoma (SpCC) or sarcomatoid carcinoma of the tongue is rare and aggressive variant of squamous cell carcinoma with incidence of <1%. It is characterised by proliferation of epithelial and mesenchymal components. It is important to diagnose this variant of SCC, because of its tendency to recur and early metastasis.

We are reporting this rare tumor with an unusual location in a forty year old gentleman to contribute in part to the better understanding and awareness of this rare malignancy.

Keywords: Spindle cell carcinoma, Biphasic, Sarcomatoid, Squamous

Access this article online
Website: www.innovativepublication.com
DOI: 10.5958/2455-6793.2016.00019.5

Introduction

Spindle cell carcinoma (SpCC) is a rare variety of squamous cell carcinoma with aggressive behaviour in which usually upper aerodigestive tract is affected.^[1,2] It accounts for almost 3% of all the SCCs in the head and neck region mainly involving larynx, hypopharynx and the mucous surface of oral cavity, but the SpCC of the tongue is very rare.^[3] It usually occurs in men (85%), during sixth to eighth decade of life.^[3,4] It is usually associated with cigarette smoking, alcohol abuse, or any prior history of radiation.^[2,4] We are hereby presenting a case report of spindle cell carcinoma of tongue in a male of 40 years old.

Case Report

A 40 year old gentleman presented with complain of ulcer on right lateral border of tongue for 2months progressive increasing in size associated with difficulty in chewing for 2 months and is not associated with bleeding from the lesion. Patient had a history of chronic tobacco chewing. There was no past history of tuberculosis, diabetes mellitus or any other chronic illness. MRI of face and neck was suggestive of well-defined lesion of 3.1*2.2*2.2cm on lateral aspect of anterior two-third of right side of tongue.[Fig. 1] Lesion is crossing midline to involve adjacent left side of tongue. There are multiple subcentimeter size discrete lymph node in submental and bilateral submandibular region. Patient underwent wide local excision with right sided supra omohyoid neck dissection on 17 October, 2015.

HPE was suggestive of tumor size of 4*2.5*1.8 cm. All margins are more than 1 cm except deep resected margin that was .4cm. zero out of 11 lymph nodes were positive. On immunohistochemistry, tumor cells were positive for p63 and vimentin. Final diagnosis of Spindle cell carcinoma of tongue with pathological stage of pT2N0 was made.

Patient was then referred to our department for adjuvant treatment. Case was discussed in multidisciplinary clinic and was planned for adjuvant radiation therapy upto a dose of 60 Gy in 30 fractions. He completed the entire treatment in November 2015 and is now on regular follow up. Follow up CECT (base of skull to insertion of diaphragm) was normal.

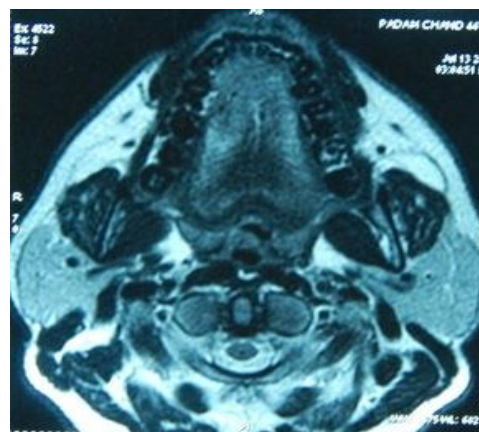


Fig. 1

Discussion

Spindle cell carcinoma is a biphasic tumor which is composed of both malignant epithelial and malignant mesenchymal components. The histogenesis of SpCC is very controversial, in spite of use of immunohistochemical electron microscope and genetic studies. As per the most recent theory, SpCC is a monoclonal epithelial neoplasm with the sarcomatous

component derived from squamous epithelium with divergent mesenchymal differentiation.^[5]

SpCC mainly affects men between sixth to eighth decade of life.^[2,4] In a study by Viswanathan S et al, 21.35% of the patients were in between 20 to 40 years of age.^[4] The most common sites affecting SpCC are larynx, hypopharynx, nasal cavity and it rarely occur in tongue.^[2,3,4] In the present case SpCC arises from the tongue of a young male of 40 years old. Potential risk factors include the history of tobacco use, poor oral hygiene, alcohol abuse, and previous ionizing irradiation of the area.^[2,4] In the present case report, the patient was a chronic tobacco chewer.

SpCC is an aggressive disease and the chances of its recurrence or metastasis to lungs and other distant organ is very high.^[4,6] Therefore it should be treated aggressively. Surgery is the standard definitive treatment for majority of oral cavity cancer. Along with surgical excision, radiotherapy plays a key role in the management of early stage and locally advanced cancer either alone or, in combination with surgery and/or chemotherapy, which provide an efficient adjuvant treatment.^[4,6] Our patient had undergone wide local excision with ipsilateral supra omohyoid dissection followed by adjuvant radiotherapy with no evidence of recurrence and/or metastasis till date.

To conclude, although rare, the diagnosis of SpCC of tongue should always be keep in mind if on HPE malignant spindle cells are seen along with epithelial component and immunohistochemistry should be advised and the case should be treated aggressively.

References

1. Yanofsky VR, Mercer SE, Phelps RG. Histopathological variants of cutaneous squamous cell carcinoma: A review. *J Skin Cancer* 2011;2011:210813.
2. Oktay M, Kokenek-Unal TD, Ocal B, Saylam G, Korkmaz MH, Alper M. Spindle cell carcinoma of the tongue: A rare tumor in an unusual location. *Patholog Res Int* 2011 20;2011:572381.
3. Thompson LD. Squamous cell carcinoma variants of the head and neck. *Curr Diagn Pathol* 2003;9:384-96.
4. Viswanathan S, Rahman K, Pallavi S, Sachin J, Patil A, Chaturvedi P, et al Sarcomatoid (spindle cell) carcinoma of the head and neck mucosal region: a clinicopathologic review of 103 cases from a tertiary referral cancer centre *Head Neck Pathol* 2010;4(4):265–75.
5. Choi HR, Sturgis EM, Rosenthal DI, Luna MA, Batsakis JG, El-Naggar AK, “Sarcomatoid carcinoma of the head and neck: molecular evidence for evolution and progression from conventional squamous cell carcinomas,” *The American Journal of Surgical Pathology* 2003;27(9):1216-1220.
6. Thompson LD, Wieneke JA, Miettinen M, Heffner DK, “Spindle cell (sarcomatoid) carcinomas of the larynx: a clinicopathologic study of 187 cases,” *American Journal of Surgical Pathology* 2002;26(2):153-170.